

# Pruritic urticarial papules and plaques of pregnancy: An unusual case report from a tertiary care hospital of the Eastern part of India



Soumyadeep Mahapatra<sup>1</sup>, Anindita Maiti<sup>2</sup>

<sup>1</sup>Assistant Professor, Department of Pharmacology, ESI PGIMS and ESIC Medical College, <sup>2</sup>Assistant Professor, Department of Community Medicine, IPGMER and SSKM Hospital, Kolkata, West Bengal, India

Submission: 03-02-2024

Revision: 29-03-2024

Publication: 01-05-2024

## ABSTRACT

Pruritic urticarial papules and plaques of pregnancy (PUPPP) is a rare dermatitis of unknown etiology first diagnosed in 1979. It occurs most commonly in the 3<sup>rd</sup> trimester of pregnancy. Postpartum presentation is extremely rare. Treatment modalities mostly involve the relief of symptoms. We are going to report here one case of a 24-year-old primigravid female who presented in the 9<sup>th</sup> month of the gestational period with generalized pruritic eruptions in a tertiary care hospital in the Eastern part of India. These eruptions were erythematous, hyperpigmented, and papular, which began within the striae distensae of the abdomen and progressively spread on the skin of upper and lower limbs, trunk, and buttocks. After the delivery of a full-term male child, there was an aggravation of the symptoms such as itching and disturbed sleep. There was also increased spread of the lesions over the skins of the mentioned areas, which persisted for 6 weeks of the postpartum period. The lesions and associated symptoms gradually subsided with topical application of corticosteroids and hydroquinone along with oral antihistaminic for prolonged periods. Our objective behind reporting this case is to make clinicians aware of PUPPP as a differential diagnosis of peripartum and postpartum pruritic eruptions for prolonged periods.

**Key words:** Pruritic; Urticaria; Plaques; Papules; Pregnancy; Primigravid; Pruritic urticarial papules and plaques of pregnancy

## INTRODUCTION

Pruritic urticarial papules and plaques of pregnancy (PUPPP), also known as polymorphic eruptions of pregnancy, is a rare dermatitis of unknown etiology that most commonly occurs in the 3<sup>rd</sup> trimester of the first pregnancy.<sup>1,2</sup> It is the most common of the inflammatory skin conditions seen exclusively in pregnant women.<sup>3</sup> It was first diagnosed in 1979 as a specific entity that manifested as a unique pruritic eruption that is most common in primigravidae in the 3<sup>rd</sup> trimester of pregnancy, arising within the striae distensae.<sup>1</sup> It is characterized by the presence of itchy papules, plaques, and also erythema.<sup>4</sup> PUPPP usually manifests in the 3<sup>rd</sup> trimester of pregnancy.<sup>2,5</sup> A stay in the

period immediately after childbirth was rarely detected, the prolongation of which persistence can cause anxiety both for the patient or her relatives and for the treating doctors.

We report here a rare case of PUPPP in a 24-year-old primigravid female whose clinical manifestations persisted for more than 1-month postpartum. This case report may help clarify any doubts regarding the prolonged postpartum persistence of polymorphic pregnancy eruptions.

## CASE REPORT

A 24-year-old lady (Primipara) reported to the outdoor of the Department of Obstetrics and Gynecology of a

### Access this article online

**Website:**

<http://nepjol.info/index.php/AJMS>

**DOI:** 10.3126/ajms.v15i5.26302

**E-ISSN:** 2091-0576

**P-ISSN:** 2467-9100

Copyright (c) 2024 Asian Journal of Medical Sciences



This work is licensed under a Creative Commons Attribution-NonCommercial 4.0 International License.

### Address for Correspondence:

Dr. Soumyadeep Mahapatra, Assistant Professor, Department of Pharmacology, ESI PGIMS and ESIC Medical College, Joka, Diamond Harbour Road, Kolkata - 700 104, West Bengal, India. **Mobile:** +91-9002275624. **E-mail:** soumyadeepmahapatra1986@gmail.com

government hospital in the Eastern part of India at the 36<sup>th</sup> week of gestation. She reported developing skin lesions on her trunk, abdomen, and both upper and lower limbs. The lesions were pruritic and caused a disturbance in sleep.

On examination, the lesions were erythematous, hyperpigmented, and papular. The area of spread was the skin of the abdomen, lateral walls of the chest, both buttocks and upper and lower limbs (Figure 1).

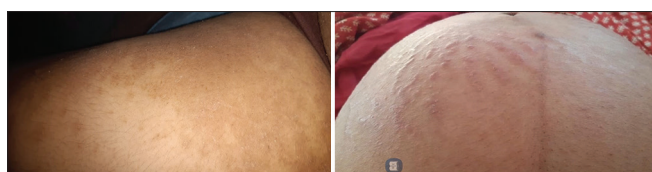
The patient had uneventful progress in the prenatal period. There was a weight gain of 15 kg during the whole pregnancy period. Despite administering second-generation antihistaminic orally and corticosteroid ointment topically, the lesions persisted till the end of the pre-partum period. She had no history of any allergy to any drug or food. Neither she was on any regular medication, nor did she have any family history of atopy.

In the 38<sup>th</sup> week of pregnancy, she presented with bleeding per vaginum, which was suspected as a placental tear. For this, an emergency cesarean section was performed on her under spinal anesthesia and she gave birth to a full-term male child weighing 2.8 kg. Pre-operative, intraoperative, and post-operative periods were uneventful.

There was an aggravation of the lesions along with pruritus in the postpartum period. She was continued with second-generation oral antihistaminics (tablet cetirizine 10 mg once a day). Along with topical corticosteroids, hydroquinone cream was applied to the lesions continuously. The patient was also followed up in the dermatology outdoor of the same hospital.

The lesions persisted for 6-week postpartum, with progressive improvement since 3<sup>rd</sup> week of the postpartum period. She was regularly followed up in OBG and dermatology outdoors. Since the 6<sup>th</sup> postpartum week, marked improvement of the lesions was observed. She was advised to take oral antihistaminic whenever necessary and continue the hydroquinone cream 3 times a day for the next 1 month.

After 1 month, the patient was followed up in the respective outdoors. Her lesions almost subsided along with other complaints such as pruritus and disturbed sleep.



**Figure 1:** Erythematous and hyperpigmented papules over the skin of the right thigh and abdomen

## DISCUSSION

PUPPP is a benign condition that affects approximately one out of 300 pregnancies.<sup>3</sup> It mostly appears during the 35<sup>th</sup> week of gestation and subsides in the early postpartum period.<sup>6</sup> Persistence during the postpartum period is rare, though onset during the postpartum period has also been reported.<sup>7</sup> Most of the cases have been found to occur in nulliparous primigravid females.<sup>8</sup>

Pruritus is the common presentation found in patients suffering from PUPPP. However systemic involvement is not found to be associated with PUPPP till date.<sup>9</sup> It mostly affects the women at 3<sup>rd</sup> trimester of pregnancy, which gets cured post-confinement.<sup>10</sup>

The exact etiopathogenesis of PUPPP is still not clearly understood, though studies reveal its strong association with nulliparity, pregnancy-induced hypertensive disorders, uncontrolled maternal weight gain during gestation, or excessive stretch of abdominal skin during the last trimester of pregnancy.<sup>9,10</sup> Several theories support the association of the above factors with the etiopathogenesis of PUPPP. Either it may be due to an immunologic response against antigens of the fetus circulating in maternal blood,<sup>11</sup> or it may be because of damage to underlying connective tissue due to abrupt stretching of abdominal skin due to the majority of maternal weight gain during 3<sup>rd</sup> trimester, which may release antigens which may promote inflammatory response.<sup>12</sup>

As seen in the above case, PUPPP can be managed with second-generation antihistaminic orally along with the topical application of corticosteroids and hydroquinone. Additional symptomatic relief can be obtained by adopting general measures such as cool, soothing baths, and wearing light cotton clothing on the body.<sup>13</sup> In chronic or severe cases, high-potency oral corticosteroids should be provided by health practitioners for relief from symptoms.<sup>14</sup>

## CONCLUSION

PUPPP can present not only in the 3<sup>rd</sup> trimester of pregnancy but also during the postpartum period and its persistence may be prolonged during the postpartum period. Its pathogenesis is multifactorial. The management of the same if present during the postpartum period should be kept in mind as mostly conservative and multidisciplinary if required. Advanced research regarding the same may help in improvising newer modalities of its management.

## ACKNOWLEDGMENT

We would like to express our gratitude to the Female patient in our study, who has continuously followed up with us regularly throughout the course of the reaction.

## REFERENCES

1. Lawley TJ, Hertz KC, Wade TR, Ackerman AB and Katz SI. Pruritic urticarial papules and plaques of pregnancy. *JAMA*. 1979;241(16):1696-1699.  
<https://doi.org/10.1001/jama.241.16.1696>
2. Giugliano E, Cagnazzo E, Servello T, Mossuto E, Marci R and Patella A. Pruritic urticarial papules and plaques of pregnancy. *J Obstet Gynaecol*. 2012;32(3):301-302.  
<https://doi.org/10.3109/01443615.2011.652704>
3. Lehrhoff S and Pomeranz MK. Specific dermatoses of pregnancy and their treatment. *Dermatol Ther*. 2013;26(4):274-284.  
<https://doi.org/10.1111/dth.12078>
4. Devaraj KN and Haley S. Atypical pruritic urticarial papules and plaques of pregnancy-a case report. *Rwanda Med J*. 2020;77(1):1-3.
5. Dehdashti AL and Wikas SM. Pruritic urticarial papules and plaques of pregnancy occurring postpartum. *Cutis*. 2015;95(6):344-347.
6. Yancey KB, Hall RP and Lawley TJ. Pruritic urticarial papules and plaques of pregnancy. Clinical experience in twenty-five patients. *J Am Acad Dermatol*. 1984;10(3):473-480.  
[https://doi.org/10.1016/S0190-9622\(84\)80097-3](https://doi.org/10.1016/S0190-9622(84)80097-3)
7. Kim EH. Pruritic urticarial papules and plaques of pregnancy occurring postpartum treated with intramuscular injection of autologous whole blood. *Case Rep Dermatol*. 2017;9(1):151-156.  
<https://doi.org/10.1159/000473874>
8. Aronson IK, Bond S, Fiedler VC, Vomvouras S, Gruber D and Ruiz C. Pruritic urticarial papules and plaques of pregnancy: Clinical and immunopathologic observations in 57 patients. *J Am Acad Dermatol*. 1998;39(6):933-939.  
[https://doi.org/10.1016/S0190-9622\(98\)70265-8](https://doi.org/10.1016/S0190-9622(98)70265-8)
9. Ohel I, Levy A, Silberstein T, Holcberg G and Sheiner E. Pregnancy outcome of patients with pruritic urticarial papules and plaques of pregnancy. *J Matern Fetal Neonatal Med*. 2006;19(5):305-308.  
<https://doi.org/10.1080/14767050600590573>
10. Elling SV, McKenna P and Powell FC. Pruritic urticarial papules and plaques of pregnancy in twin and triplet pregnancies. *J Eur Acad Dermatol Venereol*. 2000;14(5):378-381.  
<https://doi.org/10.1046/j.1468-3083.2000.00026.x>
11. Drehmer M, Duncan BB, Kac G and Schmidt MI. Association of second and third trimester weight gain in pregnancy with maternal and fetal outcomes. *PLoS One*. 2013;8(1):e54704.  
<https://doi.org/10.1371/journal.pone.0054704>
12. Cohen LM, Capeless EL, Krusinski PA and Maloney ME. Pruritic urticarial papules and plaques of pregnancy and its relationship to maternal-fetal weight gain and twin pregnancy. *Arch Dermatol*. 1989;125(11):1534-1536.  
<https://doi.org/10.1001/archderm.125.11.1534>
13. Ahmadi S and Powell FC. Pruritic urticarial papules and plaques of pregnancy: Current status. *Australas J Dermatol*. 2005;46(2):53-60, quiz 59.  
<https://doi.org/10.1111/j.1440-0960.2005.00160.x>
14. Weiss A. *Dermatoses of Pregnancy (Doctoral Dissertation, University of Zagreb. School of Medicine); 2023.*

### Authors Contributions:

**SM**- Concept and design, collection of the case, manuscript preparation; **AM**- Review of manuscript.

### Work attributed to:

ESI PGIMSR and ESIC Medical College.

### Orcid ID:

Dr. Soumyadeep Mahapatra - <https://orcid.org/0009-0008-2049-1034>

Anindita Maiti - <http://orcid.org/0000-0003-4015-6854>

**Source of Support:** Nil, **Conflicts of Interest:** None declared.