

■ Case Report

Discitis after spinal anaesthesia in lower limb surgery in orthopaedics

P Chaudhary¹, BP Shrestha¹, GP Khanal¹, R Maharjan¹, R Rijal¹, SR Paneru¹, DK Yadav²

¹Department of Orthopaedics and ²SPH &CM
B.P.Koirala Institute of Health Sciences, Dharan, Nepal

Abstract

Spinal Anaesthesia has its own complications from beginning of its use but due to lower incidence of its complications, its popularity has continued to increase world wide. We present a case of 51 year old gentleman who had undergone removal of implant (plate from tibia and Rush nail from femur) at Orthopaedic Department of B.P.Koirala Institute of Health Sciences, Dharan, Nepal with complain of low back pain with radiation to right lower limb, decreased sensation, difficulty in voiding following a surgery. We report this case for its rarity and unique characteristics and to highlight the importance of timely treatment so that serious neurological complications do not occur.

Keywords: epidural abscess, discitis, spinal anaesthesia

Introduction

Spinal Anaesthesia is one of the most common mode of given anaesthesia to perform lower limb surgery in Orthopaedics. Spinal anaesthesia is accompanied by many definite and terrible dangers which are far too little appreciated by surgeons and anaesthesiologists. Neurological complications, some of them serious, sometimes occur following spinal anaesthesia. In the majority of the relatively few cases in which they occur, they are caused by factors which can be obviated. Rigid adherence to defined safeguards will reduce the incidence of complications and overcome most of the objections to the procedure.¹

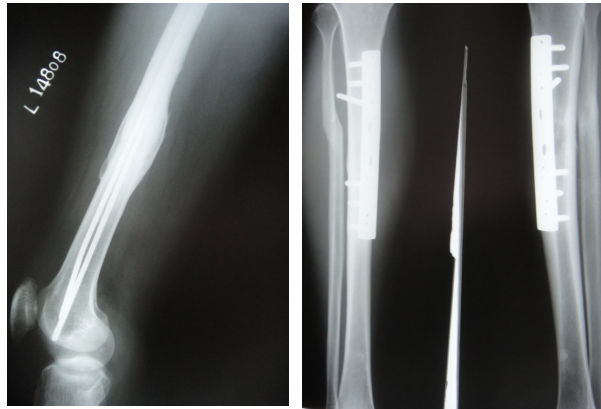
Case descriptions

A 51 year old gentleman from remote hilly areas had alleged history of RTA 7 years back for which he had undergone ORIF+Plating for both tibia and

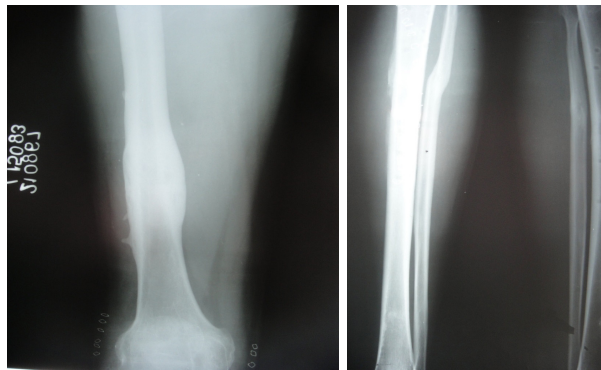
femur outside. After 3 months of post operative period, there were implant failure ie femoral plate broke. He reported to department of Orthopaedics, B.P.Koirala Institute of Health Sciences, Dharan with broken plate in femur without bony union. He was operated with Rush nails after removing broken plate from femur (Fig:1a,b). He was on subsequent follow up and fracture in both tibia and femur were united both clinically and radiologically in 6th post operative month. This time he was operated for removal of implant (Fig:2 a,b). The total anaesthetic time was 3 hours. Anaesthesiologist had given 0.5 ml of heavy buvupacaine solution using 24G spinal needle, Anaesthesia was given in between L4/L5 disc space in first attempt. As anaesthetic effect wore off, patients begun to complain of pain in the back which is radiating down to the legs. He had difficulty of voiding urine. There were scattered areas of hyposthesia on sciatic nerve distribution. On motor examination, EHL on right side was 0/5. There were no history of fever and no meningismus were present. Plane X-ray of lumbar spine was done which did not show any abnormality (Fig:3a,b). MRI scanning of L/S spine was done which was suggestive of

Address for correspondence
Dr Pashupati Chaudhary
Associate Professor, Department of Orthopaedics
BP Koirala Institute of Health Sciences, Dharan
Email: chaudharypashupati@yahoo.com

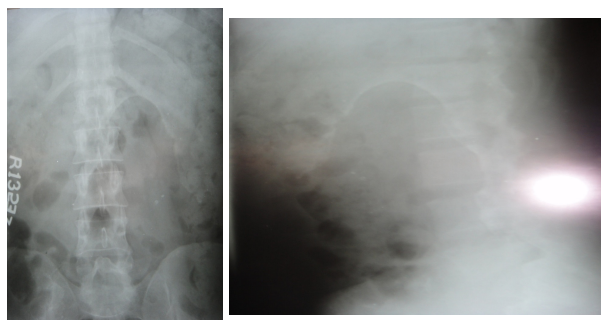
achachnoiditis and discitis(Fig:4a,b). A routine blood investigation was done. Patient was treated with I/ V drugs and steroids. Patient gradually improved with his symptoms but motor power didn't improve after 6 weeks of treatment.




(a) (b)
 Fig:1 Pre- Operative Photograph



(a) (b)
 Fig: 2 Post-Operative Photograph



(a) (b)
 Fig:3 Plane X-rays Lumbar Spine



(a) (b)
 Fig: 4 MRI of Lumbar Spine

Discussion

Discitis (achachnoiditis) is a rare complication of Spinal Anaesthesia which if unrecognized can lead to serious neurological sequelae or even death. The incidence of discitis and epidural abscess following Spinal Anaesthesia is 1: 505,000. A Finnish study of closed anaesthesia from 1987 to 93 reported 4 cases of epidural abscess in 550,000 spinal and 170,000 epidural anaesthesia administrations. In comparison, the usual cause is endogenous haematological infections with an incidence of 2:10,000 hospital admissions.¹The presentation of spinal discitis and epidural abscess can be nonspecific. Fever, malaise, and back pain are the most consistent early symptoms.² Local tenderness, with or without neurologic deficit, is the usual physical finding and leukocytosis may be the only abnormal laboratory finding. Discitis and Epidural abscess should be suspected in patients presenting with fever and back pain, specially if they have other risk factors such as an immunocompromised state, steroid therapy, diabetes mellitus or malignancy.³

Any delay in recognition and treatment can lead to serious neurological damage or death, hence the anaesthesiologist must have a high index of suspicion in a patient presenting with the above clinical findings, especially if there is a history of Spinal Anaesthesia.⁴

Conclusion

There is no doubt that spinal anaesthesia may result in severe neurological complications. However, these complications are rare and that they occur at all need not necessarily condemn the method, because of

careful analysis, it appears that most of them can be avoided. Trauma and infection may be prevented by scrupulous attention to technique

References

1. Lalla RK, Joshi MC, Sridhar Sahni MS HMJAFI 2005; 61: 186-187
2. Hilavin ML. Spinal epidural abscess: A 10 year prospective study. *Neurology* 1990; 27:177-84.
3. Aromaa U, Lahdensuu M, Cozanitis DA. Severe complications associated with epidural and spinal anaesthetics in Finland 1987-93. A study based on patient insurance claims. *Acta Anaesthesiologica Scand* 1997; 41(4):445-52.
4. Deardre Chao, Anil Nanda. Spinal epidural abscess: A diagnostic challenge. *Am Fam Physician* 2002; 65:1341-6.