

CASE REPORT
VISUAL OUTCOME ON FITTING ROSE-K2 XL LENS IN A CASE WITH TERRIEN'S MARGINAL DEGENERATION
SK MISHRA^{1*}, GS SHRESTHA¹, P DHUNGEL¹, B ARYAL²
¹BP Koirala Lions Center for Ophthalmic Studies, Institute of Medicine, Tribhuvan University, Maharajgunj, Kathmandu, Nepal.

²Department of Clinical Pharmacology, Chitwan Medical College, Bharatpur-10, Chitwan, Nepal.

**Correspondence to: Mr Sanjeeb Kumar Mishra, B.P. Koirala Lions Center for Ophthalmic Studies, Institute of Medicine, Tribhuvan University, Maharajgunj, Kathmandu, Ph no: 9841363846, Email: msanjeeb22@yahoo.com*

ABSTRACT

Terrien's marginal degeneration is an uncommon disease of the peripheral cornea occurring at any age that results in corneal thinning causing corneal irregular astigmatism. RoseK2 XL lens has an aspheric optical zone and employed in the fitting of irregular corneas for vision and comfort while maintaining corneal health. Rose K2 XL lens was fitted in a 17 year female presented to Contact lens clinic of B.P. Koirala Lions Center for Ophthalmic Studies, Kathmandu having RE Terrien's marginal degeneration. Her presenting visual acuity was 6/60 in right eye and 6/6 in left eye with best subjective refraction OD: +2.00/-3.00X150 and OS: Plano. Her corneal topography revealed irregular corneal astigmatism as indicated by SimK49.85/41.63@137. RoseK2 XL which is a mini-scleral lens, showed an excellent fitting attaining visual acuity 6/6. RoseK2 XL lens provides not only good visual acuity also confirms comfort in patients with corneal marginal degeneration.

Key Words: *Terrien's Marginal degeneration, RoseK2 XL lens*

INTRODUCTION

Terriens marginal degeneration is an uncommon disease of the peripheral cornea, occurring at any age and 75 % being males.¹ Lesions begin usually superonasally rarely inferiorly with development of fine, white sub epithelial, peripheral opacities that spare the limbus causing corneal thinning. The epithelium is typically intact with yellowish white lipid deposits in the centre of the gutter with associated vascularisation.²

Contact lens fittings for irregular corneas represent one of the greatest challenges in terms of chair time, number of patient visit and number of ordered lenses. Irregular high corneal astigmatism can be seen in keratoconus,⁴ pellucid marginal degeneration,⁵ keratoplasty,⁶ post-LASIK ectasia⁷ and corneal ring segment implantation.⁸ These conditions lead to poor visual acuity with glasses or conventional soft contact lenses. Rigid gas-permeable (RGP) contact lenses are considered the best optical solution for patients with irregular corneas for its masking corneal irregularity and optical aberration by creating a tear layer between the lens and the cornea.⁷ However, corneal RGP lenses may not be appropriate when corneal irregularity is excessive. In severe corneal distortions corneal RGP lenses may result in lens decentration and excessive lens movement causing poor comfort and unstable vision ultimately leading to corneal scarring.⁹ Hybrid lenses and piggyback lens systems might enhance lens stability and wearing comfort, but these techniques increase the cost and complicate lens storage and maintenance.^{10,11} Mini-scleral contact lenses constitute safe options in the management of irregular corneas.¹²

CASE REPORT

A 17 year old female presented to the contact lens clinic of B.P. Koirala Lions Center for Ophthalmic Studies with a chief complaint of blurring of vision her right eye. She wore glasses for 3 years. She sustained no ocular trauma and didn't perform ocular surgery. Her presenting best corrected visual acuity was 6/60 in right eye (RE) with +2.00/-3.00X150 and 6/6 in left eye (LE) with plano. Cycloplegic refraction revealed her refractive error RE +2.00/-6.00 X 150 with visual acuity of 6/18⁺². Slit lamp examination revealed RE superotemporal circumlinear corneal thinning with intact epithelium, without neovascularisation, minimal lipid deposition and a clear area existing between the lesion and limbus. (Figure 1).

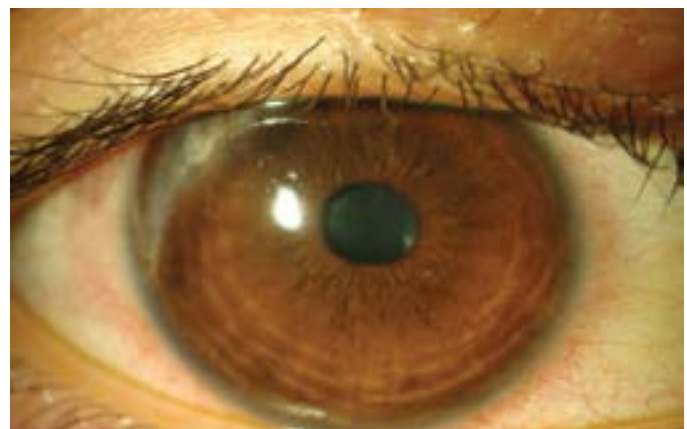


Figure 1 showing superotemporal circumlinear corneal thinning without neovascularisation

There was no epithelial defect noted by fluorescein staining. Keratometry reading indicated corneal astigmatism of 11.50D against the rule astigmatism [Vertical: 8.65mm (39.00D), Horizontal: 6.67 mm (50.50D)] in RE. The Schirmer test I revealed clinically dry eye with height of 1mm.

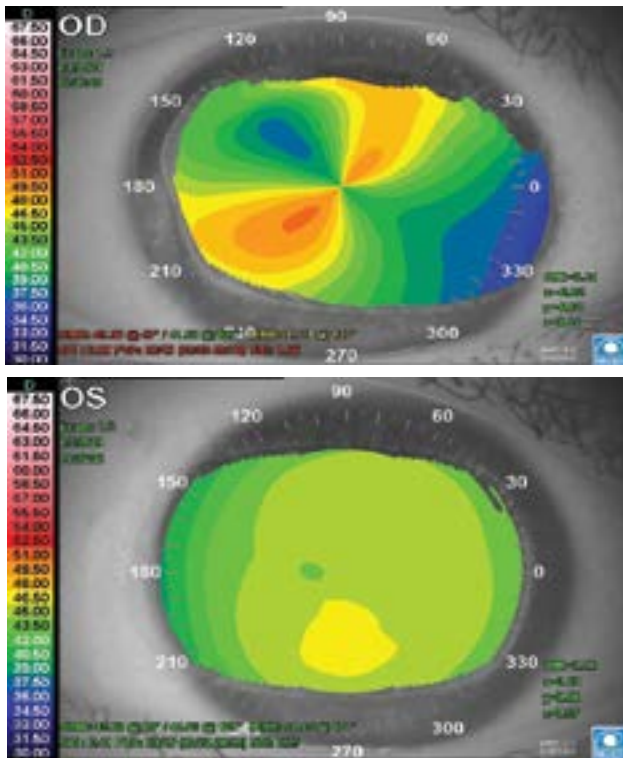


Figure-2: Corneal topography showing RE oblique corneal astigmatism and LE normal cornea

Corneal topography of right eye revealed high irregular corneal astigmatism as indicated by SimK 49.85/41.63@137. In view of above clinical findings, a diagnosis of RE Terrien's marginal degeneration was made. The fundus examination under mydriatics (tropicamide 0.5%) revealed normal caliber. Corneal contact lens was not tried owing to peripheral corneal thinning. Trial of RoseK2 XL with the parameters of base curve of 7.00mm, total diameter of 14.60mm, back vertex power of -6.00DS and standard edge lift showed an excellent fitting attaining visual acuity equal to 6/6 in RE. The static fitting assessment revealed adequate coverage with minimal movement. Dynamic fitting assessment with fluorescein staining in cobalt blue filter of slit lamp revealed adequate edge lift with no perilimbal blanching of the vessels and small air bubble which was away from the visual axis (Figure.3).

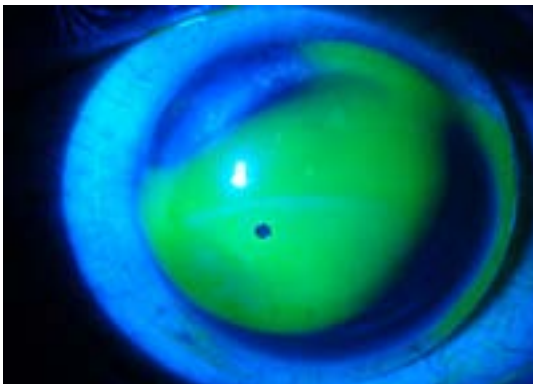


Figure 3 showing optimal Fitting of Rose K2 XL

DISCUSSION

In Terrien's degeneration when the thinning is restricted to the superior or inferior area of the peripheral cornea, there is relative steepening approximately 90° away from the mid-point of the thinned area resulting in astigmatism characteristic of this disorder.³ Histologically epithelium may be normal, thickened, and the thinned Bowman's layer and the lamellae may be split or fibrillated.¹³⁻¹⁴ The inflammation depends on the form of the disease. Lipid is found consistently.¹⁵ Though a lot of etiologies have been proposed, levels of circulating immune complexes are not elevated in patients with Terriens. In our patient the left eye was absolutely normal. Marginal corneal degeneration, dellen formation, collagen vascular diseases, sclerokeratitis, staphylococcal marginal keratitis etc have been proposed as differential diagnosis.

This patient was prescribed glasses and fitted with Rose K2 XL lens. In the last decade, improvements in RGP materials and manufacturing processes have spawned a renewed interest in large diameter lenses.¹⁶⁻¹⁷ Large diameter RGP contact lenses provide excellent level of comfort, prevent bearing on already compromised cornea and provide excellent visual performance.¹⁸⁻¹⁹

Since the patient had clinically dry eyes revealed by Schirmer tear test the conventional RGP would be of low benefits. Rose K2 XL lens is fluid filled contact lens which provide moist environment to cornea and correct irregular astigmatism. Hence symptom of dry eye can be minimized.

Rose K2 XL lenses is manufactured in tasilfocon A material (Menicon Z, Menicon Co. Ltd., Nagoya, Japan). The lens design features an aspherical optic zone and is available in 9 edge lifts (from double decrease to double increase in 0.5 steps). The trial set consisted of 14 lenses having an overall diameter ranging from 13.0 to 14.6mm depending on the back optic zone radius (BOZR) that is the diameter increases with increasing BOZR and vice versa. All lenses in the trial set were a standard edge lift. Rose K2 XL lens (0.70mm steeper than average K reading) was taken with the parameters of base curve of 7.00mm, total diameter of 14.60 mm, back vertex power of -6.00DS and standard edge lift. However, future studies with a greater sample size and a longer follow-up are recommended to confirm the safety of this type of contact lens and propose fitting protocol.

CONCLUSION

The Rose K2 XL semi-scleral contact lenses improve vision and comfort significantly for patients with irregular corneas with minimal corneal scarring. The results with this lens suggest that the fitting process is efficient and effective by reducing the number of patient visits.

REFERENCES

1. Kanski A systemic Approach to Clinical ophthalmology .1987 ;108:109.
2. Hallermann, W. Zur Behind lung der Terriens marginal dystrophy Klin. Monatsbl. Augenheilkd. 1978; 173:770.
3. Wilson S.E. etal. Corneal topography. 1990; 6:15.

4. Romero-Jiménez M, Santodomingo-Rubido J, Wolffsohn J. Keratoconus: a review. *Contact Lens and Anterior Eye* 2010;33:157–66.
5. Jinabhai A, Radhakrishnan H, O'Donnell C. Pellucid marginal degeneration: a review. *Contact Lens and Anterior Eye*. 2011;34:56–63.
6. Geerards AJ, Vreugdenhil W, Khazen A. Incidence of rigid gas-permeable contact lens wear after keratoplasty for keratoconus. *Eye and Contact Lens*. 2006;32:207–10.
7. Gemoules G, Morris KM. Rigid gas-permeable contact lenses and severe higher order aberrations in postsurgical corneas. *Eye and Contact Lens*. 2007;33:304–7.
8. Smith KA, Carrell JD. High-Dk piggyback contact lenses over intacs for keratoconus. *Eye Contact Lens*. 2008;34:238-41.
9. Barr JT, Wilson BS, Gordon MO, Rah MJ, Riley C, Kollbaum PS, et al. Estimation of the incidence and factors predictive of corneal scarring in the Collaborative Evaluation of Keratoconus (CLEK) study. *Cornea* 2006;25:16–25.
10. Nau AC. A comparison of synergeyes versus traditional rigid gas permeable lens designs for patients with irregular corneas. *Eye and Contact Lens* 2008;34:198–200.
11. Sengor T, Kurna SA, Aki S, Özkurt Y. High Dk piggyback system for contact lens-intolerant keratoconus patients. *Clinical Ophthalmology* 2011;5:331–5.
12. Ye P, Sun A, Weissman BA. Role of mini-scleral gas-permeable lenses in the treatment of corneal disorders. *Eye and Contact Lens* 2007;33:111–3.
13. Smolin and Thoft *Cornea and External diseases* pg 506 – 507.
14. Suyeges, M.D., Levai, G and Alberth, B. Pathology of Terriens degeneration.
15. Poulouen et al *Eye* 1989; 3:791.
16. Schornack MM, Patel SV. Relationship between corneal topographic indices and scleral lens base curve. *Eye and Contact Lens* 2010;36:1–4.
17. Pullum K, Whithing MA, Buckley RJ. Scleral contact lens: the expanding role. *Cornea* 2005;24:269–77.
18. Rosenthal P, Croteau A. Fluid-ventilated, gas-permeable scleral contact lens is an effective option for managing severe ocular surface disease and many corneal disorders that would otherwise require penetrating keratoplasty. *Eye and Contact Lens* 2005;31:130–4.
19. Pullum KW, Buckley RJ. A study of 530 patients referred for rigid gas permeable scleral contact lens assessment. *Cornea* 1997;14:130–7.