



CASE REPORT

OCCLUSAL STAMP, RENOVATION TO RESTORATIVE TECHNIQUE: A CASE SERIES

Kriti Shrestha^{1,*}, Chetna Arora¹, Vanita Gautam¹, Snigdha Shubham¹, Rupam Tripathi¹, Manisha Nepal¹, Ateet Karki¹

¹Department of Conservative and Endodontics, Universal College of Medical Science, Ranigaon, Bhairahawa, Nepal

Received: 14 Feb, 2021

Accepted: 2 May, 2021

Published: 19 Jun, 2021

Key words: Composite resin; Restoration; Stamp technique

**Correspondence to: Kriti Shrestha, Department of Conservative and Endodontics, Universal College of Medical Science, Ranigaon, Bhairahawa, Nepal.
Email: drkritishrestha@gmail.com*

Citation

Shrestha K, Arora C, Gautam V, Shubham S, Tripathi R, Nepal M, Karki A. Occlusal stamp, renovation to restorative technique: a case series. Journal of Chitwan Medical College. 2021;11(36):119-21.



Peer Reviewed

ABSTRACT

Maintaining the contact and contour point is very difficult task in composite restoration which requires expertise hand and is time consuming. The occlusal stamp technique has been developed to facilitate the work of dental professional and achieve aesthetic and functional results. A precise tooth like restoration with an accurate functional occlusion is obtained when the stamp technique is performed. Therefore, the aim of this case report was to present clinical cases in which the stamp technique was performed to replicate the original and well controlled occlusal anatomy, so less time is required for finishing and polishing.

INTRODUCTION

A good restoration can resemble the original anatomical shape of a tooth, which is known as biomimetic restoration.¹ Restoration can be done with both direct and indirect method. The contact, contour and the occlusion is well controlled and achieved in the laboratory in indirect method while the direct restorations pose challenges in achieving the same intra-orally.² It requires skilled dexterity to achieve precise anatomy as that of natural tooth and is time consuming and technique sensitive.

Dr. Waseem Riaz introduced the new 'stamp technique' to overcome the problem of anatomic formation for direct composite restoration that could obtain dental occlusal topography appropriately.² It has also been reported for vertical bite reconstruction of worn out dentitions.³

Stamp is like an index, which is the mini impression made by flowable composite or putty before cavity preparation. This stamp copy the original unprepared tooth structure, thus replicates the original anatomy of the tooth structure.² Before final curing, the obtained stamp is then pressed against the final composite increment to achieve a positive replica of the

pre-operative anatomy.⁴ The preoperative occlusal morphology provides an ideal index for replication of esthetic along with proper function & has become a norm in modern dentistry for patients seeking esthetic restoration even for the posterior teeth. However, such replication technique is dependent on intact occlusal morphology and only useful for restoring carious teeth with intact occlusal anatomy or hidden caries.⁵

CASE REPORT

Case 1

A 24 year female patient reported to the department of Conservative dentistry and Endodontics complaining of mild sensitivity to cold in lower right back tooth region. An oral examination revealed Class I caries on tooth 47 (Figure 1a). After thorough examination, it was decided to restore 47 using the stamp technique with putty (Figure 1b). After making the index, tooth was isolated with rubber dam (Figure 1c), a cavity was prepared (Figure 1d) followed by etching with 37% orthophosphoric acid (Figure 1e) and bonding with one coat bond SL (Figure 1f). After placing the last increment of composite (3M Filtek Supreme), the index was placed back on the teeth to replicate the previous anatomy (Figure 1g). After

removing the index, the excess composite was removed and cured (Figure 1h) and finishing and polishing done by using Soflex Spiral Wheel [3M-ESPE] (Figure 1i). This case utilized a single shade of composite.

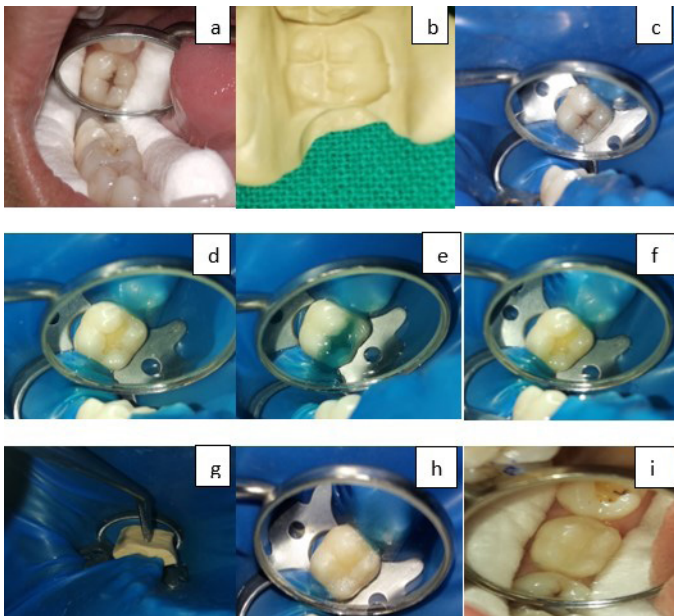


Figure 1: The stamp technique for Class I cavity of tooth 47: (a) Pre-operative photograph- 47. (b)The putty stamp. (c) Rubber dam isolation. (d) Cavity preparation. (e) Etchant applied. (f) Bonding applied.(g) Placement of the occlusal stamp.(h) Restoration after curing.(i) Final restoration

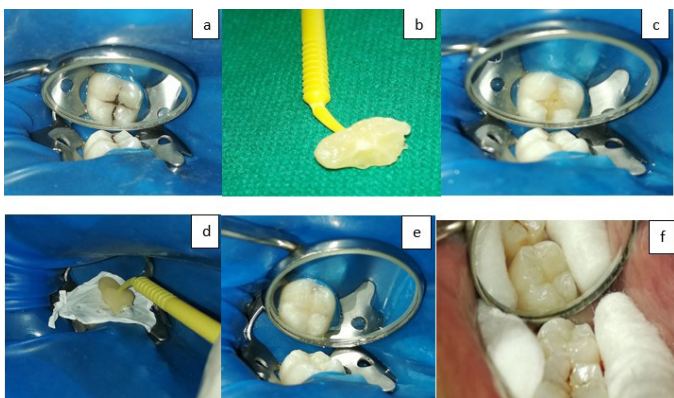


Figure 2:The stamp technique for Class I cavity of tooth 47: (a) Pre-operative photograph- 47 isolation by rubber dam. (b) The composite stamp. (c) Cavity preparation. (d) Placement of teflon tape and the occlusal stamp. (e) Restoration after curing. (f) Final restoration.

Case 2

A 20 years old male reported to the department of Conservative dentistry and Endodontics complaining of a blackish discoloration of his lower right back tooth. Upon examining, a class I cavity was visualized on tooth 47(Figure 2a). After oral prophylaxis and rubber dam isolation, the stamp

was made with flowable composite (Filtek flow, 3M ESPE) placed on occlusal surface of the affected tooth (Figure 2b). Then, cavity was prepared (Figure 2c). After etching, bonding and incremental placement of composite, the last layer of composite was added and before being cured, a piece of Teflon tape was laid on the occlusal surface and the occlusal stamp was placed over the tape (Figure 2d). Next, the tape was removed and the excess composite was removed and then polymerized (Figure 2e). Finishing and polishing done by using Soflex Spiral Wheel [3M-ESPE] (Figure 2f). This case also utilized a single shade of composite.

DISCUSSION

In the past few decades, the occurrence of dental caries is reduced. The efficient use of fluorides is considered as the contributing factor in reduction of caries incidence.⁴ Evidence also suggests that fluoride temporarily hides cavities by causing only surface remineralization which “covers up” underlying cavities. This phenomenon has been identified as the ‘fluoride bombs’ and indicates the direct relationship of fluoride utilization with the increasing resistance of the enamel surface.⁶ Despite the decreasing prevalence of tooth decay and the need for direct restorations, dentin caries lesions (“hidden caries”) is a frequent finding in individuals.⁷

Restoring a complex occlusal morphology of posterior teeth is tremendously difficult when direct composite resin restorative materials are use. Time required for finishing and polishing the composite restoration is double as compared to other restoration. The new stamp technique, an alternative placement technique of composite restoration has been introduced to overcome these problems. The preoperative case selection with preserved anatomy of pit and fissure caries is important aspect for success of the treatment.⁸ The stamp technique consists of fabricating an occlusal matrix that mimics the natural occlusal anatomy of posterior teeth, before preparing cavity and the matrix is then placed against the final composite increment before curing it. The pressure exerted by the stamp on the composite resin decreases the formation of microbubbles as well as interference of oxygen in the curing of the last layer which are considered for long-term success factors.⁹

Geena Mary et al concluded microbrush stamp technique is an easy to follow procedure to effectively and efficiently recreate occlusal topography in teeth with almost intact occlusal anatomy.² Alexy Murashkin proposed different stamp technique and concluded it to be a convenient, favorable and biomimetic procedure.⁴ Pompeu et al presented a case report on occlusal stamp technique and concluded that this technique is effective for restoration in posterior tooth with hidden caries and extensive dentin involvement.⁷

The stamp technique is a fast procedure with decreased chair side time in recreating occlusal anatomy and also in polishing and finishing. Since the matrix replicates the occlusal anatomy, no manual contouring is required; there is no need of special instruments for contouring the restoration, also the material

consumption is minimum.¹⁰ This technique cannot be used in all cases; grossly carious teeth cannot be restored and pre-restoration evaluation must be done to ensure normal occlusion. Furthermore the cost of the material used for making impression is also expensive. However, other cost-effective materials could be considered for stamp as pit and fissure sealants, poly methyl methacrylate, pattern resin, gingival dam material, vacuum formed template, and bite

registration material.⁴

CONCLUSION

Using the stamp technique, we obtain fast, simple and predictable integration of the new restoration in the occlusal anatomy and function. When the operator is skilled, this technique is a favorable and convenient procedure.

REFERENCES:

1. Soesilo D, Hadinata Y, Pangabdian F, Rochyani L. Direct composite restoration using stamp technique and pizza technique: A case report. *International Journal of Dentistry Research*. 2020; 5(1): 4-6. [\[LINK\]](#)
2. Mary G, Jayadevan A. Microbrush stamp technique to achieve occlusal topography for composite resin restorations-A Technical Report. *Journal of Scientific Dentistry*. 2016;6(2):76-82. [\[DOI\]](#)
3. Simon T, Ramseyer, Christoph Helbling, Adrian Lussi. Vertical Bite Reconstructions of Erosively Worn Dentitions and the "Stamp Technique" - A Case Series with a Mean Observation Time of 40 Months. *The Journal of Adhesive Dentistry* 2015; 17(3):283-289. [\[DOI\]](#)
4. Murashkin A. Direct posterior composite restorations using stamp technique-conventional and modified: A case series. *IJDR*. 2017;2(1):3-7. [\[LINK\]](#)
5. Shaikh H, Choksi D, Idnani B. Posterior composite restoration with stamp technique. *Indian J Oral Health Res*. 2020;6:29-31. [\[DOI\]](#)
6. Martos J, Silveira LM, Ferrer-Luque CM, González-López S. Restoration of posterior teeth using occlusal matrix technique. *Indian J Dent Res*. 2010; 21(4):596-9. [\[DOI\]](#)
7. Pompeu JG, Morais RC, Ferreira TO, Prado VL, de Jesus Sousa Sampaio T, da Silva Pedrosa M, et al. Occlusal stamp technique for direct resin composite restoration: A clinical case report. *Int J Recent Sci Res*. 2016;7(7):12427-30. [\[LINK\]](#)
8. Moraru I, Bugală A, Gheorghe A, Popescu D, Răcă AM. Why using the stamp technique in class I cavities is a first choice filling technique? *Romanian Journal of Medical and Dental Education*. 2019;8(1):54-59. [\[LINK\]](#)
9. Tambake NJ, Tambake S, Gandhi N, Jadhav Y, Madhu K, Burad P. Stamp technique-new perspective of aesthetic dentistry: A case report. *IOSR Journal of Dental and Medical Science*. 2017;16(6):49-51. [\[LINK\]](#)
10. Ionaş M, Dăncilă A. Occlusal Surface Achieved Using the Stamp Technique. *Acta Medica Transilvanica*. 2020 Sep 1;25(3):65-8. [\[DOI\]](#)