

**ORIGINAL RESEARCH ARTICLE****COMPUTED TOMOGRAM GUIDED FINE NEEDLE ASPIRATION FOR LUNG MASSES: RADIOLOGIC-CYTOLOGIC CORRELATION**A Pradhan ^{1*}, G Gurung², NB Thapa¹, K Rijal¹, DB Karki³¹ Kist Medical College and Hospital, Imadol, Lalitpur² Tribhuvan University Teaching Hospital, Maharajgunj, Kathmandu³ Patan Academy of Health Sciences, Lalitpur, Nepal***Correspondence to:** Dr Anup Pradhan, Lecturer, Department of Radiology and Imaging, Kist Medical College and Hospital, Imadol, Lalitpur, Nepal.E-mail: aminupus1@gmail.com**ABSTRACT**

The primary objective was to compare the results of computed tomography (CT) finding with that of cytology. The secondary objective was to evaluate the safety of CT guided transthoracic Fine Needle Aspiration Cytology (FNAC) of lung lesions of various sizes and locations. From December 2014 to June 2016, under CT guidance, FNAC of lung lesion was performed on 64 cases attending KIST medical college and Kathmandu imaging diagnostic center. FNAC was performed by using spinal anesthesia needle (22G/23G). Procedures were carried out under CT guidance. Smears were prepared by materials obtained and were fixed in 95% alcohol. Dry as well as wet slides were prepared. The prepared slides were then examined under light microscope by consultant pathologist. Sixty four patients were enrolled in present study. The age of patients ranges from 24 to 87 year with mean age of 55.5 and male to female ratio of 2:1. Radiologically, out of 64 cases, 49 cases were reported as malignant and 15 cases were reported as benign lesion. However, Cytologically, 39 cases were malignant, 22 cases were benign and 3 cases were suspicious for malignancy (no definite diagnosis established). The CT scan showed Sensitivity of 97.4% to identify the malignant mass as compared to cytology findings. the Specificity, Positive and negative predictive value were calculated as 63.6%, 82.6 and 93.3% respectively. CT guided fine needle aspiration cytology (FNAC) is reliable procedure for evaluation of lung lesion. It is simple and safe procedure with high diagnostic accuracy for the diagnosis of Lung cancer. Compared to biopsy, CT guided FNAC shortens the diagnostic interval and helps in differentiating lung malignancy into different cytopathological types which aids in proper management of the malignant lesion.

Keywords: Computed tomogram, Cytology, FNAC, Lung mass.**INTRODUCTION**

Fine needle aspiration (FNA) is a method of taking cytology sample by means of a fine needle attached with a syringe.¹ CT guided fine needle aspiration cytology is an outpatient method used for the evaluation of suspicious lung mass. It is simple diagnostic method which offers quick and specific diagnosis. At same time it is relatively safe method with negligible mortality and limited morbidity.²

Hagga and Alfid first reported computed tomography (CT) guided biopsy in 1976. Since that time CT guided FNAC is considered procedure of choice in the evaluation of focal chest lesions where ultrasound guided procedure is not possible.³ Ultrasound guided

FNAC has been used as a diagnostic procedure of peripheral lung mass but deep intrathoracic masses cannot be imaged by ultrasonography.⁴ Though FNA can be done for the lung lesion by different radiological procedures like fluoroscopy, USG or CT guidance, CT guided FNA had become popular due to early localization of needle.⁵ While diagnostic sensitivity has been higher for fluoroscopy guidance (97%) than CT guidance (80%), there is a higher rate of complications for FNAC in the former procedure.⁶ Whether the lesion is benign or malignant, clinical data and radiological evaluation with CT might help but does not provide definite diagnosis. The

confirmation of CT finding regarding the nature of the lesion can only be done by histopathological diagnosis. Currently CT FNA for lesions of the lungs and mediastinum is a widely practiced method, where the facilities of standard imaging techniques and cytopathology are available.⁷

One of the major advantages of FNAC is detection of tumor type like small cell carcinoma and lymphoma which can be treated by chemotherapy rather than surgery.⁸ The present study was performed to establish accuracy, safety and pathological spectrum of thoracic lesion using CT guided FNAC.

MATERIALS AND METHODS

Sixty four patients who underwent CT guided FNA from Dec 2014 to Jun 2016 at Kathmandu imaging centre or KIST Medical College, were identified by radiological report review. All these patients cytological report was traced from the pathology department. CT guided FNA was done only for those patients who are cooperative and are able to hold breathe for short. Patients having bleeding tendency, severe COPD, contralateral pneumonectomy or coagulopathy .

For FNAC usually 18 -22 G spinal needle is used. At first, radioopaque marker is kept on site of puncture and CT is done with marker to guide needle entry.

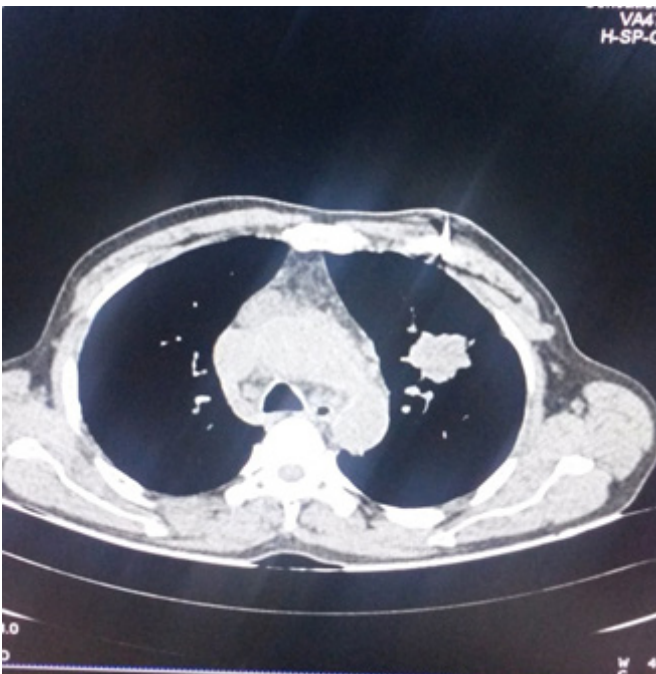


Figure 1: CT image shows well defined soft tissue mass in left upper lobe

After cleaning the surface with betadine and draping, 2% xylocaine is infiltrated at the site of puncture for local anesthesia. The spinal needle is inserted directing tip of needle towards the lesion.

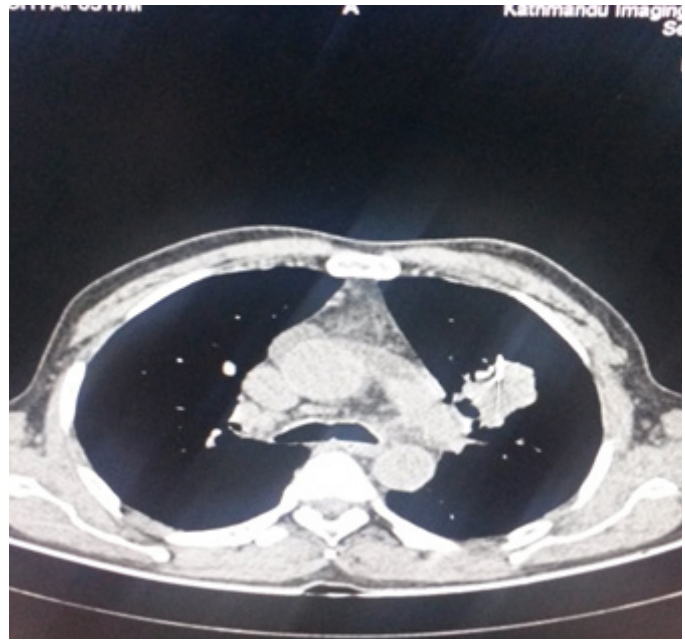


Figure 2: CT shows mass with needle insitu showing CT guided FNAC

Once needle tip is located in lesion, repeat CT of the area of interest is taken to check exact position its tip.

Stylet is removed, 20 cc syringe attached to three way venoline and negative suction maintained and aspiration is carried out. Slides are prepared and both air dried and alcohol fixed (95%alcohol) smears are made for cytological evaluation. Repeat scan of the area of interest is taken to look for pneumothorax. Data was compiled and statistical analysis was done by using statistical package for the social sciences (SPSS) version 17 program.

RESULTS

Sixty four patients were enrolled in present study. The age of patients ranges from 24 to 87 years with mean age of 55.5 years with male to female ratio of 2:1. Radiologically, out of 64 cases, 49 cases were reported as malignant and 15 cases were reported as benign lesion. However, cytologically, 39 cases were malignant, 22 cases were benign whereas 3 cases were suspicious for malignancy (no definite diagnosis established). The CT scan showed sensitivity of 97.4% to identify the

malignant mass as compared to cytology findings. The Specificity, positive and negative predictive value were calculated as 63.6%, 82.6% and 93.3% respectively. Kappa test value of 0.66 and $p < 0.001$ indicated a good significant agreement of the results of CT and cytology. Diagnostic accuracy of CT was 85.2%. Thirty nine cases were malignant, out of which adenocarcinoma and squamous cell carcinoma were in equal number comprising of 12 cases each. Eight cases of lung small cell carcinoma, 2 cases each large cell carcinoma and lymphoma were observed and 5 cases were diagnosed as lesions that were consistent with Tuberculosis. Three cases were diagnosed as fungal infection.

Table 2: Cytological Spectrum Of Disease

Histopathological diagnosis	Freq.	%
Squamous cell carcinoma	12	18.8
Adenocarcinoma	12	18.8
Small cell carcinoma	8	12.5
Large cell carcinoma	2	3.1
Lymphoma	2	3.1
Pulmonary tuberculosis	5	7.8
Inflammatory	5	7.8
Suspicious for malignancy	3	4.7
Negative for malignancy	10	15.6
Fungal infection	3	4.7
Abscess	2	3.1

Table 1: Demographic Description Of Study

Subject	subheadings	Total no	%
Age	Range	24-87	
Sex	Male:Female	43:21	67.2:32.8
Lung involve	Right	35	54.7
	Left	28	43.8
	Both	1	1.6
Lobe involve	Right upper	20	31.2
	Middle	5	7.8
	Right lower	10	15.6
	Left upper	19	29.7
	Left lower	8	12.5
	Lingula	1	1.6
	More than one	1	1.6
Provisional diagnosis	Malignant	49	76.6
	Benign	15	23.4
Cytological findings	Malignant	39	60.9
	Benign	22	34.3
	Suspicious	3	4.6
Sampling	Adequate	61	
	Inadequate	3	

Table 3: Comparison between radiological and cytological diagnosis

CT Diagnosis	Histology		Total	p	Correlation
	Malignant	Benign			
Malignant	38(62.3%)	8(13.1%)	46(75.4%)	<0.001	Sensitivity=97.4 Specificity=63.6 PPV=82.6 NPV=93.3 Accuracy=85.2
Benign	1(1.6%)	14(23%)	15(24.6%)		
Total	39(63.9%)	22(36.1%)	61		

Five cases developed pneumothorax (7.8%) and 1 case (1.6%) had hemoptysis and no one required treatment.

Table 4: Complications

Complications	Frequency	Percent
No complication	58	90.6
Pneumothorax	5	7.8
Hemoptysis	1	1.6

DISCUSSION

The accuracy of CT guided FNAC in the diagnosis of thoracic mass has been widely reported.⁹ It is relatively safe and accurate means of diagnosing benign and malignant lesions of the chest with negligible mortality. Computed tomography (CT) allows the performance of

fine needle aspiration biopsies in situations in which USG or conventional radiograph does not correctly visualize the lesion or the needle track.¹⁰ FNAC is helpful in confirming the diagnosis (benign or malignant nature) which would help the clinicians in deciding the therapeutic management.¹¹ In the present study, all the patients were adults with mean age of 55.5 with range of 24 to 87 years. All the patients were above 20 yrs of age.

There is male preponderance noted. Out of 64 cases there were 43 men (67.2%) and 21 were women (32.8%) . This correlates with the fact that intrathoracic mass occurs most commonly in older males.¹¹ Singh et al (52%), Wallace et al(55.7%), and Prashant et al(48.5%) showed similar incidence while studies by Jacob et al(86.8%) , Ahmed et al (82.7%) found slightly higher male incidence .

It has been mentioned that the diagnostic accuracy of CT guided FNAC is between 66 to 97 percent.¹¹ There was a diagnostic yield of 85.2% in CT guided transthoracic FNAC of our study. Sensitivity of this study was 97.4% and specificity was 63.6%. Positive and negative predictive value of this study were 82.6 and 93.3% respectively. Similarly, Seemann MD et al have reported the sensitivity of 88.9% and specificity of 60.9 in differentiating malignant from non neoplastic lesion. Shrestha MK et al in their study of 257 cases reported a sensitivity and specificity of 95.28% and 57.57% respectively.¹³

Malignant pathology was seen in cytological study in 63.9% cases and a benign pathology in 36.1% case. The prevalence of malignancy in our study is

significantly less than the 81.8% found in similar study done by Singh et al. The prevalence of squamous cell carcinoma and adenocarcinoma were similar (18.8%) in our study similar to the study by Singh et al which was 22%, but study done by Basnet et al showed almost double the incidence of squamous cell carcinoma compared to adenocarcinoma (50% vs 28%) whereas study done by shrestha et al showed higher incidence of adenocarcinoma. The prevalence of small cell carcinoma was 12.5% in our study which is similar to Puneet etal (11%) but very much higher than in the study by JayaShankar et al (3%).

Among the benign lesions, tuberculosis comprised 7.8% of our cases compared to 19.2% study done by Jacob et al. Inflammatory lesions and lymphoma were 7.8 and 3.1 %. Fungal lesion were 3(4.7%), abscess 2(3.1%). The present study showed high degree of concordance rates of cytological diagnosis with that of histological diagnosis.

In this study lung SOLs were located more on the right side 35(54.7%) than left 28(43.8%). Similar results observed by Saha et al³ and Basnet et al⁶. Right upper lobe was most involved lobe comprising of (31.2%) which doesnot match with study done by Prashant et al showing lingula as most effected lobe (42%). Most 17.2% of lesion were between 2.5 to 3 cm where as >3 cm in study done by Prashant et al. There were only 3 cases below 1.5cm.

Pneumothorax is the most frequent complication of the procedure which was 7.8 % which is little high compared to Gupta et al (1%), Shrestha MK et al (2%), Basnet et al (4%), Sarker et al 13%. In most instances the patient can be discharged after a check x-ray and few hours of Observation. Pneumothorax was significantly lower than 42.7%, 29%, 20.9% and 11.8% seen in the studies conducted by Vanssonenberg et al , Stanley et al, Santambrogio et al respectively.¹⁴ There was hemoptysis in only one patient which doesnot require any surgical intervention.

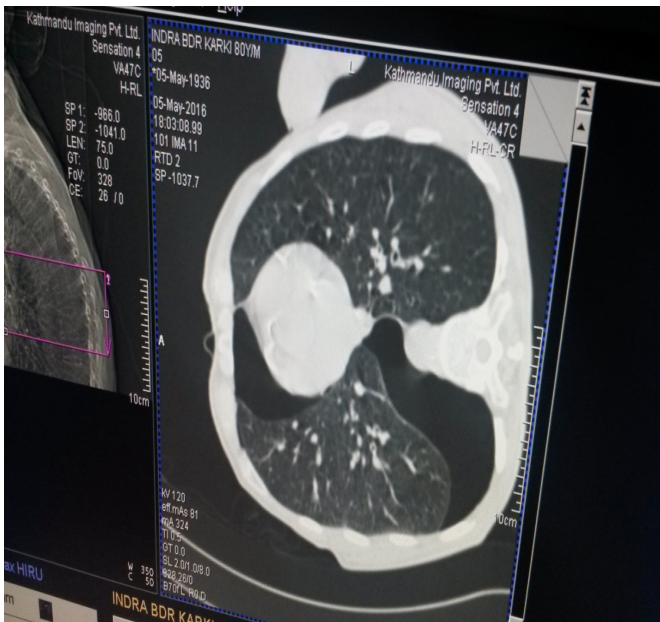


Figure 3: CT shows presence of pneumothorax

Unlike the work done by other researchers, inadequacy was not a big problem in our study (accounting for 3 cases; 4%). The reported rates of inadequacy in other studies range from 16 to 27%.¹⁵ Three cases (6%) categorized as “suggestive but not diagnostic for malignant cells” might have included some cases of large cell carcinoma but could not be labeled as such because of lack of distinctive malignant features in these cases.¹⁶

CONCLUSION

We conclude that CT guided transthoracic needle aspiration cytology allow early diagnosis & is a highly effective procedure in the diagnosis of thoracic masses. This procedure avoids unnecessary exploratory surgery for staging as diagnosis can be made with lesser trauma and at lower cost. It is a relatively simple procedure with good patient compliance and low morbidity. It is highly sensitive and specific technique with a good diagnostic accuracy and can be used safely as an outdoor procedure. Though complications are rare, pneumothorax, hemoptysis are occasionally encountered, but rarely require active management. It has greater role in evaluation of thoracic mass.

REFERENCES

1. Sarker RN, Rabbi AF et al. Computed tomography guided transthoracic fine needle aspiration cytology in the diagnosis of sonographically non-approachable intrathoracic masses: a study of 100 cases. *J Dhaka med coll* 2011;20(1);25-31.
2. Santambrogio L, Nosottim, Bellavity N et al. CT guided fine needle aspiration cytology of solitary pulmonary nodules. *Chest* 1997;112:423-5.
3. Haaga JR, Alfifi RJ. Precise biopsy localization by computed tomography. *Radiology* 1976;118:603-607.
4. Rasmussen, Holm HH, Kristensen JR, Barlebo H. Ultrasonologically guided liver biopsy. *BMJ* 1972;2:500.
5. Puneet Bhardwaj, Rahul Verma et al. Efficacy and Safety of CT guided transthoracic FNAC of lung lesions of various sizes and locations. *Journal of evidenced based medicine and healthcare* 2015;2:20-29.
6. Prashant, C Ramachandra et al Feasibility, safety and Efficacy of the CT guided fine needle aspiration cytology(FNAC) of lung lesions. *Indian Journal of medicine & Pediatric oncology* 2007; 28(2):
7. M Gangopadhyay, I Chakrabarti et al Computed tomography guided fine needle aspiration cytology of mass lesions of lung: our experiences. *Indian Journal of medicine & Pediatric oncology* 2011;32(4):192-196.
8. Sushmita Das (Bala) et al. Lung SOL-cytology and histological correlation in a tertiary care centre. *IOSR-JDMS* 2015;14:18-24.
9. Syed Ahmed et al. Computed Tomography guided fine needle aspiration cytology of lung lesions: A study of 162 cases *JCMCTA* 2009; 20(1):50-52.
10. JP singh, L Garg et al. Computed tomography (CT) guided transthoracic needle aspiration cytology in difficult thoracic mass lesions-not approachable by USG. *Indian J Radiol imaging* 2004;14;395-400.

11. Sumona Ghosh, Sanjay Nath et al. Computed Tomography guided transthoracic fine needle aspiration cytology I early diagnosis of intrathoracic masses in tertiary care hospital of Tripura, Northeast state of India. NJMR July-Sept 2015;5(3).
12. Mohammad GM. CT guided fine needle aspiration cytology in the diagnosis of thoracic lesions. JIMA 2001; 99(10):1-5.
13. Shrestha MK, Ghartimagar D et al. A Computed tomogram guided fine-needle aspiration cytology of lung and mediastinal masses with cytological correlation: A study of 257 cases in Western region of Nepal. Nepal Med Coll J 2014;16(1):80-83.
14. Jacob Baby, Paul George et al. Computed tomography guided fine needle aspiration cytology of thoracic lesions: A retrospective analysis of 114 cases . Journal of Dental and Medical Sciences (IOSR-JDMS) Jan. 2014;13:47-52.
15. Sanjay Piplani, Rahul Mannan et al Cytologic-Radiologic Correlation Using Transthoracic CT-Guided FNA for Lung and Mediastinal Masses: Our Experience. Analytical Cellular Pathology ; Volume 2014, Article ID 343461.
16. Basnet SB, Thapa GB, et al Computed Tomography Guided Percutaneous Transthoracic Fine Needle Aspiration Cytology in Chest Masses. J Nepal Med Assoc 2008;47(171):123-7.