



ISSN: 2091-2889 (online)
2091-2412 (print)

Received: 24 Mar 2025
Accepted: 10 Sep 2025
Published: 31 Oct 2025

DOI: [10.54530/jcmc.1800](https://doi.org/10.54530/jcmc.1800)



Hereditary multiple exostoses in a 13-year-old male: A case report

Sarbin Nepal¹, Achyut Marahatta², Sagun Shrestha³, Shishir Bhandari⁴

¹Bharosa Hospital Chitwan Pvt Ltd., Bharatpur, Nepal

²Chitwan hospital, Bharatpur, Nepal

³Jibjibe PHC, Kathmandu, Nepal

⁴Chitwan Medical College Teaching Hospital, Bharatpur, Nepal



Peer reviewed

Abstract

Hereditary multiple exostoses is a rare autosomal dominant skeletal disorder with multiple cartilage capped benign exostoses occurring at metaphysis of long bones. A 13 years old male presented with multiple nodular lesions in body especially along long bones and was diagnosed as a case of hereditary multiple exostoses (HME) based on clinical picture and x-ray findings and was managed symptomatically. Depending upon the site, number and size of the osteochondromas it can produce variety of clinical features. Having HME increases the risk for developing carcinoma later in life with development of chondrosarcoma more frequently than osteosarcoma. Patient with HME requires special care. While smaller lesions are left untreated and managed symptomatically, larger and symptomatic ones may require surgical excision.

How to cite

Nepal S, Marahatta A, Shrestha S, Bhandari S. Hereditary multiple exostoses in a 13-year-old male: A case report. *Journal of Chitwan Medical College*. 2025;15(55):129-132.

Correspondence

Dr. Sarbin Nepal, Bharosa Hospital Chitwan Pvt Ltd., Bharatpur, Nepal.
Email: nepalsarbin@gmail.com, Telephone: +977 9845912677

Introduction

Hereditary multiple exostoses (HME), also known as hereditary multiple osteochondromas (HMO) is a rare autosomal dominant skeletal disorder characterized by multiple cartilage-capped benign exostoses that typically occur in metaphysis of long bones. It occurs in 1 in 50,000.¹ It is more frequently found in males.² It can lead to varieties of health problems including skeletal deformities, growth disparities and neurovascular impingement. Malignant transformation into either chondrosarcomas or osteosarcomas occurs in about 2%, and can be life threatening.³ Most of these exostoses ceases to grow when the nearest epiphyseal centre fuses i.e. until adolescence. Here, we report a case of 13 years old male child with multiple hereditary exostoses with visible deformities because of its rarity and difficulty in management.

Case history

A 13 years male child referred from district hospital to emergency room for fever and cough for 7 days and pain abdomen for 4 days. He was diagnosed with scrub typhus and treated accordingly. He had multiple bony swelling on bilateral upper and lower limb, present since

last 7 years, and slowly growing in size, Figure 1. The swellings were non-tender, bony hard, irregular, fixed to underlying bone, largest on left distal thigh of around 6x4 cm² in size. Skin overlying the swelling was normal, distal neurovascular status was intact. Orthopaedic consultation was done. After a series of x-rays of limbs, and laboratory investigation a diagnosis of multiple osteochondroma was made.

His serum calcium (7.8), uric acid (2.8), ALP (98) were normal, while LDH (586) was raised.

Radiographs of bilateral knee joint showed the classic findings of HME, including broadening of metaphysis (more in distal femur) and pathognomonic features of osteochondroma with multiple lesions composing of cortical and medullary bone protruding from underlying bone mainly in metaphyseal region, Figure 2 and 3. The cartilage cap was not mineralised and not seen. Most of the lesions were sessile and away from the joint. Mild smooth periosteal reaction was seen in tibia. There is no bony destruction.

Patient was managed for scrub typhus, without surgical interventions for swellings. He was discharge with advice for regular follow-up.

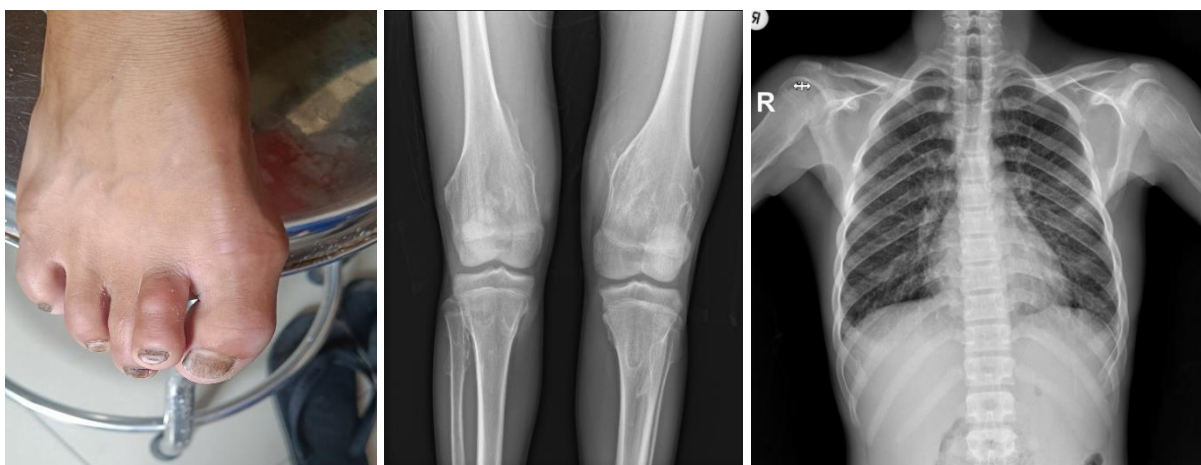


Figure 1. Clinical photograph of right foot showing swelling in first and 2nd toe; **Figure 2.** Radiograph of bilateral knee showing bony outgrowth from femur, tibia and fibula. Similar radiological changes were seen in other x-rays; **Figure 3.** Radiograph of chest showing bony outgrowth in left humerus

Discussion

A 13 years old male presented in our OPD for fever, cough and abdominal pain was incidentally diagnosed with HME. While the patient remained asymptomatic apart from visible deformity, complication could develop at any time. HME is a genetically diverse illness linked to abnormalities in at least three distinct genes known as EXT genes. It's believed that at least two of these genes have tumour-suppressing properties. These mutations may impede healthy cartilage growth, leading to the development of osteochondromas.⁴ It's an autosomal dominant transmission. While an unaffected female may spread the illness in a family with HME, an unaffected male does not. These mutations may impede healthy cartilage growth, leading to the development of osteochondromas.⁴ It's an autosomal dominant transmission. While an unaffected female may spread the illness in a family with HME, an unaffected male does not. Children in families where one parent has HME are nearly 50% more likely to develop the condition. Both sexes are affected almost equally, with males suffering the most.⁵ Limitation of our case report includes lack of follow-up.

Conclusion

A 13-year-old boy was incidentally diagnosed with Hereditary Multiple Exostoses (HME) who presented in emergency department with other illness. He had multiple sessile osteochondromas mainly in metaphyseal regions, fixed to bone, with no cartilage cap mineralization or bony destruction. He had an elevated LDH. The child was managed symptomatically and discharged with advice for regular follow-up.

Author contribution

Concept design: SS; Literature search: AD, AP, DB; Data collection: SB; Draft manuscript: SN, AM; Final manuscript and accountability: All

Acknowledgment

None

Conflict of interest

None

Funding

None

Consent

All appropriate patient consent has been taken in the form of verbal and written. In the consent form, the patient gave consent for images and other clinical information to be reported in the journal. The patient was counselled that name and initials would not be published and that due efforts would be made to conceal identity, but anonymity cannot be guaranteed.

Supplementary material

Data and supplementary material that support the findings of this study are available from the corresponding author upon reasonable request.

References

1. Kanik ZH, Gunaydin G, Sozlu U, Citaker S, Esen E. Eccentric Training as an Adjunct to Rehabilitation Program for Hereditary Multiple Exostoses: A Case Report. *Journal of clinical and diagnostic research: JCDR*. 2016 Feb;10(2):YD03-4. DOI PubMed Google Scholar Full Text
2. Epstein DA, Levin EJ. Bone scintigraphy in hereditary multiple exostoses. *AJR. American journal of roentgenology*. 1978 Feb;130(2):331-3. DOI PubMed Google Scholar Full Text
3. Pacifici M. Hereditary Multiple Exostoses: New Insights into Pathogenesis, Clinical Complications and Potential Treatments. *Current osteoporosis reports*. 2017 Jun;15(3):142. DOI PubMed Google Scholar Full Text
4. Stieber JR, Pierz KA, Dormans JP. Hereditary multiple exostoses: a current understanding of clinical and genetic advances. *Univ Pa Orthop J*. 2001;14:39-48. Google Scholar Full Text

5. Peterson HA. Multiple hereditary osteochondromata. *Clinical Orthopaedics and Related Research*®. 1989 Feb 1;239:222-30. [PubMed](#) [Google Scholar](#) [Full Text](#)
6. Bone JW. Great Ormond Street, London. *Notes and Queries*. 1891 Jun 20;s7-XI(286):489-489. [Link](#)
7. Pikula JR. Hereditary multiple exostoses: a case report. *J Can Chiropr Assoc*. 1996 Mar;40(1):28-33. [PubMed](#) [Google Scholar](#) [Full Text](#)
8. Murphey MD, Choi JJ, Kransdorf MJ, Flemming DJ, Gannon FH. Imaging of Osteochondroma: Variants and Complications with Radiologic-Pathologic Correlation. *RadioGraphics*. 2000 Sep;20(5):1407-34. [PubMed](#) [Google Scholar](#) [Full Text](#)
9. Tuncer S, Erden I, Aydin N, Oge D. Acute spinal cord compression in hereditary multiple exostoses: case report. *Paraplegia*. 1989 Oct;27(5):402-5. [PubMed](#) [Google Scholar](#) [Full Text](#)
10. Schmale GA, Conrad EU, Raskind WH. The natural history of hereditary multiple exostoses. *J Bone Joint Surg Am*. 1994 Jul;76(7):986-92. [DOI](#) [PubMed](#) [Google Scholar](#) [Full Text](#)
11. Vanhoenacker FM, Van Hul W, Wuyts W, Willems PJ, De Schepper AM. Hereditary multiple exostoses: from genetics to clinical syndrome and complications. *European Journal of Radiology*. 2001 Dec;40(3):208-17. [DOI](#) [PubMed](#) [Google Scholar](#) [Full Text](#)
12. Yinusa W, Owoola AM, Esin IA. Hereditary multiple exostoses: case report. *Niger J Clin Pract*. 2010 Jun;13(2):218-22. [PubMed](#) [Google Scholar](#) [Full Text](#)
13. Eke GK, Omunakwe HE, Echem RC. Hereditary multiple exostoses in a 15-year-old boy: A case report and review of literature. *Nig J Paed*. 2016 Oct 20;43(4):295. [Google Scholar](#) [Full Text](#)
14. Sohrabi C, Mathew G, Maria N, Kerwan A, Franchi T, Agha RA; Collaborators. The SCARE 2023 guideline: updating consensus Surgical CAse REport (SCARE) guidelines. *Int J Surg*. 2023 May 1;109(5):1136-1140. [DOI](#) [PubMed](#) [Google Scholar](#) [Full Text](#)