



ISSN: 2091-2889 (online)
2091-2412 (print)

Received: 21 Apr 2024
Accepted: 18 Aug 2024
Published: 30 Sep 2024

DOI: [10.54530/jcmc.1517](https://doi.org/10.54530/jcmc.1517)



Ruptured hepatocellular carcinoma: A case report and review of literature

Sudeep KC¹✉, Himani Poudyal²✉

¹Department of Radiology, Patan Academy of Health Sciences, Lalitpur, Nepal

²Nepal APF Hospital, Kathmandu, Kathmandu, Nepal



Peer reviewed

Abstract

Hemoperitoneum caused by nontraumatic liver rupture is rare. The spontaneous rupture of hepatocellular carcinoma can pose a serious threat to life, particularly in the absence of cirrhosis. Ruptured hepatocellular carcinoma (HCC) is a medical emergency with a high mortality rate, and diagnosing it can be challenging. Treatment options vary depending on resources and the stage of HCC.

This case report focuses on the CT findings of a 52-year-old gentleman who was initially diagnosed with hemoperitoneum resulting from the spontaneous rupture of HCC at the emergency department. The patient underwent trans-arterial embolization (TAE) for hemostasis. Timely identification and intervention for ruptured HCC are essential. This particular case underscores the importance of early detection and immediate treatment for ruptured HCC.

This case report delves into an instance of spontaneous HCC rupture in a patient without liver cirrhosis. While radiological imaging plays a crucial role in confirming the diagnosis. It also helps in treatment plans which include consideration of surgical, and interventional procedures as well as chemotherapy.

Keywords: Embolization, Hepatocellular carcinoma, Hemoperitoneum, Trans Arterial Embolization TAE

How to cite

KC S, Poudyal H. Ruptured hepatocellular carcinoma: A case report and review of literature. *Journal of Chitwan Medical College*. 2024;14(49):123-7.

Correspondence

Sudeep KC, Department of Radiology, Patan Academy of Health Sciences, Lalitpur, Nepal. Email: drsudeepkc@gmail.com, Telephone: +977 9851168399

Introduction

Hepatocellular carcinoma (HCC) is the most common type of liver cancer worldwide, ranking sixth in frequency and third in cancer-related deaths, men affected more than women, and the incidence of HCC is expected to rise due to liver cirrhosis, chronic hepatitis and non-alcoholic steatohepatitis.¹ Despite advances in diagnostic and therapeutic modalities, HCC remains a formidable challenge due to its aggressive nature and potential for complication. One of such complication is spontaneous rupture with hemoperitoneum which presents as a life-threatening emergency requiring immediate attention and intervention.²⁻⁸ Here, we describe the clinical presentation, radiological features, and management of a patient with ruptured HCC who was managed successfully.

Case report

A 52-year gentleman was brought to the emergency department of Patan Hospital, Patan Academy of Health Sciences, Nepal, after suddenly collapsing during his daily work. Physical examination revealed hepatomegaly and diffuse abdominal tenderness. His blood pressure was 80/50 mmHg and heart rate 128 bpm. Laboratory parameters were as follows: haemoglobin: 9 g/dL, direct bilirubin 1 mg/dL, alanine aminotransferase 94 U/L (normal 0 to

40), aspartate aminotransferase 80 IU/L. The serology findings were positive for hepatitis C virus (HCV).

Ultrasonography showed ill-defined subcapsular lesion measuring approximately 6 x 5 cm in right lobe of liver with irregular margin. Gross ascites was seen which was confirmed as hemoperitoneum on diagnostic aspiration.

Contrast enhanced computed tomography (CECT) abdomen and pelvis showed heterogeneously enhancing ill-defined lesion with small exophytic component measuring about 6.5 x 5.4 x 10.1 cm (TR x AP x CC) noted in subcapsular region of segment VIII and IV of liver. The lesion was contiguous with enhancing filling defect in adjacent segmental portal vein extending up to the portal bifurcation. The exophytic component protruding from the hepatic surface shows focal discontinuity possibly due rupture through the capsule. Few hypovascular lesions were noted in right lobe of liver in segment VII and VIII, one of them measuring 2.8 x 2.0 cm in segment VIII, Figure 1.

Diagnosis of hemoperitoneum secondary to liver lesion rupture was made. Alpha-protein was 500 IU/L. The CA 19.9 and CEA was within normal range. The contrast enhancement of the liver lesion and increased Alpha-feto-protein were compatible with HCC with intrahepatic metastasis and portal vein thrombosis.

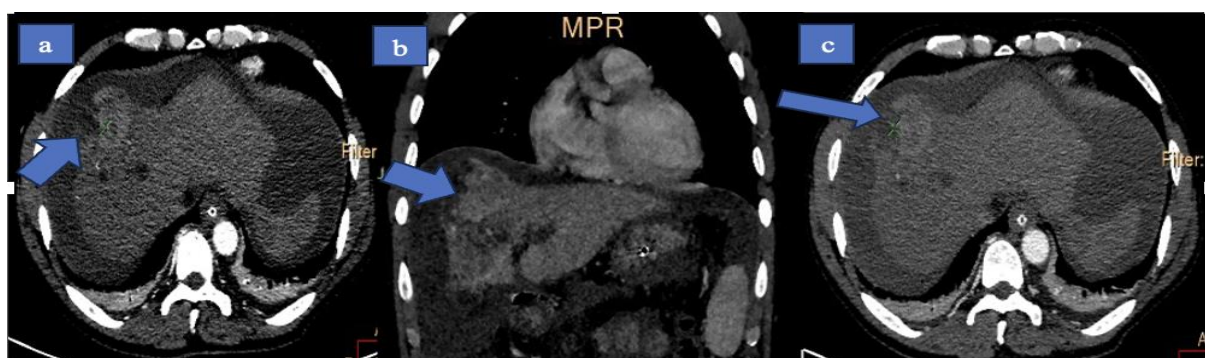


Figure 1. MDCT arterial phase, enhancing lesion in subcapsular region of right lobe of liver segment VIII with capsular breach

Transcatheter arterial embolization (TAE) was unavailable at the time of presentation. Conservative management for hypovolemic shock that included fluid resuscitation, multiple

blood transfusion was initiated and planned for TAE. Angiogram of the celiac axis revealed no active extravasation of contrast at the time of angiogram. In view of fluctuating haemoglobin

level and multiple blood transfusion. TAE was performed using 2.7 Fr microcatheter, 280-300 micron PVA particles and gelfoam emulsion. Final angiogram showed slow flow in segment VII/VIII hepatic arteries. He made an uneventful

recovery, Figure 2.

At 2 months follow-up he was doing well and is currently under oral lenvatinib therapy under oncology department in the hospital.

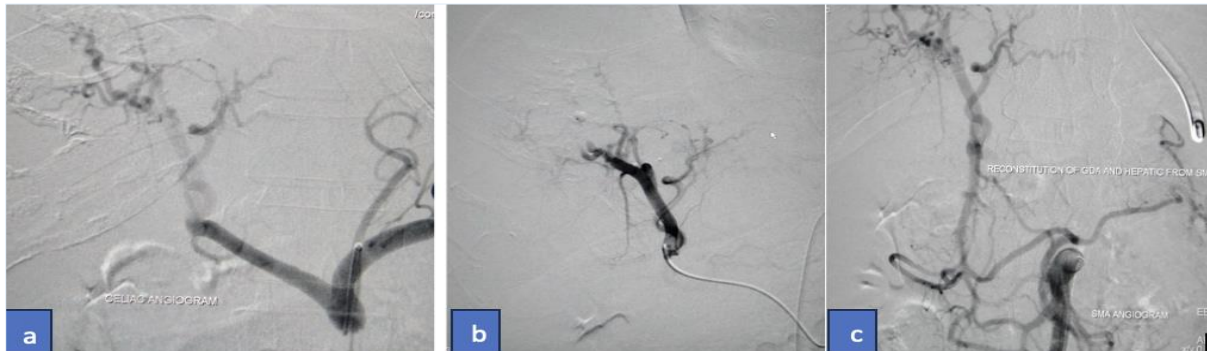


Figure 2. Trans Arterial Embolization TAE angiographic images, (a) shows no active extravasation of contrast, (b) post embolization slow flow in the lesion, (c) reconstitution of gastroduodenal hepatic artery from superior mesenteric artery

Discussion

The occurrence of spontaneous rupture in HCC varies between 3-26%, with a higher rate of spontaneous rupture without prior diagnosis reported in 41 to 75%. Ruptured HCC has a mortality rate of between 32-66%. The incidence of spontaneous rupture in HCC is more prevalent in Asia and Africa compared to Europe.²

The exact cause of spontaneous rupture still remains unknown. Studies show HCC of a size of >5.5cm, left lobe, subcapsular location, rapid growth, blood vessel erosion and trauma are risk factors for rupture.³

Symptoms of rupture include sudden abdominal pain, distention, and shock. Rupture can lead to significant blood loss and peritoneal spread of cancer cells, worsening the prognosis.⁴

Diagnosis of ruptured HCC can pose a challenge, particularly in patients lacking a history of liver cirrhosis, liver tumour, HBV or HCV infection, and in instances of hemodynamic instability. Only a quarter of patients receive a preoperative diagnosis, but the accuracy has increased with the use of imaging modalities such as ultrasound, CT scans, and celiac angiography, confirming the diagnosis in 66-75% of cases. The CT scans are effective in detecting HCC and identifying

bleeding, although pinpointing the exact location of the bleeding can be challenging.

Hepatic angiography can reveal contrast material extravasation in 13.2 to 35.7% of cases.⁵ The HCC typically exhibits arterial enhancement followed by contrast attenuation in later phases. Signs of ruptured of HCC on CT include hemoperitoneum, perihepatic hematoma, contrast leakage, interruption of the hepatic surface, and "enucleation sign" characterized by a non-enhancing low attenuating lesion with peripheral rim enhancement and hepatic surface discontinuity.⁶

Primary management involves stabilizing the patient's hemodynamic, administering blood transfusions, and addressing coagulopathy. Emergency liver resection is effective only for patients where complete tumour removal is possible with sufficient liver function. The TAE involves hepatic angiography and occlusion of the bleeding artery using materials like gelatine sponges. While the success rate ranges from 53% to 100%, it may not be feasible in up to 20% of patients due to various factors. Although TAE has favourable haemostatic effects, its therapeutic benefit is lower compared to hepatectomy.

A staged approach involving TAE followed by surgery may be suitable for selected patients.⁷ A

review of 15 studies involving 835 patients with ruptured HCC found that the 30-day mortalities for conservative treatment, emergency surgical procedures, and TAE were 71%, 50%, and 38%, respectively.⁴

The main contraindication for TAE is main portal vein thrombosis. In our case, TAE was chosen as a bridging therapy for further diagnosis and to improve overall survival. Treatment options for advanced HCC include liver resection, transplantation, and chemotherapy, with individualized decisions based on staging systems and guidelines.

The Barcelona Clinic Liver Cancer classification (BCLC) staging system takes into account tumour-related, patient-related, and liver disease-related factors.⁸ Our patient falls within the Intermediate to Advanced category, suggesting palliative care is recommended. A TAE is preferred for intermediate stage tumours, offering significant survival benefits.

Surgery is an effective approach for HCC, with survival rates ranging from 50% to 70% for intermediate/advanced cases. Curative surgery for HCC involving the gastrointestinal tract has a median survival of 9.7 months. Typically, patients with Child A/B cirrhotic liver and mild or no portal hypertension are considered suitable candidates for surgical resection.

Non-resectability may be due to factors like extrahepatic tumour, poor patient health, tumour infiltration into all liver veins, or inadequate functional liver post-resection.⁹ The current TNM staging system, developed by the AJCC/UICC, classifies all ruptured HCCs as stage T4 with very poor prognosis, which has always been controversial.

In cases of insufficient functional liver, such as in liver cirrhosis, transplantation may be an alternative.⁴ Milan criteria are used to assess suitability in patients for liver transplantation with cirrhosis and HCC.¹⁰ Spontaneous rupture of previously undiagnosed

The HCC can be challenging in emergencies, often presenting with acute abdomen symptoms.

It is important to consider HCC as the primary diagnosis in cases of spontaneous hemoperitoneum in individuals with liver lesions. Treatment requires multidisciplinary approach between emergency physicians, gastroenterologists, interventional radiologists, and surgeons for management.

Conclusion

This case highlights the successful management of a challenging case of spontaneous rupture of undiagnosed hepatocellular carcinoma presenting in shock. Transarterial embolization was successful in saving the patient life with a multidisciplinary team effort between emergency physicians, gastroenterologists, interventional radiologists and surgeons.

Author contribution

Concept and design- All (SKC, HP); Literature review- All; Data collection and analysis- All; Draft- All; Revision- All; Accountability- All authors have read and agreed to the final version of the manuscript.

Acknowledgment

None

Conflict of interest

None

Funding

None

Supplementary material

The data and supplementary material that support the findings of this study are available from the corresponding author upon reasonable request.

Consent

Written informed consent was obtained from the patient(s) for publication of this case report, including accompanying images.

References

1. Chidambaranathan-Reghupaty S, Fisher PB, Sarkar D. Hepatocellular carcinoma (HCC): Epidemiology etiology and molecular classification. *Adv Cancer Res.* 2021;149:1-61. [DOI](#) [PubMed](#) [Google Scholar](#) [Full Text](#)
2. Sahu SK, Chawla YK, Dhiman RK, Singh V, Duseja A, Taneja S, et al. Rupture of Hepatocellular Carcinoma: A Review of Literature. *J Clin Exp Hepatol.* 2019 Mar-Apr;9(2):245-256. [DOI](#) [PubMed](#) [Google Scholar](#) [Full Text](#)
3. Jang JY, Jeon UB, Kim JH, Kim TU, Ryu H, Cho M, et al. A Case of Spontaneous Rupture of Hepatocellular Carcinoma Supplied by the Right Renal Capsular Artery Treated by Transcatheter Arterial Embolization. *J Liver Cancer.* 2019 Mar 31;19(1):59–63. [DOI](#) [PubMed](#) [Google Scholar](#) [Full Text](#)
4. Xia F, Ndhlovu E, Zhang M, Chen X, Zhang B, Zhu P. Ruptured Hepatocellular Carcinoma: Current Status of Research. *Front Oncol.* 2022 Feb 17;12:848903. [DOI](#) [PubMed](#) [Google Scholar](#) [Full Text](#)
5. Pinal-García DF, Nuño-Guzmán CM, Gmez-Abarca A, Corona JL, Espejo I. Spontaneous Rupture of Hepatocellular Carcinoma in a Young Patient with Fatal Outcome. *Case Rep Gastroenterol.* 2018 Jan 17;12(1):19–26. [DOI](#) [PubMed](#) [Google Scholar](#) [Full Text](#)
6. Sandomenico F, Arpaia V De, Rosa F, Catalano O, Buonaiuto RA, Notarangelo M, et al. Spontaneously Ruptured Hepatocellular Carcinoma: Computed Tomography-Based Assessment. *Diagnostics.* 2023 Mar 7;13(6):1021. [DOI](#) [PubMed](#) [Google Scholar](#) [Full Text](#)
7. Lai EC, Lau WY. Spontaneous rupture of hepatocellular carcinoma: a systematic review. *Arch Surg.* 2006 Feb;141(2):191-8. [DOI](#) [PubMed](#) [Google Scholar](#) [Full Text](#)
8. Lurje I, Czigany Z, Bednarsch J, Roderburg C, Isfort P, Neumann UP, et al. Treatment Strategies for Hepatocellular Carcinoma – a Multidisciplinary Approach. *Int J Mol Sci.* 2019 Mar 22;20(6):1465. [DOI](#) [PubMed](#) [Google Scholar](#) [Full Text](#)
9. Madkhali A, Fadel Z, Aljiffry M, Hassanain M. Surgical Treatment for Hepatocellular Carcinoma. *Saudi J Gastroenterol.* 2015;21(1):11. [DOI](#) [PubMed](#) [Google Scholar](#) [Full Text](#)
10. Loyola PS, Bautista D, Bautista KA, White EG, Moreno JA, del Real DA, et al. Prognostic role of selection criteria for liver transplantation in patients with hepatocellular carcinoma: Review and bibliometric. *iLIVER.* 2024 Feb 6:100077. [DOI](#) [PubMed](#) [Google Scholar](#) [Full Text](#)