



Role of MRI in the Diagnosis and Characterization of Adnexal Masses in a Tertiary Hospital of Central Nepal

V. Natraj Prasad ¹

¹Department of Radiodiagnosis, College of Medical Sciences-Teaching Hospital, Bharatpur, Chitwan, Nepal.

ABSTRACT

Background

Adnexal masses represent a wide spectrum of gynecological conditions, ranging from benign cysts to malignant ovarian tumors. Accurate diagnosis and characterization are critical for clinical decision-making, including surgical planning, fertility preservation, and oncological referral. Magnetic Resonance Imaging (MRI), with superior soft-tissue contrast, multiplanar capability, and functional imaging techniques, offers improved characterization of adnexal masses. The objective of this study was to evaluate the diagnostic role of MRI in detecting and characterizing adnexal masses.

Methods

A hospital-based cross-sectional study was conducted among 80 female patients with adnexal masses identified on USG at the department of Radiology of College of Medical Sciences and Teaching Hospital, Bharatpur, Chitwan, Nepal. All patients undergo MRI evaluation followed by surgical excision and histopathological confirmation. Data were entered and analyzed using SPSS-20. p -value <0.05 was considered as statistically significant.

Results

Among all patients, the mean \pm SD of age was 38.42 \pm 6.28 years. Most of the patients (25%) were in 30-39 years with 62.5% premenopausal. Histopathology revealed 68.8% benign and 31.2% malignant lesions. MRI demonstrated sensitivity 85%, specificity 72%, PPV 78%, NPV 80%, and overall accuracy 77.5%. Restricted diffusion, solid components, peritoneal deposits, and contrast enhancement were significantly associated with the type of masses (p -value <0.05).

Conclusions

MRI is a reliable imaging modality for differentiating benign from malignant adnexal masses, identifying key imaging markers, and guiding clinical management. Integration of MRI into diagnostic pathways improves patient care and reduces unnecessary interventions.

Keywords: MRI; adnexal mass; ovarian tumor; diagnostic accuracy; histopathology

Correspondence: Dr. V. Natraj Prasad, Department of Radiodiagnosis, College of Medical Sciences-Teaching Hospital, Bharatpur, Chitwan, Nepal. Email: natrajyoga@yahoo.com, Phone: +977-9855058464. **Article received:** 2025-11-02. **Article accepted:** 2025-12-10. **Article published:** 2025-12-28.

INTRODUCTION

Adnexal masses are a broad spectrum of gynecological conditions ranging from benign cysts to malignant ovarian tumors. Accurate diagnosis and characterization of these masses are essential, as they affect clinical management decisions- like the need for surgery, fertility preservation, and oncological referral.¹ Ultrasound (USG), particularly transvaginal ultrasound, is 1st line imaging modality due to its accessibility and cost-effectiveness, it has limitations in complex or indeterminate cases, especially when the lesion shows atypical morphology or arises in patients with obesity, bowel gas interference, or equivocal sonographic findings.² Magnetic Resonance Imaging (MRI) is a powerful diagnostic tool in such scenarios. With its excellent soft-tissue contrast resolution, multiplanar capability, and absence of ionizing radiation, MRI allows detailed assessment of adnexal masses and their relationship with adjacent pelvic structures.³ It helps in differentiating benign from malignant lesions, characterizing indeterminate adnexal masses, and staging ovarian and adnexal malignancies. Advanced MRI techniques like diffusion-weighted imaging (DWI), dynamic contrast-enhanced (DCE) imaging, and apparent diffusion coefficient (ADC) mapping, provide functional information that complements morphologic evaluation, improving diagnostic accuracy.⁴

METHODS

This study was a hospital-based cross-sectional study conducted in the Departments of Radiology of College of Medical Sciences and Teaching Hospital, Bharatpur-10, Chitwan, Nepal, from September 2024 to October, 2025. Ethical approval was taken from Institutional review Committee (IRC) of College of Medical Sciences and Teaching Hospital (COMSTH) (Ref No. :COMSTHIRC/2023-123-90). Informed written consent was taken from all the patients before data collection, and confidentiality

of patient information was strictly maintained throughout the study. This study included all female patients presenting with adnexal masses detected on ultrasound (USG) and referred for MRI evaluation. The study population consisted of 80 female patients of all age groups who met the inclusion criteria. Patients were included if they had an adnexal mass identified on ultrasound, were willing to undergo MRI, and subsequently underwent surgical excision with histopathological confirmation, which served as the gold standard for diagnosis. Patients with contraindications to MRI (pacemakers, metallic implants and severe claustrophobia), pregnant women, and those who did not undergo surgery or histopathology were excluded from the study.

Demographic and clinical information, including age, menopausal status, and presenting symptoms such as abdominal pain, abdominal distension, palpable abdominal mass, and menstrual irregularities, was collected through patient interviews and medical record review. MRI examinations were performed following a standard pelvic protocol, including T1-weighted, T2-weighted, diffusion-weighted imaging (DWI), dynamic contrast-enhanced (DCE) imaging, and apparent diffusion coefficient (ADC) mapping. MRI was used to evaluate specific features of adnexal masses, including the presence of solid components, peritoneal deposits, ascites, contrast enhancement, and restricted diffusion. These imaging findings were recorded and later compared with histopathological results.

The diagnostic performance of MRI was evaluated through standard parameters, including sensitivity, specificity, positive predictive value (PPV), negative predictive value (NPV), and overall accuracy. A 2×2 cross-tabulation of MRI findings versus histopathology was constructed to calculate these diagnostic metrics.

Data were coded and entered into Microsoft Excel and analyzed using SPSS version 20. Continuous variables, such as age, were expressed as mean ±

standard deviation, while categorical variables, including MRI features and histopathological type, were presented as frequencies and percentages. The association between MRI findings and histopathological diagnosis was assessed using the Chi-square test for categorical variables. p-value of <0.05 was considered statistically significant.

RESULTS

A total of 80 female patients with adnexal masses were included in this study. The age of the participants ranged from 18 to 75 years. The mean±SD age of was 38.42±6.28 years. Majority of the patients (25%) belonged to the 30–39 years age group, followed by 18–29 years (20%) and 40–49 years (20%). Regarding menopausal status, 50 (62.5%) women were premenopausal, while 30 (37.5%) were postmenopausal. The most common presenting symptom was abdominal pain, observed in 44 (55%) patients, followed by abdominal distension in 20 (25%), palpable abdominal mass in 12 (15%), and menstrual irregularity in 4 (5%) cases (Table 1).

Table 1. Clinicodemographic information of patients (n = 80)	
Variables	Frequency (%)
Age (years)	
18–29	16(20)
30–39	20(25)
40–49	16(20)
50–59	15(18.8)
≥60	13(16.2)
Mean±SD	38.42±6.28 years
Menopausal Status	
Premenopausal	50(62.5)
Postmenopausal	30(37.5)
Presenting Symptoms	
Abdominal pain	44(55)
Abdominal distension	20(25)
Palpable mass	12(15)
Menstrual irregularity	4(5)

Histopathological examination confirmed that the majority of adnexal masses were benign, accounting for 55 (68.8%) cases, while 25 (31.2%) were malignant (Figure 1).

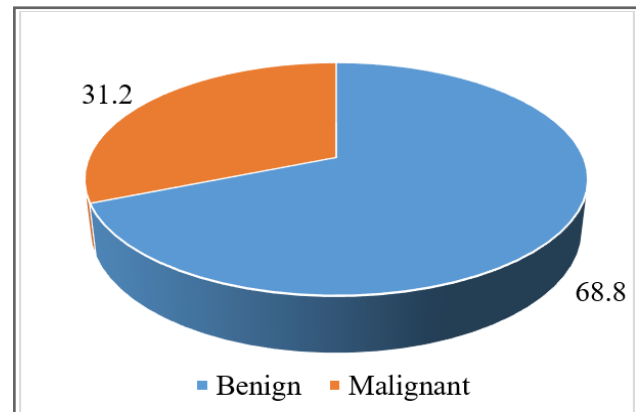


Figure 1. Histopathological Distribution of Adnexal Masses (n=80).

Restricted diffusion was observed in 18 (72%) malignant masses and 6 (10.9%) benign masses. The association between restricted diffusion and the type of adnexal mass was found to be statistically significant (χ^2 -value=30.545, p-value <0.001). Among 25 malignant cases, 7 (28%) showed the presence of peritoneal deposits, whereas 18 (72%) had no deposits. In contrast, among 55 benign lesions, only 1 (1.8%) case demonstrated peritoneal deposits, and 54 (98.2%) had none. Peritoneal deposits were found to have a statistically significant association with malignant adnexal masses (χ^2 -value=13.091, p-value =0.003). Among 25 malignant cases, 16 (64%) showed the presence of solid components, while 9 (36%) did not. In contrast, only 5 (9.1%) of 55 benign lesions demonstrated solid components, with the majority 50 (90.9%) showing purely cystic or septated morphology. Solid components on MRI were significantly associated with malignant adnexal masses (χ^2 -value=26.768, p-value <0.001). Among 25 malignant adnexal masses, 5 (20%) exhibited contrast enhancement, while 20 (80%) showed no enhancement. Conversely, among 55 benign lesions, 47 (85.5%) demonstrated contrast enhancement, whereas 8 (14.5%) did not show enhancement. Contrast enhancement showed a statistically significant association with the type of adnexal mass (χ^2 -value=32.368, p-value <0.001) (Table 2).

MRI correctly identified 21 of 25 malignant masses (true positives) and 40 of 55 benign masses (true

Table 2. Association between restricted diffusion, peritoneal deposits, solid components and contrast enhancement with type of mass (n=80)				
Variables	Type of Mass		Chi-square	p-value
	Malignant	Benign		
Restricted diffusion				
Present	18 (72)	6(10.9)	30.545	<0.001
Absent	7(28)	49(89.09)		
Peritoneal deposits				
Present	7(28)	1(1.8)	13.091	0.003
Absent	18(72)	54(98.2)		
Solid components				
Present	16(64)	5(9.1)	26.768	<0.001
Absent	9(36)	50(90.9)		
Contrast Enhancement				
Present	5 (20)	47 (85.5)	32.368	<0.001
Absent	20 (80)	8 (14.5)		

negatives). Four malignant masses were misdiagnosed as benign (false negatives), and 15 benign masses were misdiagnosed as malignant (false positives). MRI demonstrated high sensitivity (85%) and good specificity (72%), with an overall diagnostic accuracy of 77.5%, confirming its value in differentiating benign from malignant adnexal masses. There is a significant association between MRI diagnosis and Histopathology diagnosis (χ^2 -value=32.347, p-value <0.001) (Table 3).

Table 3. Diagnostic performance of MRI in differentiating benign and malignant adnexal masses compared with histopathological findings (n = 80)

MRI Diagnosis	Histopathology		Total
	Malignant	Benign	
Malignant	21 (TP)	15 (FP)	36
Benign	4 (FN)	40 (TN)	44
Total	25	55	80

Table 4. Diagnostic accuracy parameters.

Parameter	Value (%)
Sensitivity	85
Specificity	72
Positive Predictive Value (PPV)	78
Negative Predictive Value (NPV)	80
Overall Accuracy	77.5

DISCUSSION

The present study was conducted among 80 patients with adnexal masses. Among all patients, the mean \pm

SD as 38.42 ± 6.28 years with age range from 18 to 75 years. Most patients (25%) were aged 30–39 years, followed by 18–29 years (20%) and 40–49 years (20%). In a study by Al-Shukri et al., mention the mean age as 28 years.⁵ This might be due to different in the study population. Adnexal masses were most prevalent in women of reproductive age group.⁶ Among all 62.5% patients were premenopausal while 37.5% were postmenopausal. This study found that the most common presenting symptom was abdominal pain (55%), followed by abdominal distension (25%), palpable mass (15%), and menstrual irregularity (5%). Subramanyam et al., found that the most frequent presenting symptoms among patients with adnexal masses were lower abdominal pain (88%) and a palpable lump in the lower abdomen (32%).¹ Abdalla et al., reported abdominal pain in 77.5% of cases, vaginal bleeding in 20%, and asymptomatic presentation in 12.5% of patients.⁷ Although ultrasound is less effective in determining the exact origin of a mass, it serves as an important initial tool for detecting adnexal masses. However, MRI provides superior accuracy in tissue characterization.⁸ MRI demonstrated high sensitivity (85%) and 72% specificity, with an overall diagnostic accuracy of 77.5%, confirming its value in differentiating benign from malignant adnexal masses. There is a statistically

significant association between MRI diagnosis and Histopathology diagnosis (χ^2 -value=32.347, p-value <0.001). Likewise, Subramanyam et al., found that MRI showed 100% sensitivity and 97.7% specificity in the detection and characterization of adnexal masses, indicating its high diagnostic accuracy.¹ Similarly, a study by Aslam Sohaib et al., reported MRI sensitivity of 95% and specificity of 88% for adnexal mass characterization.⁶ A meta-analysis by Kinkel K et al., reported that MRI had a sensitivity of 100% and specificity of 94% for diagnosing malignancy in indeterminate adnexal masses. MRI is highly effective in confidently diagnosing many common benign adnexal lesions. Thus, women with indeterminate pelvic masses on ultrasound but a low clinical risk of malignancy are most likely to benefit from MRI.⁹ In a study by Guerra A et al., MRI demonstrated a sensitivity of 98% and specificity of 93% for detecting malignancy.¹⁰ In a study by Madan MK et al., the sensitivity of grayscale USG for detecting adnexal masses was 92.5%, which is higher than the 80% sensitivity observed in our study.¹¹ A study published in the Journal of Clinical Imaging Science reported that MRI had a sensitivity of 75% and specificity of 100%, with an overall diagnostic accuracy of 91.43% when compared to histopathology.¹² Similarly, another study in the journal of clinical and diagnostic research found MRI sensitivity and specificity to be 95% and 94.37%, respectively, with a diagnostic accuracy of 94.7%.¹³ Furthermore, Avesani et al.,¹⁴ in the ESR Essentials series, reviewed the role of MRI in the evaluation of adnexal masses, providing standardized recommendations for imaging protocols and interpretation. The study emphasized MRI's high diagnostic accuracy in distinguishing benign from malignant lesions, its complementary role to ultrasound, and its value in guiding clinical and surgical decision-making. Several studies have demonstrated that MRI serves as a valuable problem-solving modality for identifying the origin of pelvic masses

and characterizing adnexal lesions, especially in cases with ambiguous clinical findings. Moreover, MRI is effective in detecting local invasion as well.^{15,16} Saroja Adusumilli et al.,⁸ reported that MRI demonstrated a sensitivity of 100% in identifying adnexal masses and a specificity of 94% for detecting benign lesions. Their study showed an excellent agreement between MRI findings and the final diagnosis in determining the origin ($\kappa = 0.93$), tissue content ($\kappa = 0.98$), and tissue characteristics ($\kappa = 0.91$) of the masses. In contrast, ultrasonography exhibited poor agreement with the final diagnosis regarding the origin ($\kappa = 0.19$) and tissue content ($\kappa = 0.33$) of the masses. Our research showed that MRI had high sensitivity (85%) and good specificity (72%), with an overall diagnostic accuracy of 77.5%, confirming its value in differentiating benign from malignant adnexal masses. There is a significant association between MRI diagnosis and Histopathology diagnosis (χ^2 -value=32.347, p-value <0.001). Study conducted by AWAIS et al., found the sensitivity, specificity, positive predictive value (PPV), negative predictive value (NPV), and overall diagnostic accuracy of MRI in detecting adnexal masses as 95%, 94.37%, 94.37%, and 94.7%, respectively, when compared to histopathology as the gold standard.¹⁷

CONCLUSIONS

MRI plays a vital role in the diagnosis and characterization of adnexal masses, offering high sensitivity, specificity, and overall diagnostic accuracy. MRI is particularly valuable in differentiating benign from malignant lesions and in identifying key imaging features such as restricted diffusion, solid components, peritoneal deposits, contrast enhancement, and ascites, which are significantly associated with malignancy. By providing detailed morphologic and functional information, MRI guides appropriate clinical management, aids in surgical planning, and helps in making informed decisions regarding fertility preservation and

oncological referral. The integration of MRI into routine diagnostic pathways enhances patient care by improving diagnostic confidence, reducing unnecessary surgical interventions for benign lesions, and ensuring timely intervention for malignant cases. Therefore, MRI should be considered an essential

imaging modality in the comprehensive evaluation of adnexal masses in tertiary health care settings.

Conflict of interest: None

Funding: None

REFERENCES

1. Subramanyam AJJ, Cheedalla SP, Bulkapuram V, Madireddy V, Kumari V. Role of MRI in the Evaluation of Adnexal Masses-A Prospective Study. 2021 [Link]
2. Anand R, Garg A, Manchanda S, Popat P, Batra R, Amina N, Et Al. Icri Guidelines For Imaging Protocols In Women's Imaging. 2020 [Link]
3. Kido A, Himoto Y, Moribata Y, Kurata Y, Nakamoto Y. MRI in the Diagnosis of Endometriosis and Related Diseases. Korean journal of radiology. 2022;23(4):426. [DOI]
4. Kubik-Huch RA, Weston M, Nougaret S, Leonhardt H, Thomassin-Naggara I, Horta M, et al. European Society of Urogenital Radiology (ESUR) guidelines: MR imaging of leiomyomas. European radiology. 2018;28(8):3125–37. [Google Scholar]
5. MP SS, Venkateshwaran K, Gokulakrishnan R, Paul S, Ramraj B. Role of Magnetic Resonance Imaging in Evaluation of Adnexal Pathologies and Correlation with Sonography. [DOI]
6. Sohaib SA, Mills T, Sahdev A, Webb J, Vantrappen P, Jacobs I, et al. The role of magnetic resonance imaging and ultrasound in patients with adnexal masses. Clinical radiology. 2005;60(3):340–8. [DOI]
7. Abdalla N, Bachanek M, Trojanowski S, Cendrowski K, Sawicki W. Diagnostic value of ultrasound indicators of neoplastic risk in preoperative differentiation of adnexal masses. Journal of Ultrasonography. 2013;13(53):145. [DOI]
8. Adusumilli S, Hussain HK, Caoili EM, Weadock WJ, Murray JP, Johnson TD, et al. MRI of sonographically indeterminate adnexal masses. American journal of roentgenology. 2006;187(3):732–40. [DOI]
9. Kinkel K, Lu Y, Mehdizade A, Pelte MF, Hricak H. Indeterminate ovarian mass at US: incremental value of second imaging test for characterization—meta-analysis and Bayesian analysis. Radiology. 2005;236(1):85–94. [DOI]
10. Guerra A, Cunha TM, Félix A. Magnetic resonance evaluation of adnexal masses. Acta Radiologica. 2008;49(6):700–9. [DOI]
11. Madan R, Narula M, Chitra R, Bajaj P. Sonomorphological and color doppler flow imaging evaluation of adnexal masses. Indian Journal of Radiology and Imaging. 2004;14(4):NA-NA. [Link]
12. Jalili A, Afzali N. Diagnostic Value of MRI Compared to Histopathological Results in Differentiating Benign from Malignant Ovarian Masses. Maedica. 2024;19(1):4. [DOI]
13. Yaqoob J, Alam MS, Khalid N. Diagnostic accuracy of Magnetic Resonance Imaging in assessment of Meniscal and ACL tear: Correlation with arthroscopy. Pakistan journal of medical sciences. 2015;31(2):263. [DOI]
14. Avesani G, Panico C, Nougaret S, Woitek R, Gui B, Sala E. ESR Essentials: characterisation and staging of adnexal masses with MRI and CT—practice recommendations by ESUR. European Radiology. 2024;34(12):7673–89. [Link]
15. Chilla B, Hauser N, Singer G, Trippel M, Froehlich JM, Kubik-Huch RA. Indeterminate adnexal masses at ultrasound: effect of MRI

imaging findings on diagnostic thinking and therapeutic decisions. *European radiology*. 2011;21(6):1301–10.[[Link](#)]

16. Salem FM, Alarabawy RA, El-Ebiary MT, Edorf AA, Abozeid SM. Imaging modalities in the

differentiation of various adnexal lesions. *Tanta Medical Journal*. 2016;44(2):39–52. [[Link](#)]

17. Awais A, Sarfraz S, Saleem F, Sajjad S, Tariq T, Aruj Agn. The diagnostic accuracy of dynamic MRI in diagnosis of complex adnexal masses. *Age (years)*. 2021;40:40.[[Link](#)]

Citation: Prasad V.N. Role of MRI in the Diagnosis and Characterization of Adnexal Masses in a Tertiary Hospital of Central Nepal. *JCMS Nepal*. 2025; 21(4): 321-327.