

Nepal's First Laser Bronchoscopy: A Case Report

Ranjan Sapkota¹, Bibhush Shrestha²

Author(s) affiliation

¹Department of Cardio-Thoracic Surgery, Maharajgunj Medical Campus, Manmohan Cardio-Thoracic Vascular and Transplant Centre, Institute of Medicine, Maharajgunj, Kathmandu, Nepal

²Department of Cardio-Thoracic and Vascular Anesthesiology, Manmohan Cardio-Thoracic Vascular and Transplant Centre, Institute of Medicine, Maharajgunj, Kathmandu, Nepal

Corresponding author

Ranjan Sapkota, MS, MCh
ranjansapkota@gmail.com

Submitted

May 5, 2021

Accepted

Jul 24, 2021

ABSTRACT

Light Amplification by Stimulated Emission of Radiation (Laser) is an essential tool for a thoracic surgeon in the management of tracheobronchial lesions: alone or on combination with other modalities of treatment. Post-tracheostomy tracheal stenosis (PTTS) is a well-known entity and often a challenging problem to manage. Here we report a successful use of endotracheal Laser, yet unreported in available English Literature from Nepal, in a 24 year man with PTTS after a protracted hospital stay for traumatic brain injury. The use of Laser bronchoscopy in such cases is safe and feasible, alone or in combination with tracheal dilatation.

Keywords

Bronchoscopy, dilatation, post-tracheostomy tracheal stenosis, laser

INTRODUCTION

Light Amplification by Stimulated Emission of Radiation (Laser) is in medical use since 1960. CO₂ Laser was the first Laser used in tracheobronchial tree. Subsequently, Neodymium-doped Yttrium-Aluminium-Garnet (Nd:YAG) Laser became the most popular ablation tool for airway lesions, owing to a) its shorter wavelength (1064 nm) which allowed its delivery via flexible quartz fibres compatible with a flexible bronchoscope and b) its ability to penetrate tissues, coagulate bleeders and cause instant vaporization of solid lesions.¹ Endobronchial Laser is a desirable tool for every thoracic surgeon dealing primarily with malignant, but also benign lesions of the central airways. In this report, we present a patient with benign tracheal stenosis, treated with Nd:YAG Laser along with tracheal dilatation. To the best of our knowledge, this is the first such report from Nepal, in available English literature.

CASE PRESENTATION

A 24 year young man sustained severe traumatic brain injury in a road-traffic accident, and underwent a number of sequential neurosurgical interventions. Due to prolonged postoperative mechanical ventilation, a surgical tracheostomy was also done early in the course of treatment. The tracheostomy tube stayed for a total of 3 months. After 2 weeks of its removal, he developed rapidly worsening stridor, and was admitted again.

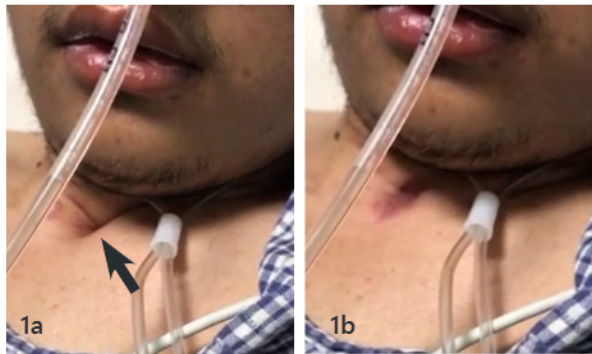


Figure 1a. Patient inspiring and Figure 1b. expiring. Note the marked indrawing (arrow) at the tracheostomy scar during inspiration

In the intensive care unit (ICU), the patient had a severe inspiratory stridor which worsened when the patient got agitated; however, oxygen saturation was maintained with minimal oxygen supplementation. He was vocalizing normally, and there were no other respiratory symptoms. The scarred tracheostomy site was seen markedly 'sucked in' during inspiration. (Fig 1) Subsequently, a computed tomogram of the neck/chest revealed a severely stenosed (4mm* 5mm- narrow, 1 cm-long), irregular trachea at the level of D1 vertebra, with otherwise normal proximal and distal airways. (Fig 2).

The patient's neurological recovery was not complete yet, and he needed significant assistance for activities of daily living. On this ground, the family opted for a tracheal dilatation as opposed to a surgical resection and anastomosis of trachea. Subsequently, his trachea was dilated initially with a CRE balloon under general anesthesia. The trachea was rendered adequate for a number 6 endotracheal tube for brief postoperative ventilation lasting few hours. On the 10th postoperative day, the patient developed stridor again, and had to be taken in for a re-dilatation of the stenosed trachea, this time with rigid bronchoscope, up to #7. The patient had an uneventful recovery. During both these procedures, the vocal cords, proximal trachea, distal trachea and both the bronchial trees were visualized to be normal, with a flexible bronchoscope. The centimetre-long stenosis began 6 cm distal to true vocal cords, and ended 5 cm proximal to carina.

Unfortunately, the patient developed stridor again after 3 weeks. The culprit was found to be a shelf-like narrowing, and hence a decision was taken to ablate it with Laser. A total of 0.8 KJ of Nd:YAG Laser was used in 22 pulses at a power setting of 15-20 W, in continuous mode, via a flexible bronchoscope inserted via a rigid one, with all anesthetic precautions. Care was taken to align the lasing fibre as parallel to the tracheal wall as possible. (Fig 3) The desiccated tissue was debrided

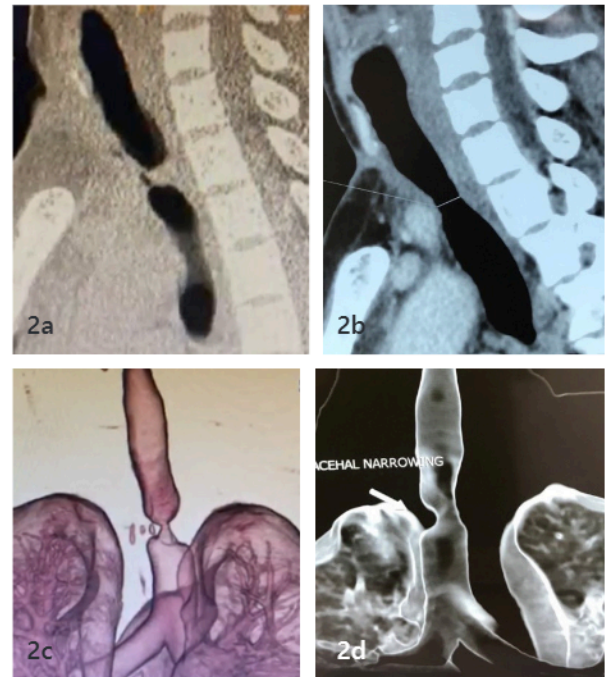

Figure 2. CT scans of the patient. 2a, 2c pre-Laser images with severely stenosed, irregular trachea at the level of D1 vertebra and 2b, 2d post-Laser with partly opened

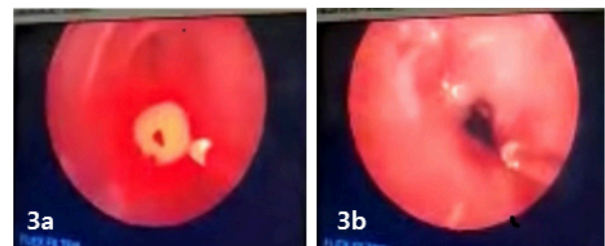


Figure 3. Intraoperative pictures of Laser bronchoscopy 3a. aiming beam highlighting the tracheal stenosis and 3b. partly opened up lesion at the beginning of lasing

using flexible and rigid forceps, and hemostasis was achieved with Laser itself. At the end of the procedure, a gentle rigid dilatation was done with a #7 bronchoscope. The procedure took 45 minutes, and there were no procedural complications.

The patient was extubated on table, and cared for in the ICU subsequently with supplemental oxygen, frequent nebulisations and injectable steroids for a day. He stayed for 5 more days for the treatment of intercurrent chest infection, and was discharged home without stridor. On follow up, he required one more rigid bronchoscopic dilatation after about a month.

Six months after Laser bronchoscopy, the patient is doing well. The patient is recuperating well from his traumatic brain injury: ambulatory, able to take care of himself and with no stridor, even on exertion.

DISCUSSION

Endotracheal intubation and tracheostomy are well-known risk factors for tracheal stenosis. The incidence has decreased after the advent of low pressure high volume cuffs, but nevertheless, the chance is real. Post-tracheostomy tracheal stenosis (PTTS) has been studied for at least 100 years.² It occurs in about 1-2% as a late complication of tracheostomy. Majority of the PTTS occur at the stoma site, and some occur distally at the level of cuff or tip.^{3,4} Several mechanisms are proposed to explain stomal PTTS: inadequate tracheal incision, fractured cartilage, tracheostomy wound infection, prolonged mechanical ventilation and exaggerated granulation around the stoma.⁵ Both open and percutaneous methods of tracheostomy have produced tracheal stenoses.^{5,6} It was recognized early that the stenosis at the tracheostomy site was often due to diaphragm-like granulation or membranous tissue as opposed to the hourglass-type deformity due to the cuff.⁷ The finding in our patient was pretty much in keeping with this description.

The stubborn and recurrent nature of these stenoses is a well-known phenomenon, and poses formidable challenge to the airway surgeon. The armamentarium for management of post-tracheostomy tracheal stenosis consists of mechanical rigid dilatation, balloon dilatation, LASER, airway stenting, T-tubes and surgery in form of resection and end-to-end anastomosis.^{3,8} On most occasions more than one of these techniques is used simultaneously or sequentially. Although surgery remains the most definite form of treatment, acute presentations sometimes prompt emergent use of less invasive endoscopic techniques.⁸ The management of our patient has been in line with these commonly accepted understandings.

The most common indication for Laser photoresection is malignant endoluminal growth obstructing the central airways. However, the use of Laser in non-malignant airway stenosis is extensively reported since as early as the 8th decade of the last century.⁹⁻¹¹ Laser delivery into the airway has been done in various ways, but the most commonly utilised method is to use a combination of rigid and flexible bronchoscopy under general anesthesia. It is customary to use a power setting of <40 watts and use pulsed delivery of Laser. In the absence of randomized controlled trials, experts' recommendations have been the guiding principles: Dumon's Ten Commandments and Mehta's Rules of Fours, for example.^{1,12} Similarly, a number of favourable and unfavourable factors affecting the outcome of a Laser bronchoscopy have been listed.¹ It is not unusual for the patients to require

repeated Laser treatments with or without other bronchoscopic procedures, some series reporting 34 treatments in a patient.^{10,13} Various Lasers have been successfully used in the airways; however, its excellent cutting and coagulation properties have made Nd:YAG the Laser of choice for airways as well as the lungs.^{1,8,12}

CONCLUSION

Endotracheal Nd:YAG Laser can be safely used for benign tracheal stenosis, in conjunction with tracheal dilatation.

CONSENT

Written informed consent was obtained from the patient for publication of this case report and the accompanying images.

CONFLICT OF INTEREST

None declared.

REFERENCES

1. Khemasuwan D, Mehta AC, Wang KP. Past, present and future of endobronchial photoresection. *J Thorac Dis* 2015;7(54):S380-88.
2. Goldberg M, Pearson FG. Pathogenesis of tracheal stenosis following tracheostomy with a cuffed tube. *Thorax* 1972;27:678.
3. Shin B, Kim K, Jeong BH, Eom JS, Song WJ, Kim H. Clinical implications of differentiating between types of post-tracheostomy tracheal stenosis. *J Thorac Dis* 2017;9(11):4413-23.
4. Sarper A, Ayten A, Eser I, Ozbudak O, Demircan A. Tracheal stenosis after tracheostomy or intubation. *Tex Heart Inst J* 2005;32:154-8.
5. Zias N, Chroniou A, Tappa MK, Gonzalez AV, Gray AW, Lamb CR, et al. *BMC Pulm Med* 2008;8:18.
6. Maden B, Datta S, McNulty G. Tracheal granulation tissue after percutaneous tracheostomy treated with Nd:YAG laser. *J Laryngol Otol* 2001;115(9):743-4.
7. Lefemine AA, MacDonnel K, Moon HS. Tracheal stenosis following cuffed tube tracheostomy. *Ann Thorac Surg* 1973;15(5):456-62.
8. Vandemoortele T, Laroumagne S, Bylicki O, Astoul P, Dutau H. Endobronchial treatment of complete tracheal stenosis: report of three cases and description of an innovative technique. *Ann Thorac Surg* 2013;95:351-4.
9. Dalar L, Ozdemir C, Sokucu SN, Urer HN, Altin S. Bronchoscopic treatment of benign endoluminal lung tumors. *Can Resp J* 2019; Article ID 5269728, 7 pages. <https://doi.org/10.1155/2019/5269728>
10. Verret DJ, Jategaonkar A, Helman S, Kadakia S, Bahrami A, Gordin E, et al. Holmium laser for endoscopic treatment of benign tracheal stenosis. *Int Arch Otorhinolaryngol* 2018;22:203-7.
11. Gelb AF, Epstein JD. Nd:YAG laser treatment of tracheal stenosis. *West J Med* 1984;141:472-5.
12. Sharpe DAC, Dixon K, Moghissi K. Endoscopic laser treatment for tracheal obstruction. *Eur J Cardiothorac Surg* 1996;10:722-6.
13. Leventhal DD, Krebs E, Rosen MR. Flexible laser bronchoscopy for subglottic stenosis in the awake patient. *Arch Otolaryngol Head Neck Surg* 2009;135(5):467-71.