

Morphology and Morphometry of Thyroid Gland in Cadavers: A Descriptive Cross-Sectional Study

Navindra Phuyal, Anusuya Shrestha, Rosha Bhandari, Bidur Adhikari, Jyoti Gautam, Deepesh Dhungel, Subina Gautam, Nirju Ranjit

Author(s) affiliation

Department of Anatomy,
Maharajgunj Medical Campus,
Tribhuvan University Teaching
Hospital, Institute of Medicine,
Kathmandu, Nepal

Corresponding author

Bidur Adhikari, MBBS, MS
biduradhikari@gmail.com

DOI

[10.59779/jiomnepal.1297](https://doi.org/10.59779/jiomnepal.1297)

Submitted

May 15, 2024

Accepted

Jul 26, 2024

ABSTRACT

Introduction

Variations in anatomy of thyroid gland include the occasional presence of a pyramidal lobe and a fibromuscular band called levator glandulae thyroideae. These variations affect the gland's morphometry and morphology. This study aimed to study morphometry and variation prevalence of thyroid gland.

Methods

This descriptive study examined adult cadavers from the Department of Forensic Medicine at Maharajgunj Medical Campus. Measurements of the length, breadth, and thickness of both lateral lobes and the isthmus were taken. The presence or absence of the isthmus, pyramidal lobe, and levator glandulae thyroideae was recorded, along with the origin and dimensions of the pyramidal lobe, if present.

Results

The mean dimensions of the right lobe were 43.88±6.88 mm (length), 23.93±4.76 mm (breadth), and 12.28±3.30 mm (thickness). For the left lobe, the measures were 40.47±7.26 mm, 21.95±4.22 mm, and 12.84±3.61 mm, respectively. The isthmus had mean dimensions of 18.12±5.52 mm, 16.65±5.51 mm, and 5.10±1.76 mm. The isthmus was absent in 7.2% of cases. The pyramidal lobe, present in 27.8% of cases, had mean dimensions of 19.17±8.26 mm, 11.64±3.47 mm, and 4.60±1.33 mm, typically originating from the center of the isthmus. The average weight of the thyroid gland was 16.19±5.22 g.

Conclusion

The thyroid gland's weight was higher in males and positively correlated with the individual's height. Also, thyroid gland's dimensions and weight were less than those described in standard texts. The relationship between body weight and thyroid gland weight warrants further investigation.

Keywords

Cadaveric study; morphometry; thyroid gland

INTRODUCTION

Thyroid gland is a ductless and highly vascular gland which is situated in front and at the sides of trachea at the level of fifth cervical to first thoracic vertebrae. It is brownish red in colour and is ensheathed by the pre tracheal layer of the deep cervical fascia.^{1,2} Anatomical variations of thyroid gland are well-documented, but there is considerable variability in their prevalence and morphometric characteristics across different populations. Existing literature highlights the significance of understanding these variations for clinical and surgical implications, particularly in thyroidectomy and related procedures.³⁻⁵

As variable presence of pyramidal lobe is very high in some populations, a thorough understanding of thyroid anatomical variations is crucial for surgical procedures, particularly thyroidectomy. Accurate knowledge of these variations can significantly impact surgical planning and outcomes, reducing the risk of complications.⁶⁻⁹ The presence of accessory thyroid tissue and its vascular supply could affect surgical approaches while performing thyroidectomy surgery.^{3,10}

Despite these studies, there remains a gap in the comprehensive understanding of thyroid gland variations, particularly in diverse populations. The current study aims to address this gap by providing detailed morphometric data and variation prevalence in the Nepali population. By doing so, it seeks to contribute to the existing body of knowledge and enhance clinical and surgical practices related to the thyroid gland. This study's findings will be valuable for anatomists, surgeons, and endocrinologists, improving the accuracy of diagnoses and the effectiveness of thyroid-related treatments.

METHODS

This cross-sectional observational study aimed to investigate the morphometry and anatomical variations of the thyroid gland in Nepalese cadavers. The study was conducted at the Department of Forensic Medicine, Maharajgunj Medical Campus.

The sample included cadavers brought to the mortuary of the department, using non-probability sampling. Cadavers were included if they were Nepalese nationals aged 18 years and above, excluding those with gross abnormalities in the neck or thyroid region, pregnant cadavers or those that were putrefied.

Consent was obtained from the relatives of the deceased. Standard routine autopsy procedures were followed using Letulle's method, with thyroid gland removal. This involved preliminary skin incisions, removal of the thyroid gland en bloc, and dissection to expose the gland.¹¹ The presence of the isthmus, pyramidal lobe, and levator glandulae

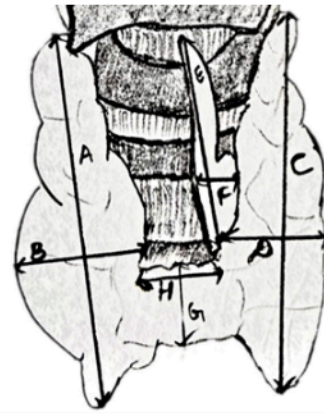


Figure 1. Diagram showing the points of measurements.¹⁰ A: length of right lobe, B: breadth of right lobe, C: length of left lobe, D: breadth of left lobe, E: length of pyramidal lobe, F: breadth of pyramidal lobe, G: length of isthmus, H: breadth of isthmus.

thyroideae was noted.

Measurements of the thyroid gland were taken using a digital Vernier calliper and a digital weighing machine. Length, breadth, and thickness of the right and left lobes, isthmus, and pyramidal lobe (if present) were measured. The weight of the thyroid gland was also recorded. The length of the cadaver was measured using a measuring tape. The gland was cleaned and prepared for measurement after removal, ensuring accuracy and consistency. Measurements were taken as outlined in Figure 1.

Data was recorded in a pro forma and entered into an Excel spreadsheet daily. Incomplete data samples were omitted. Descriptive statistics, including mean, median, and standard deviation, were calculated. Chi squared, Spearman's Rho test, and Mann Whitney U t-test were used to find associations or differences between variables as per the normality of data. Statistical analysis was performed using SPSS version 18, with a confidence level of 95% and a significance level of 0.05.

RESULTS

In this study total 97 cadavers were included among which 67 were male and 30 were female. They belonged to the age group 18 to 80 years with the mean age of 38.49 (SD = 15.06). The different measurements of thyroid gland are summarized in Table 1.

Out of total cadavers, pyramidal lobe was present in 27. Its origin was at the center of isthmus in 13, towards left lobe in 9 and towards right lobe in 5 (Figure 2). Out of total 97 cadavers, isthmus was absent in seven (Figure 3).

The mean weight of thyroid gland in female was found to be 13.34 g (SD= 4.51) while that of male

Table 1. Measurements of thyroid gland

Charateristics	Number	Mean	Minimum	Maximum
Right lobe dimensions (mm)				
Length	97	43.88±6.88	30.64	63.49
Breadth		23.93±4.76	14.58	34.18
Thickness		12.28±3.30	7.16	22.87
Left lobe dimensions (mm)				
Length	97	40.47±7.26	27.12	63.74
Breadth		21.95±4.22	13.11	34.36
Thickness		12.84±3.61	5.42	24.12
Isthmus dimensions (mm)				
Length	90	18.12±5.52	4.23	34.68
Breadth		16.65±5.51	6.74	29.28
Thickness		5.10±1.76	1.07	10.35
Pyramidal lobe dimensions (mm)				
Length	27	19.17±8.26	10.39	39.70
Breadth		11.64±3.47	5.20	22.16
Thickness		4.60±1.33	1.73	7.52
Weight (kg)	97	16.18±5.22	8.60	29

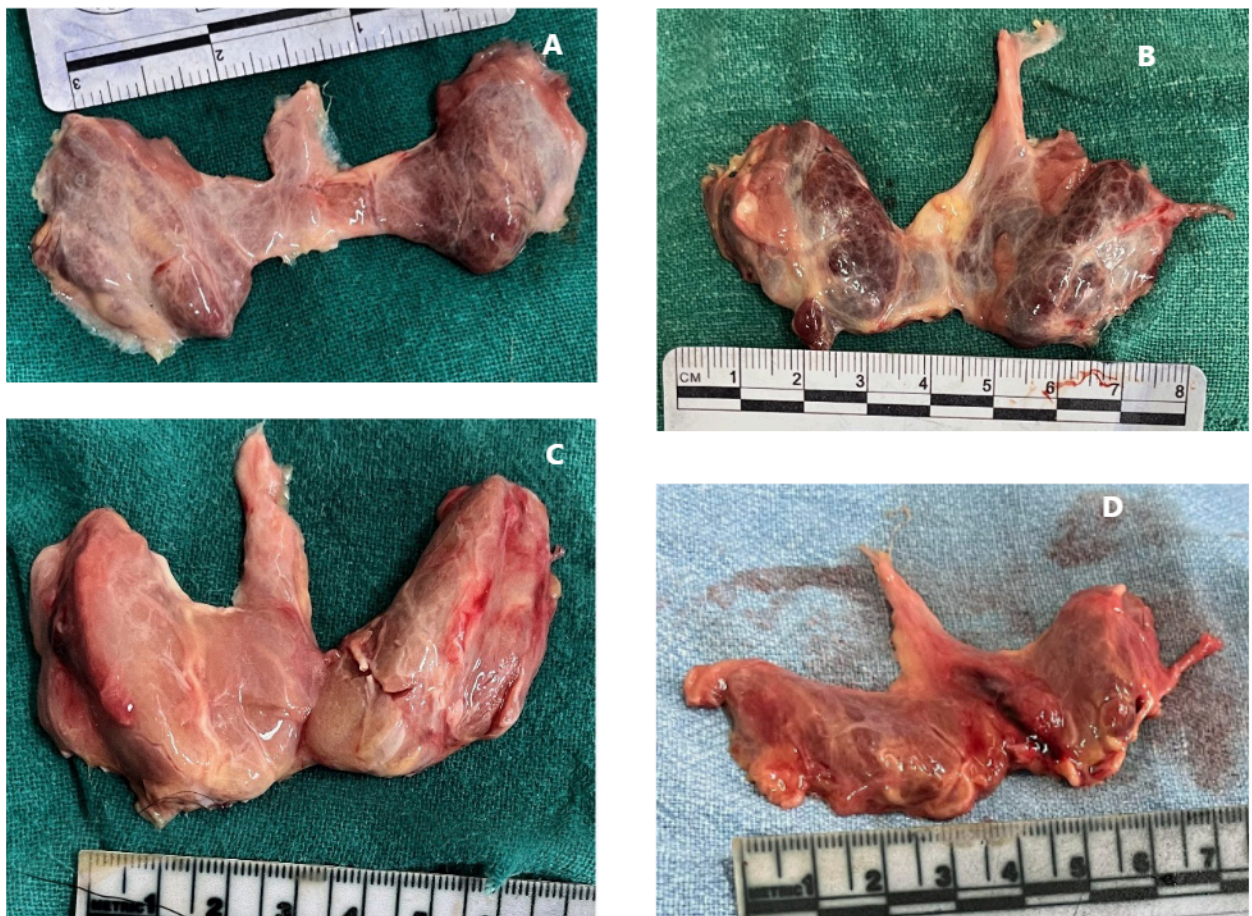

Figure 2. Different origins of pyramidal lobe (A: central, B: towards right lobe, C: towards left lobe), presence of levator glandulae thyroideae (D).

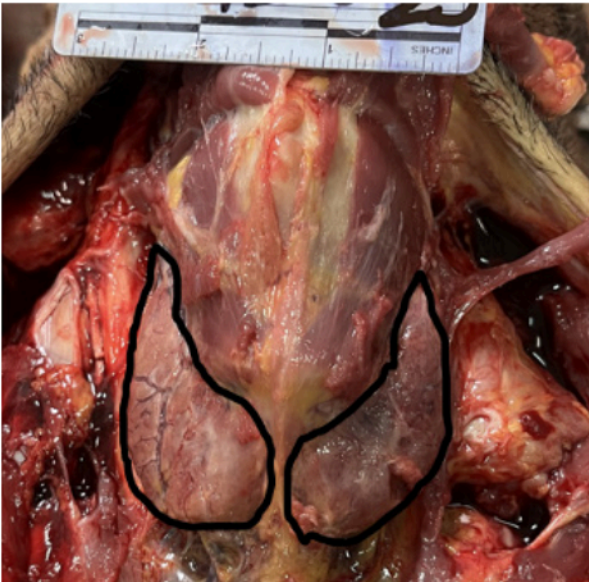

Figure 3. Absence of isthmus.

was found to be 17.46 g (SD= 5.04). The difference was found to be statistically significant on Mann Whitney U test (p -value<0.001).

Mean weight of thyroid gland was not significantly related to age of the cadaver on correlation of age with thyroid weight. However, weight of thyroid gland showed significant positive correlation with length of the cadaver (Spearman's correlation coefficient = 0.452, p -value <0.001).

Levator glandulae thyroideae was present in 25 cases (Figure 2), out of which 22 were male and 3 were female. Its presence was found to be significantly associated with gender (Chi-squared test, p -value =0.02)

DISCUSSION

The current study found the mean weight of thyroid gland to be 16.2 g (SD=5.22), mean right lobe length 43.9 mm (SD=6.9), mean right lobe breadth 23.9 mm (SD=4.77), mean right lobe thickness 12.28 mm (SD=3.31), mean left lobe length 40.48 mm (SD = 7.27), mean left lobe breadth 21.96 mm (SD=4.22), mean left lobe thickness 12.84 (SD=3.61). Pyramidal lobe was present in 27.8% cadavers while levator glandulae thyroideae was present in 25.7%.

In comparison to standard textbooks, which report lateral lobe dimensions of 5 cm in length, 3 cm in breadth, and 2 cm in thickness,^{1,2} our study found slightly smaller dimensions. This aligns more closely with findings from Dessie et al.¹², Prakash et al.¹³, Sravani et al.¹⁴, and Joshi et al.¹⁵, who also reported smaller measurements compared to

textbooks. Notably, Ozgur et al.¹⁰ and Tanriover et al.¹⁶ reported larger dimensions than our findings. Racial and geographical variations between human populations could be a factor in this difference.

The slight larger size of the right lobe compared to the left, as observed in this study, concurs with explanations by Joshi et al.¹⁵ and Rajkonwar et al.⁴ Differences in thyroid dimensions between populations may be attributed to variations in height and body build, with European populations generally being taller than Asian populations, as noted by Markey.¹⁷ Geographical variations may also affect thyroid morphometry.

For breadth and thickness, the measurements from current study were consistent with previous research but generally less than the values reported in standard textbooks. Dessie et al.¹² and Tanriover et al.¹⁶ reported slightly different measurements, possibly due to differences in the preservation of samples or population characteristics.

Regarding the isthmus, the measurements from our study align with those reported by Joshi et al.¹⁵, Sravani et al.¹⁴, and Raut et al.¹⁸, although our thickness measurement was slightly higher than Raut et al.'s findings¹⁸. Similarly, the dimensions of the pyramidal lobe in our study are consistent with previous studies by Milojevic et al.⁷, Gurleyik et al.⁸, and Srikant et al.¹⁹.

The site of origin of the pyramidal lobe aligns with Sravani et al.¹⁴ and differs from Dessie et al.¹², Tanriover et al.¹⁶, and other studies, which often found the left side of the isthmus to be the most common origin site. The smaller sample size in the current study could have resulted in detection of fewer rare variations like this. The occurrence of pyramidal lobe in 27.8% cases and its dimensions warrants vigilance from operating surgeons and diagnosing clinicians in order to avoid complications or misdiagnoses.

Thyroid gland injury is a common complication of tracheostomy, potentially leading to hemorrhage from thyroid vessel or gland injury. The anatomical variations of the thyroid gland, including isthmus resection or blunt dissection, are crucial for safe tracheostomy procedures.²⁰ Knowledge of these variations helps avoid complications, but this study did not include the extent of the isthmus against the tracheal rings due to time constraints. Future studies could address this.

Standard textbooks typically describe the thyroid gland weight as 25 grams^{1,2}. In this study, the mean thyroid gland weight was found to be significantly lower, with males averaging slightly more than females. This finding is consistent with Pankow et al.²¹, who reported similar weights for different age groups, but lower than the weights reported by Tanriover et al.¹⁶ The study found a statistically

significant difference in thyroid gland weight between males and females, but no significant correlation between age and gland weight. A positive correlation was found between individual height and thyroid weight, aligning with Sahin et al.²², who reported strong positive correlations between thyroid volume and height in males and weaker, but significant, correlations in females.

This was a cadaveric study done on recently deceased, non-formalin-fixed cadavers at the Forensic Department. The study was done using standard procedures and data was collected by the principal investigator only to avoid bias. All measurements were taken twice and averaged before entry to proforma. However, this study was limited due to the short data collection period and smaller sample size. Due to the lack of facilities for weighing cadavers, individual weight correlations also could not be established. Nevertheless, the current study forms a strong baseline data among adult Nepalese population about the morphometry of thyroid gland.

The study provides a baseline data from the Nepalese population which could have implications in thyroid surgeries and procedures like tracheostomy. For higher generalizability, it is recommended to increase the sample size in future studies. Including a larger number of women would enable a more detailed comparison of thyroid weight across different age groups. Investigating the effects of thyroid disorders on gland weight, using patient history or studies on live subjects, could provide further insights. Additionally, analyzing samples from different geographical regions would help identify regional variations in thyroid anatomy. Separate studies should be conducted to explore the extent of the isthmus, variations in thyroid gland relations, and blood supply differences. The position of the parathyroid glands also warrants further investigation. Lastly, allocating sufficient time for data collection and observation is crucial to avoid bias and ensure comprehensive results.

CONCLUSION

The thyroid glands showed common anatomical variations like absent isthmus and centrally originating pyramidal lobes. The thyroid glands were found to be smaller in size and weight than standard textbook descriptions. Thyroid weight had a positive correlation with height and was higher in males than females. These findings are valuable for surgeons, radiologists, and forensic experts, particularly in understanding regional anatomical differences and performing emergency procedures.

FINANCIAL SUPPORT

The author(s) did not receive any financial support for the research and/or publication of this article.

CONFLICT OF INTEREST

The author(s) declare that they do not have any conflicts of interest with respect to the research, authorship, and/or publication of this article.

AUTHOR CONTRIBUTIONS

Concept of research & Design of research: NP, AS, RB, BA, JG, DD, SG, NR; Literature search: NP, BA, RB; Data collection: NP; Data analysis: NP, BA, SG; Data Interpretation: NP, BA, AS, NR, JG; Drafting and Reviewing of the manuscript for important intellectual content: NP, AS, RB, BA, JG, DD, SG, NR; Final approval of the version ready for submission: NP, AS, RB, BA, JG, DD, SG, NR; Agreement to be accountable for all aspects of the work: NP, AS, RB, BA, JG, DD, SG, NR

REFERENCES

1. Standring S. Gray's anatomy: the anatomical basis of clinical practice. 41st ed. Elsevier; 470–474 p.
2. Datta AK. Principles of general anatomy. K P Basu Publishing Company; 2004. 160–166 p.
3. Ranade AV, Rai R, Pai MM, et al. Anatomical variations of the thyroid gland: possible surgical implications. Singapore Med J. 2008;49(10):831.
4. Rajkonwar AJ, Kusre G. Morphological variations of the thyroid gland among the people of upper Assam region of northeast India: a cadaveric study. J Clin Diagn Res. 2016;10(12):AC01. <https://doi.org/10.7860/JCDR/2016/19395.8966>
5. Dave MR, Rajguru J, Gupta D. A study of the variations in the morphology of the thyroid gland and its surgical correlations. Int J Anat Res. 2019;7(1.3):6269–73. <https://doi.org/10.16965/ijar.2018.455>
6. Sinos G, Sakorafas GH. Pyramidal lobe of the thyroid: anatomical considerations of importance in thyroid cancer surgery. Oncol Res Treat. 2015;38(6):309–10. <https://doi.org/10.1159/000430894>
7. Milojevic B, Tosevski J, Milisavljevic M, et al. Pyramidal lobe of the human thyroid gland: an anatomical study with clinical implications. Rom J Morphol Embryol. 2013;54(2):285–9.
8. Gurleyik E, Gurleyik G, Dogan S, et al. Pyramidal Lobe of the Thyroid Gland: Surgical Anatomy in Patients Undergoing Total Thyroidectomy. Anat Res Int. 2015 Jul 7;2015:1–5. <https://doi.org/10.1155/2015/384148>
9. Zivic R, Radovanovic D, Vekic B, et al. Surgical anatomy of the pyramidal lobe and its significance in thyroid surgery. S Afr J Surg. 2011;49(3):110–6.
10. Ozgur Z, Celik S, Govsa F, et al. Anatomical and surgical aspects of the lobes of the thyroid glands. Eur Arch Otorhinolaryngol. 2011 Sep;268(9):1357–63. <https://doi.org/10.1007/s00405-011-1502-5>
11. Sheaff MT, Hopster DJ. Block dissection. In: Sheaff MT, Hopster DJ, editors. Post Mortem Technique Handbook. London: Springer; 2001. <https://doi.org/10.1007/978-1-4471-3677-4>
12. Dessie MA. Anatomical variations and developmental anomalies of the thyroid gland in Ethiopian population: a

- cadaveric study. *Anat Cell Biol.* 2018;51(4):243. <https://doi.org/10.5115/acb.2018.51.4.243>
13. Prakash, Rajini T, Ramachandran A, et al. Variations in the anatomy of the thyroid gland: clinical implications of a cadaver study. *Anat Sci Int.* 2012 Mar;87(1):45–9. <https://doi.org/10.1007/s12565-011-0115-9>
 14. Sravani T, Sofia P, Devi CL. Anomalous development of thyroid gland: A cadaveric study in coastal population of Andhra Pradesh. *Indian J Clin Anat Physiol.* 2019;6(2):220–3. <https://doi.org/10.18231/j.ijcap.2019.049>
 15. Joshi SD, Joshi SS, Daimi SR, et al. The thyroid gland and its variations: a cadaveric study. *Folia Morphol.* 2010;69(1):47–50.
 16. Tanriover O, Çomunoglu N, Eren B, et al. Morphometric features of the thyroid gland: a cadaveric study of Turkish people. *Folia Morphol.* 2011;70(2):103–8.
 17. Markey O, Collaboration NRF. A century of trends in adult human height. *Elife* [Internet]. 2016 [cited 2024 Jun 17];5(e13410). Available from: <https://centaur.reading.ac.uk/66465/> <https://doi.org/10.7554/eLife.13410>
 18. Raut RS. Morphometric Study of Isthmus of Thyroid Gland and Its Embryological and Clinical Corelation. *Sch Int J Anat Physiol.* 2019 Jan;2(1):13–8.
 19. Srikanth V, Umarji J, Thomas A. A Morphological Variation in Thyroid Gland- A Case Report. *Int J Health Sci.* 2018;(9).
 20. Cipriano A, Mao ML, Hon HH, et al. An overview of complications associated with open and percutaneous tracheostomy procedures. *Int J Crit Illn Inj Sci.* 2015;5(3):179–88. <https://doi.org/10.4103/2229-5151.164994>
 21. Pankow BG, Michalak J, McGee MK. Adult human thyroid weight. *Health Phys.* 1985;49(6):1097–104. <https://doi.org/10.1097/00004032-198512000-00005>
 22. Şahin E, Elboğa U, Kalender E. Regional reference values of thyroid gland volume in Turkish Adults. *Srp Arh Celok Lek.* 2015;143(3–4):141–5. <https://doi.org/10.2298/SARH1504141S>