

## Diagnostic and Therapeutic Value of ERCP : Experience from a Tertiary Care Center

Rahul Pathak, Manoj Lamsal, Anurag Jha, Brindeswari Kafle, Rabin Hamal

### Author(s) affiliation

Department of Gastroenterology,  
Maharajgunj Medical Campus,  
Tribhuvan University Teaching  
Hospital, Institute of Medicine,  
Maharajgunj, Kathmandu, Nepal

### Corresponding author

**Manoj Lamsal, MBBS, MD**  
manojlamsal@gmail.com

### DOI

[10.59779/jiomnepal.1322](https://doi.org/10.59779/jiomnepal.1322)

### Submitted

Apr 20, 2024

### Accepted

Jul 5, 2024

## ABSTRACT

### Introduction

The role of ERCP to diagnose and manage biliopancreatic diseases is increasing since its inception with refinement of operator skill, technical advancement and better patient selection. The aim of the study was to explore common clinical and endoscopic characteristics, outcome, adverse events and safety profile of patients.

### Methods

An observational study was conducted on patients undergoing ERCP in Department of Gastroenterology, Tribhuvan University Teaching Hospital, for management of biliopancreatic diseases from April 2023 to March 2024 after taking approval from IRC-IOM. Patient demographics, clinical characteristics, ERCP findings and post procedure outcome data were collected and analyzed using SPSS version 26.

### Results

A total of 200 patients were included with mean age  $52.36 \pm 17.04$  years and female:male ratio of ~3:2. Elective procedures were done in 182 (91%) patients and in 18 (9%) as urgent procedure (within 48 hours). The most common indications were choledocholithiasis (157, 78.5%) followed by benign biliary stricture (12, 6%). The most frequent papilla was type 1 papilla (normal variant) in 48% followed by type 3 papilla (protruding) in 30%. Difficult cannulation was encountered in 130 (51.5%) cases. Post ERCP pancreatitis (8, 4%) and hypoxia (9, 4.5%) were the most common procedure and anesthesia related adverse events respectively. Common therapeutic interventions included sphincterotomy (176, 88%), CBD stenting (154, 78.5%) and precut sphincterotomy (45, 22.5%).

### Conclusion

ERCP was mostly done for benign diseases like CBD stone and benign biliary strictures. Common therapeutic procedures were sphincterotomy and CBD stenting. Complications related to procedure and anesthesia though occurred, their rate was low.

### Keywords

Choledocholithiasis; ERCP; pancreatitis

INTRODUCTION

Endoscopic retrograde cholangio-pancreatography (ERCP) represents advanced endoscopic technique for the management of biliopancreatic disease.<sup>1</sup> Initially developed as a diagnostic procedure, ERCP has evolved over the years to a predominantly therapeutic tool.<sup>2, 3</sup> Side-viewing duodenoscope allows perfect visualization of ampulla as well as gives access to accessories for various therapeutic interventions. Albeit a complex and technically demanding procedure, ERCP has become the standard of care for patients presenting with bile duct pathology, including stones, strictures, bile leaks and biliary malignancy.<sup>4, 5</sup> Being invasive procedure, it is associated with various minor and major complications that varies between 4% - 30%.<sup>6, 7</sup> Better patient selection, anesthesia and advanced technique makes it a safer and effective procedure.<sup>8</sup>

The history of ERCP procedure dates back to early 2011 from very limited centers.<sup>9, 10</sup> Over the years, it has expanded to multiple centers inside and outside of capital city for numerous biliopancreatic indications. Major surgical indications of biliopancreatic diseases has shifted to ERCP with resultant less morbidity and better outcomes. Advancement in ERCP expertise over the years has saved cost, time and productivity of economically active patients. Aim of the study is to analyze various diagnostic and therapeutic spectrum of patients undergoing ERCP for biliopancreatic disorders at our center.

METHODS

A retrospective study was conducted using data from patients who underwent ERCP in Department of Gastroenterology from April 2023 to March 2024 at Tribhuvan University Teaching Hospital, Kathmandu. The study enrolled 200 patients (aged 12 years and older) undergoing ERCP as per convenient sampling. ERCP documentation files of all the patients during the study period were retrieved and analyzed. All patients received standard of care along with management of inadvertent complications. Written informed consent were taken prior to procedure regarding the procedure, complications and possible outcomes. All patients received conscious sedation during the procedure. Bile duct was accessed using sphincterotome and guide wire. Successful biliary cannulation time more than 5 minutes were defined as difficult cannulation and macroscopic appearance of papilla were observed to record its various types. Depending upon indications, patients received sphincterotomy, balloon trawling, biliary brush cytology and biliary stent placement.

Data were analyzed using SPSS version 26.0. Descriptive statistics for patients characteristics and analytic techniques were used as appropriate.

The study protocol was approved by Institutional Review Committee (IRC) of the tertiary care hospital, ensuring compliance with ethical guidelines and protection of patient confidentiality and rights (approval no 469 (6-11) E2).

RESULTS

Total of 200 patients were included in the study. The mean age was 52.36 ± 17.04 years and 59% of the patients were female (table 1). Among the total patients undergoing the procedure, 46.5% patients were having comorbid medical conditions which could increase the procedural and anesthesia related risk during ERCP. Albeit most procedure were done in an elective basis, 9% of patients underwent emergency ERCP (within 48 hours of presentation). All of the urgent ERCP were done

Table 1. Baseline clinical characteristics of patients undergoing ERCP

Characteristics	Number (%)
Age in years (Mean±SD)	52.36±17.04
Gender (Female: Male)%	118:82 (59%:41%)
Comorbidities N=93 (%)	
HTN	24
T2DM	11
IHD/CAD	7
COPD	8
T2DM and HTN	9
Liver Disease	11
Hypothyroidism	13
Stroke	2
Hemolytic anemia	4
Malignancy	3
HIV	1
Urgency of ERCP N (%) :	
Elective	182 (91%)
Emergency	18 (9%)
Presenting symptoms N (%)	
Biliary colic	167 (83.5%)
Obstructive jaundice	68 (34%)
Fever	28 (14%)
Cholangitis	27 (13.5)
Pancreatitis	23 (11.5%)
Post cholecystectomy status	35 (17.5%)
Liver Function Test N (%)	
Normal	25 (12.5)
Obstructive Pattern	128 (64)
Hepatocellular Pattern	47 (23.5)
Cholelithiasis (N=165)	
Yes	130 (78.8%)
No	35 (21.2%)

**Table 2.** Endoscopic characteristics of patients undergoing ERCP

Characteristics	Number (%)
Papilla type	
Type 1	96 (48%)
Type 2	24 (12%)
Type 3	60 (30%)
Type 4	20 (10%)
Cannulation time (N=187)	
<5 mins	103 (51.5%)
>5 mins	84 (42%)
Precut sphincterotomy (NKP done)	45 (22.5%)
ERCP related adverse events	
Bleeding	3 (1.5%)
Perforation	1 (0.5%)
Pancreatitis	8 (4%)
Cholangitis	5 (2.5%)
Anesthesia related adverse events	
Hypoxia during procedure	9 (4.5%)
Arrhythmia during procedure	3 (1.5%)
Shock during procedure	3 (1.5%)

for patients with cholangitis with hemodynamic compromise. The baseline clinical characteristics of the patients were as depicted in Table 1.

During the procedure, endoscopic characteristics and periprocedural events were analyzed (Table 2). Most common type of papilla was type 1 (48%) followed by type 3 (30%), type 2 (12%) and type 4 (10%). Depending upon the papilla type, cannulation difficulties were encountered. Difficult cannulation requiring more than 5 minutes for successful cannulation was encountered in 42% and cannulation was unsuccessful in 13 patients (6.5%) even with precut sphincterotomy. Precut sphincterotomy in the form of needle

**Table 3.** Primary diagnosis of patients who underwent ERCP

Primary diagnosis	Number (%)
Choledocholithiasis	157 (78.5%)
Benign biliary stricture	12 (6%)
Cholangiocarcinoma	7 (3.5%)
Malignant stricture from distant metastasis	3 (1.5%)
Choledochal cyst	4 (2%)
Ca pancreas	2 (1%)
Bile leak	3 (1.5%)
Carcinoma gall bladder	1 (0.5%)
Ampullary ca	2 (1%)
Hydatid cyst	3 (1.5%)
Mirizzi syndrome	6 (3%)

**Table 4.** Therapeutic procedure performed during ERCP

ERCP Procedure	Number (%)
EST, Stone extraction with balloon/basket	176 (88%)
CBD stenting	
Plastic	154 (77%)
SEMS	3 (1.5%)
Precut sphincterotomy	45 (22.5%)
Biliary stone that could not be extracted endoscopically (referred for surgery)	42 (21%)

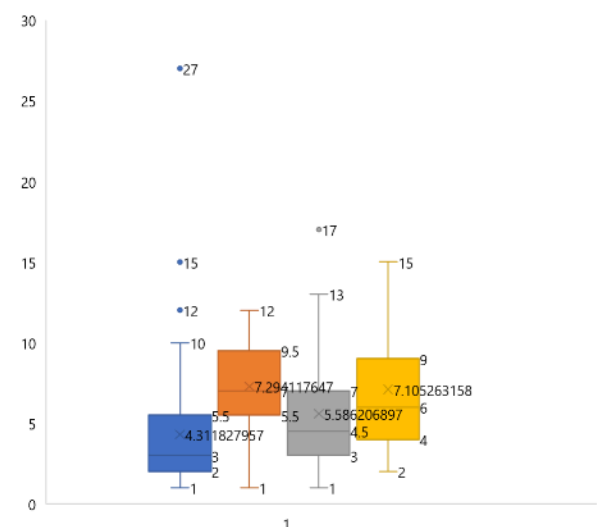
EST: Endoscopic sphincterotomy; SEMS: self-expandable metallic stent

knife papillotomy (NKP) was required in 22.5% for successful cannulation. Among the various complications of ERCP, most common ERCP related adverse events was pancreatitis in 4.5% patients. Similarly, hypoxia was the most common anesthesia related adverse events during the procedure.

Various procedural difficulties were encountered during the procedure. Among them, the most common difficulties encountered was periampullary diverticulum (16.5%), failed stone extraction (10%), failed cannulation (6.5%) and abnormal duodenal/papillary anatomy (5%).

Most of the patients who underwent the procedure had benign diseases. The most common indication of ERCP was choledocholithiasis in benign etiology whereas cholangiocarcinoma was the most common malignant etiology (Table 3).

Therapeutic procedures were performed for various indications. Among them, CBD stone extraction

**Figure 1.** Average cannulation time depending on various types of papilla



with balloon or basket was done in 88% patients, CBD stenting with plastic stent in 77% patients, self-expandable metallic stent (SEMS) in 1.5% and precut sphincterotomy done in 22.5% patients (Table 4).

Depending upon the papilla types, successful cannulation attempt was variable (Figure 1). Most difficult papilla for successful cannulation was type 2 (Micropapillary variant) requiring mean time 7.29 minutes followed by type 4 (longitudinal/creased variant). Type 1 papilla (normal variant) was most easy to cannulate with mean time to cannulate 4.31 minutes.

## DISCUSSION

The role of ERCP for biliopancreatic disease is increasing worldwide and our country too is not an exception to it. The expanding expertise and advancement in ERCP technique has replaced various surgical indications to ERCP, reducing the surgical intervention related risk. The centers practicing ERCP has expanded outside Kathmandu valley over the years and more number of complicated cases are being attempted at referral centers like ours. Our study reflects various diagnostic and therapeutic spectrum of patients undergoing ERCP procedure for various biliopancreatic disease.

Most common indications for ERCP were benign conditions like choledocholithiasis, finding similar to other studies around the globe.<sup>9</sup> Since most patients underwent ERCP for CBD stones, females were commonly affected. Though most patients had cholelithiasis (78.8%) along with choledocholithiasis, 21.2 % patients had no gall stones reflecting those most likely to be primary CBD stones. This finding suggests that secondary CBD stones that have migrated from gall bladder are more commoner than primary CBD stones that forms due to various underlying medical conditions.<sup>11</sup> Most patients who underwent ERCP were elderly with mean age of 52.36 years reflecting that biliopancreatic diseases increases with increase in age. Increase in age is also associated with various comorbid condition that might increase benign condition like CBD stones, CBD stricture and malignant conditions like cholangiocarcinoma, malignant CBD stricture or pancreatic neoplasm. Our study analysis showed that ERCP indications were more for benign conditions compared to malignant condition, findings similar to study done by Meseeha et al.<sup>12</sup> Malignant conditions requiring ERCP were done mostly for therapeutic palliative procedure like biliary drainage, mostly underwent plastic stenting. Although majority of cases taken for ERCP for certain indications could be successfully accomplished, certain procedural difficulties are inevitable in every centers, most often in referral centers like ours. Our study showed that, most common procedural difficulty

encountered was periampullary diverticulum (16.5%) which could lead to difficult cannulation and sometimes failed cannulation. Similarly failed cannulation was reported in 6.5% cases and failed stone extraction in 10% cases and such cases were referred for surgical management. Our study showed that 21% patients were referred for surgical intervention in view of unsuccessful ERCP procedure due to various procedural difficulties like failed cannulation, CBD stricture, stone proximal to stricture.<sup>13</sup> Our study also analyzed various types of papilla comparing and found that type 1 papilla were the most common type. This agrees with reports in literature, in which type 1 papilla was found in 32-56% of participants.<sup>14-16</sup> Our study also compared papillary types with difficult cannulation. Finding showed that type 2 papilla was most difficult to cannulate with average time of cannulation 7.29 minutes. Study done by Haraldsson et al also reported that the odds of difficult biliary cannulation were highest in patients with type 2 papilla.<sup>14</sup> Though ERCP is a relatively safe procedure, certain complications are inherent as reported from various studies inside and outside the country. Our study showed that ERCP procedure related adverse were observed in 8.5% cases which is a little higher than that observed in systematic survey of 21 prospective studies between 1977 to 2006 involving 16,885 subjects reporting an overall post-ERCP complication rate of 6.85%.<sup>17</sup> This discrepancy could be explained based on that fact that most of the cases are complicated cases which are being referred from outside centers. Similar to previous studies, most common complication noted was post ERCP pancreatitis, reported in 4.5% cases, however none of them were severe and resolved with conservative management.<sup>18</sup> Elmunzer BJ et al. also reported post ERCP pancreatitis to be the most common complication observed in 3-15% cases.<sup>19</sup> Severe complication in the form of perforation during ERCP was reported in single case, however it was non-fatal and resolved with conservative management. Apart from procedural complications, anesthesia related adverse events were observed in the form of hypoxia (4.5%), arrhythmia (1.5%) and hypotension (1.5%) which although events were less than those observed in other study.<sup>20</sup>

## CONCLUSION

Most patients underwent ERCP for benign diseases like CBD stone and benign biliary stricture. Therapeutic procedures commonly performed were sphincterotomy and CBD stenting. Complications related to procedure and anesthesia occurred, but their rate was low. The role of ERCP in various biliopancreatic diseases for diagnostic and therapeutic procedure are ever-increasing. Being an invasive procedure, complications occur. Hence, there should be backup of good surgical team.

## ACKNOWLEDGEMENT

This study was possible because of immense support and guidance from faculties of Department of Gastroenterology, residents of Internal Medicine, nursing staff and above all my patients without whom this study would not have been completed.

## FINANCIAL SUPPORT

The author(s) did not receive any financial support for the research and/or publication of this article.

## CONFLICT OF INTEREST

The author(s) declare that they do not have any conflicts of interest with respect to the research, authorship, and/or publication of this article.

## AUTHOR CONTRIBUTIONS

Study concept and design: RP, AJ, BK; Data collection: RP, ML, RH; Analysis and interpretation: RP, ML, AJ, BK; Manuscript draft: RP, ML, RH. All author read approved the final manuscript.

## REFERENCES

- Mathisen GE, Johnson JP. Brain abscess. Clin Infect Dis Off Publ Infect Dis Soc Am. 1997 Oct;25(4):763–79; quiz 780–1. <https://doi.org/10.1086/515541>.
- Salerno R, Mezzina N, Ardizzone S. Endoscopic retrograde cholangiopancreatography, lights and shadows: Handle with care. World Journal of Gastrointestinal Endoscopy. 2019;11(3):219. <https://doi.org/10.4253/wjge.v11.i3.219>
- Chathadi KV, Chandrasekhara V, Acosta RD, et al. The role of ERCP in benign diseases of the biliary tract. Gastrointestinal endoscopy. 2015;81(4):795–803. <https://doi.org/10.1016/j.gie.2014.11.019>
- Sanders DJ, Bomman S, Krishnamoorthi R, et al. Endoscopic retrograde cholangiopancreatography: Current practice and future research. World Journal of Gastrointestinal Endoscopy. 2021;13(8):260. <https://doi.org/10.4253/wjge.v13.i8.260>
- Costamagna G, Familiari P, Marchese M, et al. Endoscopic biliopancreatic investigations and therapy. Best Practice & Research Clinical Gastroenterology. 2008;22(5):865–81. <https://doi.org/10.1016/j.bpg.2008.05.004>
- Kozarek RA. The past, present, and future of endoscopic retrograde cholangiopancreatography. Gastroenterology & hepatology. 2017;13(10):620. PMID: 29230140 PMCID: PMC5718180
- Freeman ML, Nelson DB, Sherman S, et al. Complications of endoscopic biliary sphincterotomy. New England Journal of Medicine. 1996;335(13):909–19. <https://doi.org/10.1056/nejm199609263351301>
- Williams E, Taylor S, Fairclough P, et al. Risk factors for complication following ERCP; results of a large-scale, prospective multicenter study. Endoscopy. 2007;39(09):793–801. <https://doi.org/10.1055/s-2007-966723>
- Tarikci Kilic E, Kahraman R, Ozdil K. Evaluation of Safety and Outcomes of Endoscopic Retrograde Cholangiopancreatography in 1337 Patients at a Single Center. Medeniyet Medical Journal. 2019;34(3). doi: 10.5222/MMJ.2019.58265
- Gurung R, Purbey B, Koju R, et al. Endoscopic retrograde cholangiopancreatography at Dhulikhel Hospital: outcome analysis. Kathmandu University Medical Journal. 2014;12(1):55–9. <https://doi.org/10.3126/kumj.v12i1.13640>
- Gnawali A, Pathak R, Pandey R, et al. Endoscopic Extraction of CBD Stone: single centre experience in tertiary care centre. Journal of Advances in Internal Medicine. 2020;9(1):29–33. <https://doi.org/10.3126/jaim.v9i1.29164>
- Sebghatollahi V, Parsa M, Minakari M, et al. A clinician's guide to gallstones and common bile duct (CBD): A study protocol for a systematic review and evidence-based recommendations. Health Science Reports. 2023;6(9):e1555
- Meseeha M, Attia M. Endoscopic retrograde cholangiopancreatography. 2018. PMID: 29630212 Bookshelf ID: NBK493160
- Iida F, Kusama J. Surgical evaluation of endoscopic retrograde cholangiography for biliary tract diseases. The Japanese journal of surgery. 1982;12:257–61. <https://doi.org/10.1007/bf02469557>
- Haraldsson E, Kylänpää L, Grönroos J, et al. Macroscopic appearance of the major duodenal papilla influences bile duct cannulation: a prospective multicenter study by the Scandinavian Association for Digestive Endoscopy Study Group for ERCP. Gastrointestinal endoscopy. 2019;90(6):957–63. <https://doi.org/10.1016/j.gie.2019.07.014>
- Gutierrez-De Aranguren C, Parra-Perez V, et al. Association between the type of major duodenal papilla and difficult biliary cannulation in a private tertiary center. [Article in Spanish] Rev Gastroenterologia Peru 2021;41(3):169–75. PMID: 34978554
- Chen PH, Tung CF, Peng YC, et al. Duodenal major papilla morphology can affect biliary cannulation and complications during ERCP, an observational study. BMC gastroenterology. 2020;20:1–8. <https://doi.org/10.1186/s12876-020-01455-0>
- Andriulli A, Loperfido S, Napolitano G, et al. Incidence rates of post-ERCP complications: a systematic survey of prospective studies. Official journal of the American College of Gastroenterology| ACG. 2007;102(8):1781–8. <https://doi.org/10.1111/j.1572-0241.2007.01279.x>
- Vandervoort J, Soetikno RM, Tham TC, et al. Risk factors for complications after performance of ERCP. Gastrointestinal endoscopy. 2002;56(5):652–6. <https://doi.org/10.1067/mge.2002.129086>
- Elmunzer BJ. Reducing the risk of post-endoscopic retrograde cholangiopancreatography pancreatitis. Digestive Endoscopy. 2017;29(7):749–57. <https://doi.org/10.1111/den.12908>
- Hormati A, Aminnejad R, Saeidi M, et al. Prevalence of anesthetic and gastrointestinal complications of endoscopic retrograde cholangiopancreatography. Anesthesiology and Pain Medicine. 2019;9(4). <https://doi.org/10.5812/aapm.95796>