

Risk factors associated with retinopathy of prematurity among neonates in a tertiary care hospital in Nepal

Shrestha JB¹, Yadav R², Shrestha JK³, Shrestha L⁴, Sah RP⁵

¹Jyoti Baba Shrestha, Associate Professor, Department of Ophthalmology, Institute of Medicine, Tribhuvan University; ²Reena Yadav, Ophthalmologist, Sagarmatha Chaudhary Eye Hospital; ³Jeevan Kumar Shrestha, Professor, Department of Ophthalmology, Institute of Medicine, Tribhuvan University; ⁴Laxman Shrestha, Professor, Department of Paediatrics, Institute of Medicine, Tribhuvan University; ⁵Raman Prasad Sah, Optometry officer, BP Koirala Lions Centre for Ophthalmic Studies

Abstract

Background: Retinopathy of prematurity is a vascular retinal disease that can cause blindness in premature new born babies. Several risk factors are associated with the incidence of ROP. Information and data on risk factors associated with ROP in context to Nepalese population is scarcely documented in literature.

Objectives: The purpose of this study was to evaluate the risk factors of retinopathy of prematurity in premature infants admitted in the neonatal intensive care unit of Tribhuvan University Teaching Hospital.

Methods: Neonates with gestational age of 36 weeks or less and birth weight of 2000 gram or less admitted to neonatal intensive care unit (NICU), during 2013 to 2015 were screened for retinopathy of prematurity. Risk factors and severity of retinopathy of prematurity were evaluated. The initial examination was carried out at 4-6 weeks after birth by indirect ophthalmoscope and retinopathy of prematurity positive and negative infants were compared subsequently. The Chi-square and independent *t*-tests were used for statistical analysis. A *p* value less than 0.05 was considered statistically significant.

Results: The incidence of retinopathy of prematurity was 22.6% and severe retinopathy of prematurity requiring treatment was observed in 3.2% of 93 neonates who had eye examinations. There was a significant relationship between the occurrence of ROP and birth weight ($p=0.000$), gestational age ($p=0.000$), duration of oxygen therapy ($p=0.009$) and sepsis ($p=0.002$). However, insignificant relationship was observed between the occurrence of retinopathy of prematurity and gender, type of delivery, multiple gestation, premature rupture of foetal membrane, respiratory distress syndrome and hyperbilirubinaemia.

Conclusion: The risk factors contributing to development of retinopathy of prematurity showed significant relationship with immaturity, duration of oxygen supplementation and septicemia.

Key words: Blindness, Retinopathy of prematurity, Risk factors

INTRODUCTION

Retinopathy of prematurity (ROP) is a proliferative retinopathy affecting premature infants of very low birth weight. With premature birth, progression of normal retinal vascularization is arrested, which is followed by excessive production of vascular endothelial growth factor (VEGF) that results in the neovascular complications of retinopathy of prematurity leading to blindness in children. It is one of the treatable causes of

visual impairment and blindness in premature infants¹. The incidence of ROP is low in developing countries, due to low survival rate of premature infants². However, neonatal mortality rate in Nepal has declined from 45.2 in 2002 to 24 in 2012 per 1000 live births due to improved neonatal care and support, and subsequently predisposing these premature neonates at a risk of developing ROP³.

The major risk factor of ROP is the degree of immaturity as measured by either birth weight or gestational age⁴⁻⁶, the first being the more powerful predictor. Clinical studies have confirmed the relationship between oxygen and ROP^{5,6}.

Address for correspondence

Dr. Jyoti Baba Shrestha
Associate Professor
Department of Ophthalmology
Institute of Medicine, Tribhuvan University
E-mail: jyotibaba@gmail.com

Factors like increasing prematurity, low birth weight and prolonged exposure to supplementary oxygen have been consistently identified risk factors for the causation of ROP^{3,4}. Several other risk factors have also been implicated such as gender, phototherapy for the treatment of hyperbilirubinaemia in neonates, anaemia needing blood transfusion, sepsis, apnoea, respiratory distress syndrome, multiple pregnancy and intraventricular haemorrhage⁷⁻¹⁰. Nevertheless, a preterm extremely low birth weight neonate can develop ROP even without exposure to oxygen or presence of these risk factors. Few studies in the recent past from Nepal have focused exclusively on the incidence of ROP only^{11,12}. Therefore it is now necessary to study the risk factors associated with the development of ROP in Nepalese neonates. The aim of this prospective study was to find out the risk factors which contribute to the development of ROP in neonates admitted to Neonatal Intensive Care Unit (NICU) in a tertiary care hospital in Nepal.

METHODS

All neonates weighing ≤ 2000 grams and/or with a gestation age ≤ 36 weeks admitted to NICU at a tertiary referral hospital (Tribhuvan University Teaching Hospital) in Nepal from 2013 to 2015 were enrolled in this study. Initial eye examinations were performed at four to six weeks after birth. Further examinations were carried out whenever required as indicated by clinical findings. The pupils were dilated with topical tropicacyl (combination of tropicamide 1% and phenylephrine 2.5% eye drop). The eye drop was instilled three times at 15-minute intervals for approximately 1 hour before the scheduled examination. For topical anaesthesia, one drop of 2% proparacaine was used. An infant wire eye speculum (K 1-5350; Katena Products, Inc., Denville, NJ) was used for eyelid retraction. Fundus evaluation was done with a 20 dioptre lens using a binocular indirect ophthalmoscope. A scleral depressor was used to indent the wall of the eye to visualize the retinal periphery routinely.

Patients were recorded as being ROP positive if they were noted to have Stage 1 disease or worse.

ROP classification and staging was performed using the International classification of ROP (ICROP)¹³. ICROP defines the location of disease in the retina and the extent of involvement of the developing vasculature. It also specifies the stage of involvement with levels of severity ranging from Stage 1 (least affected) to Stage 5 (severe disease). The classification involves describing severity of ROP by stage as retinopathy at the junction between the vascularised and avascular retina.

STAGE 1

A flat grey-white demarcation line separates the vascularized from non-vascularized retina. Often faint, it can be difficult to identify. Retinal vessels run up to the line but do not cross it.

STAGE 2

The demarcation line has increased in volume and extends out of the plane of the retina. The colour of the ridge may be white or pink and small neovascular tufts may be seen posterior to the ridge.

STAGE 3

It has the features of stage 2, but is characterized by extraretinal neovascularization. The new vessels may be continuous with, or disconnected from, the posterior border of the ridge, or extend into the vitreous. The extraretinal neovascularization may extend from the region of the ridge into the vitreous or, typically in more posterior disease, lies back across the surface of the vascularized retina.

STAGE 4

This is characterized by subtotal exudative or tractional retinal detachment that is extrafoveal (stage 4B), or involves the foveal region (stage 4A).

STAGE 5

There is a funnel-shaped total retinal detachment. This stage is further defined according to the anterior and posterior characteristics of the funnel.

Plus disease is described as tortuosity of the retinal arterioles and congestion of the retinal veins close to the optic disk. Signs of plus disease may appear at any ROP stage and the diagnosis of plus disease is critical and is an indicator of severe ROP that requires treatment.

Newborns were categorized into two groups: case (ROP positive) and control (ROP negative). Comparisons were made between all ROP positive and ROP negative infants.

Data for birth weight and gestational age were collected from the NICU and admission records. Additional data recorded for each infant included gender, type of delivery, history of sepsis, respiratory distress syndrome (RDS), jaundice, days on oxygen, premature rupture of membrane (PROM) and multiple gestations. These were the neonatal and maternal risk factors explored for the causation of ROP in the study.

The data was entered and analysed using SPSS 20 software. The Chi-square and independent *t*-tests were used for statistical analysis. A value of $p \leq 0.05$ was considered statistically significant.

Ethical clearance was obtained from the Institutional Review Board (IRB) of Institute of Medicine. Informed written consent was taken from parents of study groups.

RESULTS

A total of 120 neonates were admitted in the NICU during the study period 2013-2015. A complete data of 19 cases could not be retrieved and 8 babies left the hospital against medical advice. Ninety three infants who fulfilled the inclusion criteria were assessed in the study period. There were 52 males (60%) and 41 females (40%). The mean gestational age was 31.64 ± 2.37 weeks (range, 27.2-36 weeks). The mean birth weight was 1491.77 ± 252.37 gram (range, 790-2000 gram). There was normal vaginal delivery in 46 (49%) cases and 47 (50.5%) cases were delivered via caesarean section and 32 (34.4%) of the infants were twins and 61 (65.6%) were single. Thirty six (38.7%) babies had jaundice in the study group.

Of the mothers, 28 (31%) had a history of premature rupture of the membrane (PROM).

Retinopathy of prematurity (ROP) was observed in 22.6% ($n=21$) of neonates (Figure 1) in the present study. Stage 3 plus ROP was present in 3.2% ($n=3$) of infants who underwent laser treatment. Among the infants with ROP, 71% ($n=15$) were males and 29% ($n=6$) were females. ROP was more common in boys than in girls. The male to female ratio in infants with ROP was 2.5:1 and 1:1 in ROP negative group. However, association of ROP and male gender was not statistically significant ($p=0.08$) in this study.

The mean gestational age for ROP positive group was 29.80 ± 1.54 weeks and 32.16 ± 2.32 weeks for ROP negative group. The difference in GA between the ROP positive and ROP negative groups was statistically significant ($p < 0.001$). The lower gestational age found in the ROP group was identified as a risk factor for the development of ROP. The mean birth weight in the ROP positive group was 1238.19 ± 176.00 g and 1558.43 ± 235.70 g in the ROP negative group. The higher incidence of ROP with decreasing birth weight was strongly correlated. The difference in two groups was statistically significant ($p=0.000$). In the ROP group, 12.9% ($n=12$) had stage 1 ROP, 6.5% ($n=6$) had stage 2 ROP and 3.2% ($n=3$) had Stage 3 plus ROP (Figure 1). However stage 4 and stage 5 ROP was not observed. Oxygen was received by 16 neonates (76%) in ROP positive group and 39 neonates (54%) in control group ($p=0.005$). Likewise longer duration of oxygen intake (7.34 ± 6.31 days in mean) and the development of ROP in ROP positive babies could be strongly co-related as compared to the ROP negative babies who were exposed to oxygen for relatively shorter duration (3.10 ± 3.57 days in mean) (Table 1). Thirteen (30.2%) babies with ROP had respiratory distress syndrome (RDS) as compared to thirty (69.8%) babies without ROP. There was no significant difference between the cases and controls and associated respiratory distress syndrome ($p=0.08$). A total of 16 babies in ROP group ($n=21$), and 27 in ROP negative group ($n=72$) had associated septicaemia. The co-relation was statistically significant for the occurrence of ROP and septicaemia ($p=0.002$). ROP development was not significantly associated with hyperbilirubinaemia in neonates ($p=0.66$). Moreover, the type of delivery, multiple birth or premature rupture of membrane and the development of ROP ($p > 0.05$) could not be co-related by the present study (Table 1).

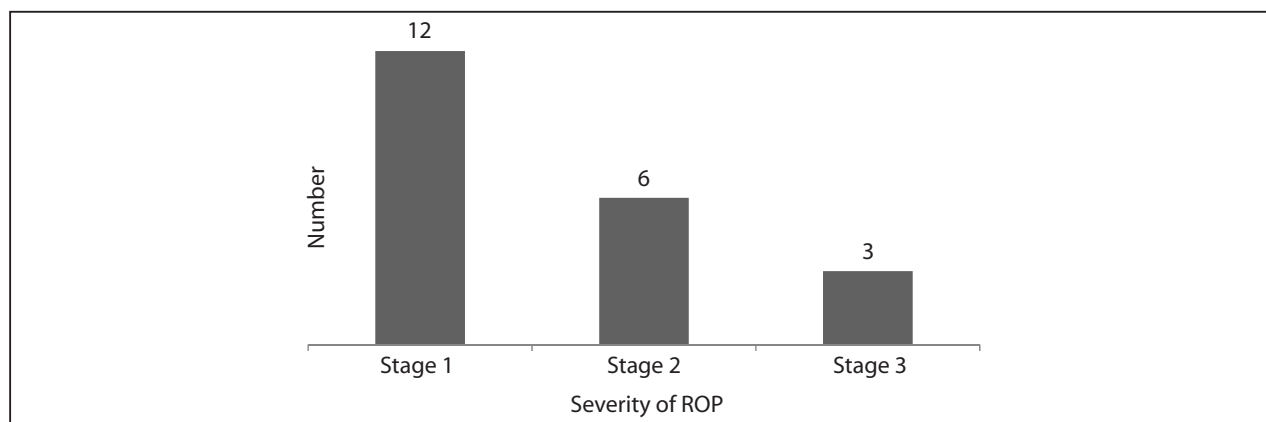


Figure 1: Stages of ROP

Table 1: Association of various risk factors with ROP positive and ROP negative groups

Risk factors		ROP positive n=21 (22.6%)	ROP negative n=72 (77.4%)	p-value
Gestational age, weeks		29.80± 1.54	32.16± 2.32	<0.001
Birth weight, gram		1238.19± 176.00	1558.43± 235.70	<0.001
Gender	Male	15 (28.8%)	37 (71.2%)	0.08
	Female	6 (14.6%)	35 (85.4%)	
Delivery type				
Normal		13 (28.3%)	33 (71.7%)	0.15
Caesarean section		8 (14.6%)	35 (83%)	
Gestation				
Multiple		8 (25%)	24 (75%)	0.44
Single		13 (21.3%)	48 (78.7%)	
Duration of oxygen therapy, days (mean)		7.34± 6.31	3.10± 3.57	0.009
Sepsis		16 (37.2%)	27 (62.8%)	0.002
Respiratory distress syndrome (RDS)		13 (30.2%)	30 (69.8%)	0.08
PROM		6 (21.4%)	22 (78.6%)	0.55
Hyperbilirubinaemia		9 (25%)	27 (75%)	0.66

DISCUSSION

ROP is a leading cause of treatable visual impairment in premature babies. Recently, many eye hospitals in Nepal have been involved in the screening of preterm babies for early detection of ROP which is a crucial step in protecting these babies from blindness. Moreover, with the availability of advanced ventilator services in the NICU, survival of smaller and sick neonates is increasing. As a consequence, the incidence of ROP is likely to rise in Nepal as more premature infants are expected to survive³ and more ROP examinations are going to be performed.

In this study, the incidence of ROP was observed in 22.6% of premature babies, which is comparable with reports from other countries. Several other studies have reported similar incidence of ROP as in India (27%)¹⁴, Iran (26.2%)¹⁵, Singapore (29.3%)⁹, Nepal (29.5%)¹¹, India (22.3%)¹⁶ and a little higher in Turkey (30%)¹⁷ and much lower in China (12.7%)¹⁸.

Few epidemiologic studies have identified male gender as an independent risk factor for ROP^{7, 19-21}. Male gender is found to be associated significantly with an increased risk of progression beyond Stage 2²². The explanation of better outcome in females is not clear. But the difference has been suggested to result from a different hormonal milieu associated with increased organ maturation, compared with male infants of the same GA²³. But there was no significant difference in the incidence of ROP between males and females in this study. A similar finding is reported in a study by Chaudhari et al¹⁷.

The mean gestational age for ROP positive group was 29.80± 1.54 weeks. Many other studies have shown the similar incidence of ROP with decreasing gestational ages of 30.5 weeks¹⁴, 29.7 weeks¹⁵ and 29.1 weeks¹⁸. In addition, the mean birth weight for ROP positive group was 1238.19± 176.00 grams. The study from India¹⁴ also reported the same result about the birth weight (1249± 276 gram). Whereas a report from China showed even lower birth weight (855.0± 199.0 gram)¹⁹. However Stage 4 and stage 5 ROP was not observed and no ROP was detected in infants greater than 32 weeks of gestational age and above 1500 grams of birth weight by the current study. The finding is consistent with the study done a decade ago in NICU of another tertiary hospital in Nepal¹¹. Presentation of ROP in infants with lower gestational age (≤32 weeks GA) and birth weight (≤1500g) suggests there should be set appropriate screening criteria for detecting premature infants with ROP in Nepal. Absence of advanced stages of ROP found in this study could be related to early diagnosis and thereby secondary prevention of visual loss by appropriate management.

Patz et al demonstrated the casual effects of high oxygen administration on the development of ROP²⁴. Longer duration of oxygen supplementation has been suggested to be related to ROP severity^{14,25,26}. Our analysis reveals similar finding. The mean duration of oxygen received by ROP group was 7.34±6.31 days and ROP negative group was 3.10± 3.57 days (p=0.009). The oxygen saturation level in all cases were in the range of

70- 90%. This may have reflected the lower incidence/ absence of advance stages (Stage 4 and Stage 5) of ROP requiring surgical treatment.

Insignificant association, found in our study between ROP; and the gender, the type of delivery, multiple gestation, premature rupture of foetal membrane, respiratory distress syndrome, and hyperbilirubinaemia, was also observed in other published data^{16,27}. Bassiouny et al²⁷ reported that lower BW, GA, apnoea, blood transfusion, mechanical ventilation, metabolic acidosis, intraventricular haemorrhage and sepsis were associated with development of ROP. Significant association of sepsis with the presence of ROP ($p=0.002$) in this study is similar to reports from other part of world²⁸⁻³⁰, indicating

that there exists inadequate neonatal care in NICU which warrants improvement.

The ROP group in the current study had statistically significant low birth weight, younger gestational age, higher incidence of septicaemia and longer duration of oxygen administration when compared to infants who did not have ROP.

CONCLUSION

The incidence of ROP in premature infants was 22.6%. Immaturity, septicaemia and duration of oxygen therapy were the main risk factors for the development of ROP. Prevention of prematurity, appropriate medical care of neonates and judicious use of oxygen may reduce the incidence of ROP in these new born babies.

REFERENCES

- Purohit DM, Ellison RC, Zierler S, Miettinen OS, Nadas AS. Risk factors for retrolental fibroplasia: experience with 3,025 premature infants. National collaborative study on patent ductus arteriosus in premature infants. *Pediatr*.1985; 76:339-44.
- Gilbert C, Rahi J, Eckstein M, O'Sullivan J, Foster A. Retinopathy of prematurity in middle-income countries. *The Lancet*.1997; 350:12-4.
- United Nations Children Fund. Statistics Nepal UNICEF, 2012. Available at: https://www.unicef.org/infobycountry/nepal_nepal_statistics.html.
- Avery GB, Glass P. Retinopathy of prematurity: progress report. *Pediatr Ann*. 1988; 17: 532-3.
- Flynn JT. Retinopathy of prematurity. *Pediatr Clin North Am*. 1987; 34: 1487-1516.
- McColm JR, Fleck BW. Retinopathy of prematurity causation. *Semin Neonatol*. 2001; 6: 453-60.
- Nødgaard H, Andreassen H, Hansen H, Sørensen HT. Risk factors associated with retinopathy of prematurity (ROP) in northern Jutland, Denmark 1990-1993. *Acta Ophthalmol Scand*. 1996; 74:306-10.
- Karkhaneh R, Riazi-Esfahani M, Ghojzade L, Kadivar M, Nayeri F, Chams H, et al. Incidence and risk factors of retinopathy of prematurity. *Bina J Ophthalmol*. 2005; 11:81-90.
- Shah VA, Yeo CL, Ling YL, Ho LY. Incidence, risk factors of retinopathy of prematurity among very low birth weight infants in Singapore. *Ann Acad Med Singapore*. 2005; 34:169-78.
- Karkhaneh R, Mousavi SZ, Riazi-Esfahani M, Ebrahimzadeh SA, Roohipoor R, Kadivar M, et al. Incidence and risk factors of retinopathy of prematurity in a tertiary eye hospital in Tehran. *Br J Ophthalmol*. 2008; 92:1446-9.
- Shrestha JB, Bajimaya S, Sharma AK, Shrestha JK, Karmacharya PC. Incidence of Retinopathy of Prematurity in a Neonatal Intensive Care Unit in Nepal. *Journal of Pediatr Ophthalmol Strabismus*.2010; 47: 297-300.
- Adhikari S, Badhu BP, Bhatta NK, Rajbhandari RS, Kalakheti BK. Retinopathy of prematurity in a tertiary care hospital in eastern Nepal. *JNMA*. 2008; 47:24-7.
- International Committee for the Classification of Retinopathy of Prematurity. The International Classification of Retinopathy of Prematurity revisited. *Arch Ophthalmol*.2005; 123:991-9.
- Maheshwari R, Kumar H, Paul VK, Singh M, Deorari AK, Tiwari HK. Incidence and risk factors of retinopathy of prematurity in a tertiary care newborn unit in New Delhi. *Natl Med J India*.1996; 9(5):211-4.
- Abrishami M, Maemori GA, Boskabadi H, Yaeghobi Z, Shahin MN. Incidence and Risk Factors of Retinopathy of Prematurity in Mashhad, Northeast Iran. *Iranian Red Crescent Med J*. 2013; 15 (3): 229-33.
- Chaudhari S, Patwardhan V, Vaidhya U, Kadam S, Kamat A. Retinopathy of Prematurity in a Tertiary Care Center – Incidence, Risk Factors and Outcome. *Indian Pediatr*. 2009 Mar; 17: 219-24.
- Bas A. Y, Koc, E. Dilmen, U. R. O. P. Neonatal Study Group. Incidence and severity of retinopathy of prematurity in Turkey. *Br J Ophthalmol*. 2015; 99(10): 1311-4.
- Yau GS, Lee JW, Tam VT, Liu CC, Wong IY. Risk factors for retinopathy of prematurity in extremely preterm Chinese infants. *Medicine*. 2014; 93:e314.
- Wheatley CM, Dickinson JL, Mackey DA, Craig JE, Sale MM. Retinopathy of prematurity: recent

- advances in our understanding. *Br J Ophthalmol.* 2002; 86:696–700.
20. Darlow BA, Hutchinson JL, Henderson-Smart DJ, Donoghue DA, Simpson JM. Prenatal risk factors for severe retinopathy of prematurity among very preterm infants of the Australian and New Zealand neonatal network. *Pediatr* 2005 Apr; 115(4) : 990-6.
 21. Quinn GE, Gilbert C, Darlow BA, Zin A. Retinopathy of prematurity: An epidemic in the making. *Chin Med J.* 2010;123:2929–37.
 22. Todd D, Kennedy J, Roberts V, John E. Risk factors in progression beyond stage 2 retinopathy of prematurity. *Aust NZ J Ophthalmol.*1990; 18:57–60.
 23. Ingemarsson I. Gender aspects of preterm birth. *Br J Obstet Gynaecol.* 2003; 110(20):34–8.
 24. Patz A, Hoeck LE, De La Cruz E. Studies on the effect of oxygen administration in retrolental fibroplasia: nursery observations. *Am J Ophthalmol.* 1952; 35:1248-53.
 25. Ashton N, Ward B, Serpell G. Effect of oxygen on developing retinal vessels with particular reference to the problem of retrolental fibroplasia. *Br J Ophthalmol.* 1954; 38(7): 397– 432.
 26. Teoh SL, Boo NY, Ong LC, Nyein MK, Lye MS, Au MK. Duration of oxygen therapy and exchange transfusion as risk factors associated with retinopathy of prematurity in very low birth weight infants. *Eye.* 1995; 9:733–7.
 27. Bassiouny MR. Risk factors associated with retinopathy of prematurity: a study from Oman. *J Trop Pediatr.* 1996; 42:355-8.
 28. Akcakaya A A, Yaylali S A, Erbil H H, Sadigov F, Aybar A. Screening for retinopathy of prematurity in a tertiary hospital in Istanbul: incidence and risk factors. *J Pediatr Ophthalmol Strabismus.* 2012; 49(10):21-5.
 29. Celebi AR, Petricli IS, Hekimoglu E, Demirel N, Bas AY. The incidence and risk factors of severe retinopathy of prematurity in extremely low birth weight infants in Turkey. *Med Sci Monit.*2014; 20:1647-53.
 30. Fegghi M, Altayeb SM, Haghi F, Kasiri A, Farahi F, Dehdashtyan M. Incidence of retinopathy of prematurity and risk factors in the South-Western region of iran. *Middle East Afr J Ophthalmol.* 2012;19:101-6.