

## Diagnostic Utility of Bone Marrow Aspiration Cytology- A Hospital Based Prospective Study at Nepalgunj Medical College

Adhikari M<sup>1</sup>, Ghimire PG<sup>1</sup>, Shrestha R<sup>1</sup>, Baidya P<sup>1</sup>, Rayamajhi A<sup>2</sup>

### ABSTRACT

**Introduction:** Hematological disorders are common in all age groups and are worldwide in distribution. At times, routine hematological tests are not sufficient to diagnose blood disorders. Bone marrow examination serves as an important diagnostic aid to evaluate various neoplastic and non-neoplastic hematological diseases. **Aims:** To study role of Bone Marrow Aspiration Cytology in diagnosing hematological disorders. **Methods:** This is a one-year hospital based prospective study done at Department of Pathology, Nepalgunj Medical College, Kohalpur. It included 34 cases subjected to Bone marrow aspiration cytology. Correlation with Peripheral Blood Smear, Reticulocyte count, pearls iron stain and other parameters were done before giving the final diagnosis. **Results:** Age of patients ranged from 10-82 years with equal gender distribution. Common indications for Bone marrow examination were pancytopenia (50%), followed by Anemia and Thrombocytopenia. Megaloblastic Anemia (n=10,29%) was the commonest Anemia followed by mixed nutritional deficiency and Iron Deficiency Anemia. Hematological Malignancy accounted for six cases, of which Acute Myeloid Leukemia was diagnosed in two cases. Infectious causes comprised of two cases of Visceral Leishmaniasis and one case of Bone Marrow Tuberculosis. **Conclusion:** Bone marrow aspiration cytology serves as an important adjunct in diagnosing hematological disorders. More reproducible results are obtained if bone marrow biopsy is done in conjunction with aspiration cytology.

**Keywords:** Anemia, Bone Marrow, Cytology, Hematology, Pancytopenia

### Authors:

1. Dr. Milan Adhikari
2. Dr. Pragya Gautam Ghimire
3. Dr. Richa Shrestha
4. Dr. Pooja Baidya
5. Ms. Asmita Rayamajhi

<sup>1</sup>Department of Pathology, Nepalgunj Medical College and Teaching Hospital, Kohalpur, Banke, Nepal

<sup>2</sup>Kapilvastu Integrated Development Services (KIDS)

### Address for Correspondence:

Dr Milan Adhikari  
Lecturer  
Department of Pathology  
Nepalgunj Medical College & Teaching Hospital  
Kohalpur, Banke, Nepal  
Email: milanadhikari011@gmail.com

### INTRODUCTION

Hematological disorders are common in all age groups and are worldwide in distribution. Most common hematological disorder in our part of world is Anemia. Various types of anemia and other cytopenias can be correctly diagnosed by clinical as well routine hematological tests.<sup>1</sup> At instances, peripheral blood film examination along with other routine hematological tests are not sufficient to diagnose blood disorders. Bone marrow examination thus serves as an important diagnostic adjunct to evaluate various disorders including both neoplastic and non-neoplastic hematological diseases.<sup>2-4</sup> Bone Marrow Aspiration (BMA) is a minimally invasive procedure, where hematopoietic cells are aspirated from the spongy bone marrow by the help of a

needle for diagnostic evaluation.<sup>4</sup> Posterior superior iliac spine is the preferred site for aspiration. Slides thus prepared can be used for the morphological evaluation of the hematopoietic cells along with application of special stains like Pearls Iron stain (to evaluate the iron store), ZN stain and Periodic Acid Schiff (PAS).<sup>2</sup> Various indications of bone marrow aspiration cytology include hematological disorders, malignancies, storage diseases and chronic systemic disorders.<sup>5</sup> Bone marrow aspiration cytology examination has started in our laboratory as a routine OPD procedure from the past two years. Our institution is a tertiary care hospital and a referral central for many of the mid and far western districts of our country. This study, hence was done to evaluate the role of bone marrow aspiration cytology in diagnosing various hematological and non-hematological disorders.

**METHODS**

This is a hospital based prospective study conducted over a period of one year starting from December 2022 to November 2023 in department of Pathology, Nepalgunj Medical College-Kohalpur. Ethical clearance was obtained from IRC, NGMC. Patients visiting any department advised for Bone marrow aspiration cytology were included in the study after receiving a verbal consent. A total of 34 cases of BMA examination, who presented during the study period were included in the study. Peripheral blood smear examination study was also done if patients presented before any blood transfusion. Patients of all age group and both sexes were included in the study. Samples which were inadequate for evaluation due to diluted marrow by peripheral blood or a dry tap were excluded from this study. Aspiration was done from posterior superior iliac spine by suitable sized needles under aseptic conditions. Slides were air dried and stained for Giemsa and Pearls Iron stain as per standard staining protocols. Clinical and Radiological correlation were done in available cases following which slides were reviewed and reporting done as per the standard bone marrow examination format. Special stains were applied as and when needed. Cell blocks were made and processed and stained as per the routine Standard procedure for Hematoxylin and Eosin staining.

Data were analyzed using Microsoft excel 2010 and standard statistical software SPSS 20.0.

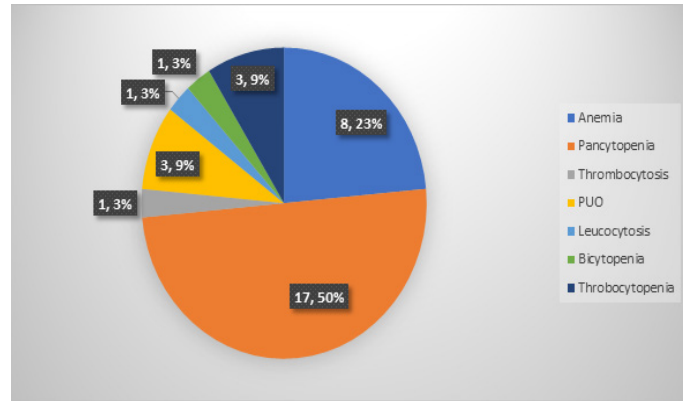
**RESULTS**

A total of 34 BMA cases were included in the study. Age of the patients ranged from 10-82 years, with the maximum number of patients falling in the age range 31-45 years. Of the 34 cases half were male (n=17) and half were female (n=17) (Table I).

Age group	Sex= (n%)		Percentage (%)
	Male	Female	
≥ 15	1 (33.33)	2 (66.66)	3 (8.82)
16-30	2 (28.57)	5 (71.43)	7 (20.58)
31-45	8 (61.64)	5 (38.46)	13 (38.23)
46-60	2 (40)	3 (60)	5 (14.73)
> 61	4 (66.66)	2 (33.34)	6 (17.64)
Total	17 (50)	17 (50)	34 (100.0)

**Table I: Age group and sex of patients**

The commonest indication for BMA examination was Pancytopenia (n=17, 50%) followed by Eight cases of Anemia (23%), three each of Thrombocytopenia (9%) and Pyrexia of Unknown Origin (PUO) (9%) along with one each case of Bicytopenia, Leukocytosis and Thrombocytosis. (Figure 1)



**Figure 1: Indications for BMA examination**

Most of the patients had multiple symptoms. Fever, weakness and fatigue were the common symptoms followed by headache and skin rashes. Limb edema, pain abdomen, palpitation and SOB were the less common symptoms in the patients presenting for BMA examination. (Table II)

Symptoms	No. of cases
Fever	20
Weakness	12
Fatigue	10
Headache	08
Skin rashes	07

**Table II: Common presenting complaints**

BMA findings in most cases showed Hypercellular Marrow with Erythroid Hyperplasia (n=27,80%), followed by six cases of normocellular marrow and a single case of marrow hypocellularity.

Cellularity	No. of cases	Percentage (%)
Hypercellular	27	80
Normocellular	6	17
Hypocellular	1	3

**Table III: Marrow Cellularity in BMA aspirates**

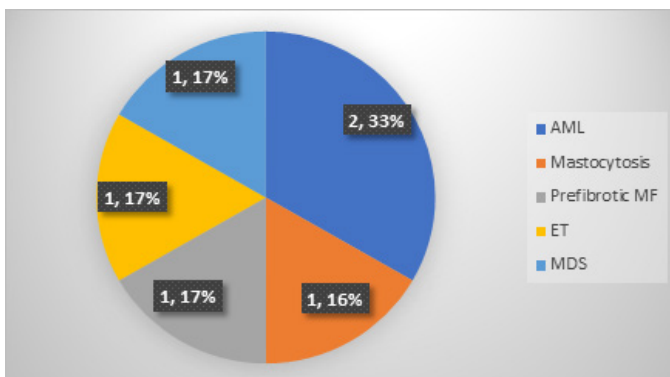
After the evaluation of PBS and bone marrow aspiration, diagnosis was grouped as Anemia (n=18,53%), malignancy (n=6,18%), infections (n=3, 9%) and miscellaneous (n=7, 20%). Anemia was then categorized by correlating with bone marrow iron store (pearls iron stain), reticulocyte count (%) and other blood investigations when available. Thus the final diagnosis of the cases was given as shown in Table IV.

Disease	N=34(%)
Megaloblastic Anemia	10 (29.41)
Mixed Nutritional Deficiency Anemia	4 (11.76)

Iron Deficiency Anemia	3 (8.82)
Aplastic Anemia	1 (2.94)
Reactive Marrow	3 (8.82)
Visceral Leishmaniasis	2 (5.87)
TB	1 (2.94)
Haemophagocytic Syndrome	2 (5.88)
Malignancy	6 (17.65)
Megakaryocytic Thrombocytopenia	2 (5.87)

**Table IV: Disease diagnosed by bone marrow aspirate cytology**

Megaloblastic Anemia was the most common diagnosed entity via BMA (n=10, 29.41%) followed by hematological Malignancies (n=6, 17.65%). Other anemias diagnosed by BMA were four cases of Mixed Nutritional Deficiency and three cases of Iron Deficiency Anemia (IDA). Two cases each of Visceral Leishmaniasis, megakaryocytic Thrombocytopenia and Hemophagocytic Syndrome along with one case each of Bone Marrow Tuberculosis and Aplastic Anemia were diagnosed by BMA evaluation. Of the six hematological malignancies diagnosed, two cases were Acute Myeloid Leukemia (AML), one case each of Prefibrotic Myelofibrosis, Essential Thrombocythemia, Systemic Mastocytosis and Myelodysplastic Syndrome were diagnosed by BMA study.



**Figure 2: Malignancies diagnosed by BMA**

**DISCUSSION**

Bone marrow aspiration cytology is a simple, minimally invasive, cheap and OPD based procedure done routinely. BMA has been established as an important adjunct in diagnosing hematological disorders where routine blood investigations are of not much help. Bone marrow aspiration in conjunction with bone marrow biopsy examination is used in most of the centers for diagnosing hematological disorders. We could not correlate with biopsy findings in this study as Bone

marrow biopsy is not being done in our institution. However, cell block preparations were made whenever possible and correlation with cell block findings were done. We studied a total of 34 BMA cases over a period of one year. Highest number of cases were in between the 3<sup>rd</sup> and 4<sup>th</sup> decade of age which is in concordance to other studies conducted by Prabhala S et al, Basir N et al, and Ranabhat S et al.<sup>5-7</sup> Half of the patients were male and the other half were female. This signifies hematological disorders do not have specific gender predilection and is equally common in both male and female. Near comparable results were also seen in other studies done globally.<sup>8,9,10</sup> Fever and weakness were the commonest symptoms in patients who were subjected to bone marrow evaluation. Pallor was the universal sign present in almost all patients. Other complaints that followed were fatigue, headache, skin rashes and limb edema. These findings are in concordance with the studies done by Prabhala S et al and Vaidya et al.<sup>6,11</sup>

Most of the patients subjected for bone marrow examination showed pancytopenia in their CBC profile. This was followed by anemia as the second most common indication in our study. Most of the studies done globally also show these two entities as the common indications for BMA examination. This was followed by Leukocytosis, Pyrexia of Unknown origin, Thrombocytopenia and Thrombocytosis.<sup>8,10,12,13</sup>

Anemia was the most common diagnosis made via bone marrow aspiration examination. Megaloblastic Anemia was the commonest one of all, followed by mixed nutritional deficiency anemia and iron deficiency Anemia. These findings are similar to many studies done globally some of them being studies done by Ranabhat et al, Basir et al, Jha et al, Vaidya S, Prabhala et al,<sup>5-7,11,14</sup> Therefore, majority of the BMA smears were hypercellular for age, owing to erythroid series hyperplasia due to Anemia. Most of the Megaloblastic Anemia cases presented with Pancytopenia in CBC. (Picture 1) A single Pancytopenia case showed hypocellular marrow due to Aplastic Anemia. Some of the studies have shown Aplastic Anemia to be the commonest cause of Pancytopenia which is in contrast to our study.<sup>9</sup> It might largely be due to the fact that aplastic anemia in many instances on Bone marrow aspiration yield dry tap and hence are diagnosed by bone marrow biopsy. As Bone marrow biopsy were not done and dry Tap marrow excluded from our study, the cases of Aplastic Anemia might have been missed in our study.<sup>15</sup> Two cases of AML were diagnosed by BMA study, one of which presented with Pancytopenia in CBC with no blast cells visible in Peripheral blood smear. Other case presented with Leucocytosis but with sub leukemic Blast counts in Peripheral blood smear. AML M3 patients can present with Pancytopenia. Also in early stages of leukemia, peripheral blood smear might not be of help due to subleukemic blasts circulating in blood. Bone marrow aspiration cytology study in these borderline cases show good diagnostic yield, hence serves as an important adjunct in leukemia diagnosis. Studies done by Jha et al and Jalaeikhoo et al suggest AML to be the commonest malignancies seen in cases presenting with Pancytopenia.<sup>14,16</sup> (Picture 2) Both the cases were advised flowcytometry and cytogenetics for

categorization of AML. Other malignancies diagnosed by BMA were a single case each of Systemic Mastocytosis, Myelodysplastic syndrome, Prefibrotic Myelofibrosis and Essential Thrombocythemia. All of these diagnosis required further confirmation by bone marrow biopsy, and cytogenetic tests and hence were advised for the same in the report of aspiration cytology. PUO was another indication for which BMA was ordered. Of the three cases, two cases were diagnosed as visceral leishmaniasis and one case diagnosed as Bone marrow Tuberculosis. Visceral leishmaniasis cases presented with fever, anemia and splenomegaly. Bone marrow tuberculosis case presented with fever and Anemia. Bone Marrow Tuberculosis case was confirmed by demonstration of Acid Fast Bacilli via ZN stain. Visceral Leishmaniasis, demonstrated as extra and intracellular LD bodies was the commonest infection detected by bone marrow aspiration cytology (Picture 3) followed by TB as shown by studies done by Ranabhat et al, Pudasaini et al, and Kumar et al.<sup>5,10,17</sup>

Two cases of secondary Hemophagocytic syndrome were diagnosed via bone marrow aspiration cytology examination. Both these cases were diagnosed as Dengue fever by clinical and serological study. These patients were successfully managed and discharged, who subsequently presented with fever after some days. Here in, macrophages in the marrow are seen to have engulfed intact hematopoietic elements in their cytoplasm. Dengue fever has been known for causing Hemophagocytic Lymphohistiocytosis, also known as Secondary Hemophagocytic Syndrome. Studies done by Chang et al and Hein et al suggested cases of Dengue fever are commonly complicated by hemophagocytosis.<sup>18,19</sup>

## CONCLUSION

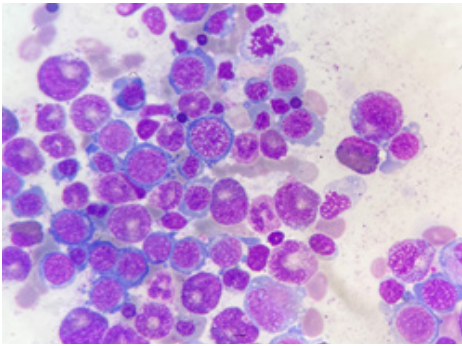
The findings of our study are in concordance to those of other studies done globally. Hence we can conclude that bone marrow aspiration cytology examination serves as an important diagnostic tool in various hematological and non-hematological disorders especially when routine investigations have limited diagnostic yield. A better yield can be obtained by correlating the BMA cytology findings with Bone marrow biopsy.

## LIMITATIONS

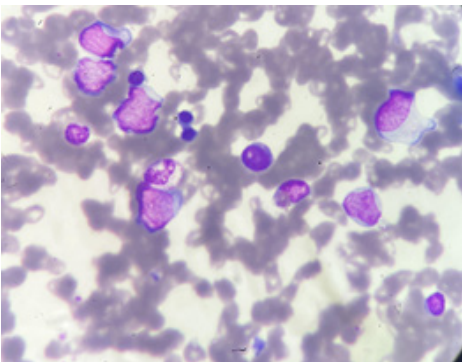
The most important limitation of our study is a small sample size. Biopsy follow up was not available in our cases. So cases where in aspiration was non diagnostic and yielded a dry tap had to be excluded owing to the lack of bone marrow biopsy follow up

## REFERENCES

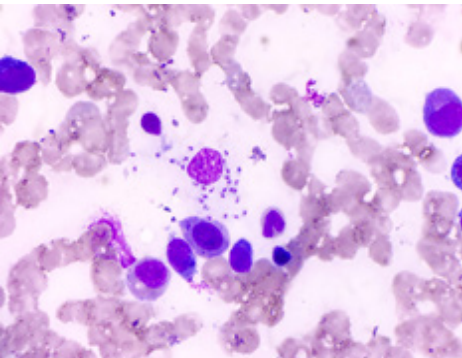
- Bain BJ. Bone marrow aspiration. *J Clin Pathol.* 2001;54(9):657–63.
- Tshabalala WS, Pillay S, Wilson DPK. Diagnostic outcomes of bone marrow aspirate and trephine biopsies performed at a hospital in KwaZulu-Natal, South Africa. *Afr J Lab Med.* 2020;9(1):1–6.
- Hyun BH, Stevenson AJ, Hanau CA. Fundamentals of Bone Marrow Examination. *Hematol Oncol Clin North Am.* 1994 Aug 1;8(4):651–63.
- Parajuli S, Tuladhar A. Correlation of bone marrow aspiration and biopsy findings in diagnosing hematological disorders - a study of 89 cases. *J Pathol Nepal.* 2014 Apr 25;4(7):534–8.
- Ranabhat S, Maharjan S, Tiwari M, Bhandari A, Osti BP. Bone marrow aspiration cytology in the diagnosis of hematologic and non-hematologic diseases in a multi-specialty hospital in Nepal. *Int J Res Med Sci.* 2017 Feb 20;5(3):922.
- Prabhala S, E J, B P, M S, T R. Bone Marrow Examination in Pancytopenia: a Study of Six Years. *J Evol Med Dent Sci.* 2014;3(65):14189–95.
- Bashir N, Musharaf B, Reshi R, Jeelani T, Rafiq D, Angmo D. Bone marrow profile in hematological disorders: an experience from a tertiary care centre. *Int J Adv Med.* 2018;5(3):608.
- Saqib Qayyum Ahmad, Obaid Ullah Khan NZ. Utility of Bone Marrow Examination in a Secondary Care Hospital. *J Rawalpindi Med Coll.* 2011;15(1):40–1.
- Pathak R, Jha A, Sayami G. Evaluation of bone marrow in patients with pancytopenia. *J Pathol Nepal.* 2012 Sep 25;2(4):265–71.
- Pudasaini S, Prasad K, Rauniyar S, Shrestha R, Gautam K, Pathak R, et al. Interpretation of bone marrow aspiration in hematological disorder. *J Pathol Nepal.* 2012 Sep 25;2(4):309–12.
- Vaidya S. Evaluation of bone marrow in cases of pancytopenia in a tertiary care hospital. *J Pathol Nepal.* 2015;5(9):691–5.
- Saleh Yuguda, Ahmed Iya Girei, Kasim Mohammed Pindiga, Rufai Abdu Dachi1, Aliyu Ibrahim Lawan2 YMA. Indications and Diagnostic Utility of Bone Marrow Aspiration Cytology: A 12-year Experience at a Tertiary Health Center in Gombe, Northeastern Nigeria. *Ann Trop Pathol.* 2020;11(2):119–22.
- Dogan A, Demircioglu S. Diagnostic importance of bone marrow aspiration evaluation: A single-center study. *Pakistan J Med Sci.* 2022 Mar 1;38(4Part-II):811.
- Jha A, Sayami G, Adhikari RC, Panta AD, Jha R. Bone marrow examination in cases of pancytopenia. *J Nepal Med Assoc.* 2008;47(169):12–7.
- Donald S, Kakkar N. Dry tap on bone marrow aspiration: a red flag. *J Hematop.* 2021 Jun 1;14(2):125–30.
- Jalaeikhoo H, Kashfi SMH, Azimzadeh P, Narimani A, Gouhari Moghadam K, Rajaienejad M, et al. Acute Myeloid Leukemia as the Main Cause of Pancytopenia in Iranian Population. *Iran J Pathol.* 2017 Jun 1;12(3):265.
- Kumar V, Bhatia A, Madaan GB, Marwah S, Nigam AS. Role of bone marrow examination in the evaluation of infections: Clinico-hematological analysis in a tertiary care centre. *Turk Patoloji Derg.* 2020;36(1):17–22.
- Chang CY, Rajappan M, Zaid M, Ong ELC. Dengue fever complicated by hemophagocytic lymphohistiocytosis: Report of 2 cases and bone marrow findings. *Clin Case Reports.* 2020;8(12):3427–31.
- Heina N, Bergaraa GH, Moura NBV, Cardoso DM, Hirosea M, Ferronatoa AE et al. Dengue



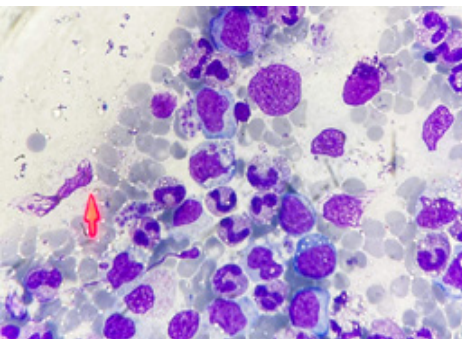
**Picture 1: Megaloblastic Anemia (Giemsa Stain, 1000x)**



**Picture 2: AML (Giemsa, 1000x)**



**Picture 3: LD bodies in Visceral Leishmaniasis (Giemsa 1000x)**



**Picture 4: Hemophagocytosis (Giemsa 1000x)**