

Normal Pituitary Gland Size and Morphology and Its Variations Related To Age and Gender: An MRI Evaluation

Jha A¹, Paudel N¹, Nepal S¹, Nayak R¹

ABSTRACT

Introduction: The pituitary gland is regarded as the master endocrine gland of the body. Subtle alterations in the size can cause significant changes to other endocrine glands and hormonal status. Magnetic Resonance Imaging (MRI) is the investigation of choice to examine pituitary gland. It is important to know the range of normal size and variations according to age and gender to enable radiologists to suggest what might be an abnormal pituitary gland. **Aim:** This study aims to examine normal size, volume and shape of pituitary gland and to establish a normal reference value for pituitary size in different age groups and genders. **Methods:** MRI Brain of 137 patients were studied retrospectively and patients with endocrinal abnormalities were excluded from the study. Images were acquired in General Electronics 1.5 Tesla MRI machine and mid-sagittal T1WI and coronal T2WI were selected for accurate measurement of the gland. Height, AP diameter, Transverse diameter, and volume were calculated for each individual and the collected data was categorized based on age and sex for analysis. Pearson's correlation test was done to establish a relation between age and volume of the gland and a p-value of <0.05 was considered as significant. **Results:** Our study included 137 patients (57 males, 80 females) with age ranging from 3 to 86 years. The study was divided into six age groups. Mean pituitary height, AP diameter, transverse diameter and volume of the gland were 6mm, 8.9mm, 12.3 mm, and 354.5 mm³ respectively. The gland observed a gradual increase in size up to the third decade and was more pronounced in the female population. A steady decline in the size of the gland was noted after 30 years for both populations. **Conclusion:** Good understanding of the normal size and shape of pituitary gland and its variation with age and gender is a must for every radiologist to compare with an abnormal increase in size.

Keywords: MRI, Normal, Pituitary gland

Authors:

1. Dr. Amit Jha
2. Dr. Nabin Paudel
3. Dr. Sabin Nepal
4. Dr. Rajesh Nayak

¹Department of Radiodiagnosis, Nepalgunj Medical College and Teaching Hospital, Kohalpur, Banke

Address for Correspondence:

Dr. Amit Jha
 Department of Radiodiagnosis
 Nepalgunj Medical College and Teaching Hospital
 Kohalpur, Banke, Nepal
 Email: amitjha52.aj@gmail.com

INTRODUCTION

Pituitary gland is a small gland located in pituitary fossa of sphenoid bone. This region has significant variations between normal individuals, including sphenoid sinus, size of sella including depth and size and shape of pituitary gland.^{1,2} It has been coined 'master gland' as it controls the activity of most other hormone-secreting glands. Before the advent of MRI, imaging of pituitary and hypothalamus region was done by plain radiographs and CT scan. Now MRI has been accepted as the investigation of choice to evaluate pituitary gland as there is a better delineation of the gland due to its resolution and as there is no harmful ionizing radiation involved. Depending on the hormonal status, the size of the gland changes. Usually,

large size of the gland is observed in pregnant/ lactating women and small size in child and older individuals. The size and shape of this gland varies with age, sex, and even race of the individual. Thus, a detailed assessment of pituitary gland is very important as findings sometimes can be very subtle. Generally, it is possible to differentiate normal from abnormal size, there exists an ambiguous region where it is difficult for a radiologist to say whether the size is normal or not. For this assessment, one should be aware of its normal size, anatomy, and physiological variations with age and gender of the individual. Various studies are done to evaluate dimensions and physiological variations of pituitary gland^{3,4}, however, there is paucity of such data on the dimensions of normal pituitary

gland in Nepali population. To the best of our knowledge only one similar study was carried out by Lamichhane et al, i.e., 'Age and gender related variations of pituitary gland size of healthy Nepalese people using magnetic resonance imaging'.⁵ This study showed the mean height, AP diameter, transverse diameter, and volume of normal pituitary gland, however shape of the gland and subjects below the age of 10 years were not included in this study. Furthermore, the dimensions were measured in 0.3T MRI of 6mm slice thickness where only axial sections were used, whereas for most accurate measurements T1 weighted thin sections in sagittal and coronal planes should be used. Therefore, this present study was conducted for accurate assessment of pituitary gland dimensions in various age groups of both genders and to procure normal standard reference values for various dimensions of pituitary gland in Nepali population.

METHODS

This is a retrospective observational study carried out in Nepalgunj Medical College, Kohalpur, Nepalgunj, Nepal. Patients without any significant brain pathology or endocrine disorder who had undergone MRI Brain in the department of Radiology, Kohalpur, between November 2019 to May 2020 were chosen for this study. The study group consisted of 137 patients (57 males, 80 females). Institution review committee clearance was obtained.

Patient selection:

All patients of any age group and gender sent for MRI Brain were selected for this study with the following exclusion criteria.

Exclusion criteria

- Subjects with pituitary diseases in past or present.
- Subjects who received in past or receiving at present, hormonal therapy, including thyroxin, gonadal steroids, and adrenal steroids (except use of corticosteroid for <7 days before current MRI, and not prescribed for adrenal insufficiency)
- Subjects with history of any psychiatric disorder or receiving antipsychotic drug
- Subjects with history of intracranial surgery
- Subjects who were pregnant or in within 2 weeks of post-partum
- Subjects with structural abnormality of pituitary gland such as empty sella, cyst, microadenoma, etc.

The patients included in this study were divided into six age groups (1 to 10 years, 11 to 20 years, 21 to 30 years, 31 to 40 years, 41 to 50 years, 51 years and above) for both genders.

MRI sequences were performed using General Electronics MRI 1.5 Tesla scanner. Sequence parameters included matrix

352x256, FOV 230mm and 5mm slice thickness. The coronal and sagittal views were taken using the midline plane of both T1-weighted sagittal spin-echo and T2- weighted coronal spin-echo images. The mid-sagittal section was defined by visualization of the anterior and posterior pituitary gland with pituitary stalk in the same slice.

All the measurements were done in T1 weighted mid sagittal and T2 weighted coronal images (Figure 1 and 2). Vertical height (craniocaudal), anteroposterior (AP) diameter, transverse (TR) diameter was measured and volume was calculated using the formula $V = AP \text{ dimension} \times TR \text{ dimension} \times CC \text{ dimension} \times 0.52$. This formula was derived from the sphere volume equation coefficient and cubic volume calculation: $(4/3\pi) (r^3) / (2r)^3 = 3.1416/6 = 0.52$. Height, AP and TR diameter were expressed in mm and volume in mm^3 . The shape of superior surface of the gland was observed to be concave, flat and convex.

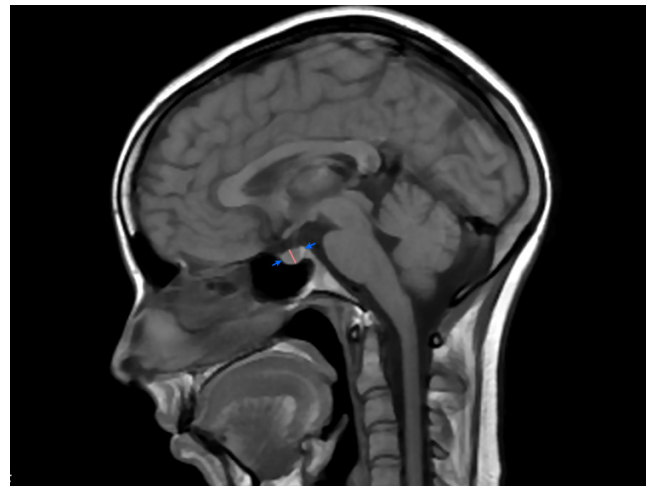


Figure 1 : Mid-sagittal T1WI at the level of stalk shows normal pituitary gland. The arrows represent the length (AP) and the central line represents the normal height (CC) of the gland

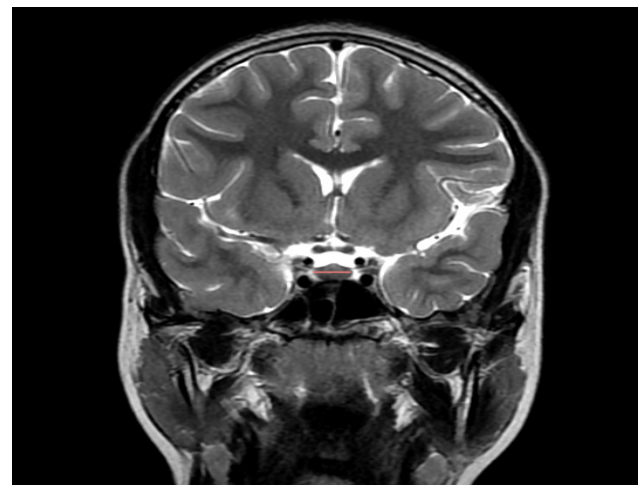


Figure 2 : Coronal T2WI image shows a central line which represents normal width (TR) of the gland. Also noted is superior convex surface of the gland

Statistical analysis

Statistical calculations were done using statistical package for the social sciences (SPSS). Mean and Standard deviations of pituitary gland height, AP and TR diameter were calculated in mm. Volume in different age groups was calculated in the scale of mm³. The relationship between pituitary gland volume with age was examined statistically using Pearson’s correlation while gender differences were evaluated using the Student’s t-test. P-value of <0.05 was considered significant.

RESULTS

Pituitary gland dimensions of 137 patients within the inclusion criteria were measured out of which 57 were male (42%) and 80 females (58%). The age of the patients ranged from 3 years to 86 years. The mean pituitary gland height in our study group was 6 ± 1.3mm and the mean volume was 354.59± 128.25 mm³. Mean height and volume for male were 5.53±1.06mm and 314.54±106.8 mm³ and for female were 6.33±1.38mm and 382.95±135.13 mm³ respectively. Mean height, AP diameter, transverse diameter, and volume of the gland according to different age groups are listed in table I.

Age group	Mean height in mm (SD)	Mean AP diameter in mm (SD)	Mean transverse diameter in mm (SD)	Mean volume in mm ³
1-10	3.6±0.6	6.8±0.9	9.9±1.2	126.1±28.1
11-20	6.4±0.9	8.5±1.2	12.3±1.4	357.3±96.2
21-30	6.7±1.2	9.3±0.9	13.±1.6	432.9±135.3
31-40	6.1±0.9	9.4±0.9	12.3±1.3	372.4±90.0
41-50	5.5±1	9.3±1.3	12.2±1.3	332.6±107.4
Above 50 years	4.9±0.9	8.4±1.3	11.9±1.8	259.6±77.6

Table I : Mean value of pituitary gland height and volume in different age groups

The mean value of pituitary gland dimensions and volume in different age group and both the sexes are given in the Table II and the relationship between age and pituitary gland volume in both sexes are demonstrated in Figure 3.

Age	Sex	Mean height in mm (SD)	Mean AP diameter in mm (SD)	Mean transverse diameter in mm (SD)	Mean volume in mm ³
1-10 years	Male	3.3±0.6	6.3±0.5	9.7±1.7	105.5±14.4
	Female	3.9±0.7	7.4±1	10.2±10.7	153.4±9.3
11-20 years	Male	5.9±0.9	8.8±1.3	12.5±1.5	350.2±107.6
	Female	6.6±0.9	8.4±1.2	12.2±1.4	361.2±92
21-30 years	Male	5.9±0.6	9.3±0.7	12.7±1.3	364±53.3
	Female	7.1±1.3	9.4±1.1	13.2±1.7	467.4±150.9
31-40 years	Male	5.8±0.8	9.1±1.3	12±1.18	334.8±89
	Female	6.3±0.9	9.6±0.5	12.5±1.4	398.2±83.8

41-50 years	Male	5.3±1.2	9.2±1.7	11.9±1.7	312.3±128
	Female	5.7±0.9	9.3±0.7	12.5±0.8	355.7±81.3
Above 50 years	Male	5.3±0.8	8.7±1.5	11.5±2.2	273.8±76.2
	Female	4.4±0.9	8.2±0.9	12.5±1	241.9±80.5

Table II. Mean value of pituitary gland height and volume in different age group and in both sexes

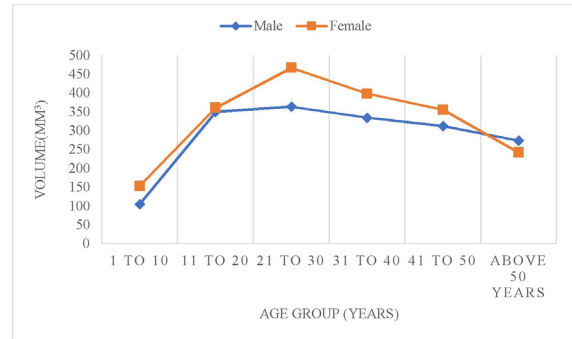

Figure 3 : Relationship between age and pituitary gland volume

Superior surface of the gland was categorized as concave surface, flat surface and convex surface. Superior flat surface was observed in 50 patients whereas the surface was concave in 44 and convex in 40 patients. Concave surface was mostly observed in patients <10 years of age and >50 years of age, while young adults showed mostly flat and convex surface. Pituitary volume was largest in age group 21 to 30 for both males and females. The lowest values recorded were in age group <10 years followed by above 50 years of age. Pituitary height and volume correlated negatively for age (p=0.161).

DISCUSSION

MRI is the preferred examination to visualize pituitary gland and the radiologist must be aware of the normal size and volume of the gland and the variations related to age and gender as small changes in the size of the gland could have a considerable effect on other neuro-endocrine glands. Borderline pituitary abnormalities are frequently encountered such as small microadenoma, physiological alterations of the gland and inflammatory diseases but there is a constant dilemma for the radiologists to report such cases. Although there are many works of literatures on normal size and variations of the gland abroad, there is a scarcity of such literatures in Nepal. This study was designed to recognize the normal size and volume of pituitary gland and its variations with age and sex in Nepali population.

Our study showed there was a linear increase in pituitary dimensions and volume up to 30 years of age in both sexes, after which a gradual decrease in size and volume was observed. This finding is consistent with a study conducted by Ibinaiye et al.⁶

Our study showed the mean height and volume of the gland to be 6 ±1.3mm and 354.59± 128.25 mm³ respectively which

is partly comparable to the study performed by Lamichhane et al.⁵ In contrast to their study, the mean volume of the gland in our study was much less as patients less than 10 years of age were not included in their study and our study shows the mean volume of the gland of patients below 10 years to be only 128mm³. Concave superior surface was mostly observed in children below 10 years of age and adults above 50 years of age. Superior surface in most of the cases was flat. A sudden increase in the volume of the gland during puberty is a well-known fact.⁷⁻⁹ Similarly, in our study we found the maximum size of the gland to be in pubertal females. Studies done previously suggest that changes in the morphology of the gland are due to the hormone levels. The above-mentioned increase in pituitary height during puberty can be related to the increased production of Luteinizing Hormone (LH) during this time of growth. The decreased in the pituitary height with age also shows the changes in the endocrine status with aging and also physiological atrophy of the pituitary gland.⁴

Furthermore, we also observed that among the parameters that we studied including height, AP diameter, TR diameter and volume, pituitary gland height changed most remarkably with respect to age and sex. This is in partial agreement with the belief that mid-sagittal height of the pituitary gland reflects the variation in pituitary morphology more accurately.^{6,10}

Some of the previous studies^{4,6} show a second surge in pituitary height in the fifth decade of life which is more pronounced in females but was not observed in our study. Correlation between age and volume of the gland was non-significant in accordance with previous studies.^{6,11}

LIMITATION

Since this was a hospital-based study from a single-center, its findings may not apply to all populations and the fact that since MRI is an expensive study there was a selection bias as normal volunteers declined for this study.

CONCLUSION

MRI is the best modality for assessing the size and shape of pituitary gland. This study provides the normal range of pituitary dimensions and volume and its variation according to age and gender among Nepali population. The maximum size of the gland was observed in the second decade and a large size was more pronounced in the female population. The data collected may be used for future larger studies regarding the normal pituitary gland. Maximum height and volume are observed in puberty and a decrease in gland size reflect physiological atrophy of the gland with age.

REFERENCES

1. Chaudhary, V., & Bano, S. 2011. Imaging of the pituitary: Recent advances. *Indian journal of endocrinology and metabolism*, 15 Suppl 3(Suppl3), S216–S223.
2. Elster Imaging of the sella: anatomy and pathology. *Seminars in ultrasound, CT, and MR*, 1993;14(3):182-194
3. Ikram, M. F., Sajjad, Z., Shokh, I., & Omair, A. Pituitary height on magnetic resonance imaging observation of age and sex related changes. *The Journal of the Pakistan Medical Association*. 2008;58(5):261-65
4. Yadav, P. Singhal, S. Chauhan, S. Harit, S. MRI Evaluation of Size and Shape of Normal Pituitary Gland: Age and Sex Related Changes 2017; 11(12), TC01-TC04 Available from <https://www.doi.org/10.7860/JCDR/2017/31034/10933>
5. Tika Ram Lamichhane, Susheel Pangei, Sharma Paudel, Hari Prasad Lamichhane, Age and Gender Related Variations of Pituitary Gland Size of Healthy Nepalese People Using Magnetic Resonance Imaging, *American Journal of Biomedical Engineering*. 2015; 5(4): 130-5.
6. Ibinaiye, P. O., Olarinoye-Akorede, S., Kajogbola, O., & Bakari, A. G. Magnetic Resonance Imaging Determination of Normal Pituitary Gland Dimensions in Zaria, Northwest Nigerian Population. *Journal of clinical imaging science*. 2015;5(1):1-6
7. Suzuki, M., Takashima, T., Kadoya, M., Konishi, H., Kameyama, T., Yoshikawa, J., Gabata, T., Arai, K., Tamura, S., & Yamamoto, T. Height of normal pituitary gland on MR imaging: age and sex differentiation. *Journal of computer assisted tomography*, 1990; 14(1):36-9.
8. Elster, A. D., Chen, M. Y., Williams, D. W., 3rd, & Key, L. L. Pituitary gland: MR imaging of physiologic hypertrophy in adolescence. *Radiology*, 1990;174(3):681-85
9. Doraiswamy, P. M., Potts, J. M., Axelson, D. A., Husain, M. M., Lurie, S. N., Na, C., Escalona, P. R., McDonald, W. M., Figiel, G. S., & Ellinwood, E. H., Jr. MR assessment of pituitary gland morphology in healthy volunteers: age- and gender-related differences. *AJNR. American journal of neuroradiology*. 1992; 13(5):1295-99.
10. Hayakawa, K., Konishi, Y., Matsuda, T., Kuriyama, M., Konishi, K., Yamashita, K., Okumura, R., & Hamanaka, D. Development and aging of brain midline structures: Assessment with MR imaging. *Radiology*. 1989; 172(1), 171–7.
11. Lurie, S. N., Doraiswamy, P. M., Husain, M. M., Boyko, O. B., Ellinwood, E. H., Jr, Figiel, G. S., & Krishnan, K. R. In vivo assessment of pituitary gland volume with magnetic resonance imaging: the effect of age. *The Journal of clinical endocrinology and metabolism*. 1990; 71(2), 505–8.