

# Mild Encephalopathy with Reversible Splenic Lesions in an Infant with COVID-19

Natsuki Yagi<sup>1</sup>, Ryo Sugitate<sup>1</sup>, Mariko Shimizu<sup>1</sup>, Tomomi Ogata<sup>2</sup>, Atsushi Matsui<sup>1</sup>

<sup>1</sup> Department of Paediatrics, Japanese Red Cross Maebashi Hospital, 389-1 Asakuramachi, Maebashi, Gunma 371-0811, Japan.

<sup>2</sup> Department of Paediatrics, Gunma University Graduate School of Medicine, Chome - 39-22 Showamachi, Maebashi, Gunma 371-0034, Japan.

## Article History

Received On – 2023 Jan 31

Accepted On – 2023 Jul 04

**Funding sources:** none

**Conflict of Interest:** None

## Keywords:

acute encephalopathy; MERS; Omicron variant; SARS-CoV2; seizure

## Online Access



DOI: 10.60086/jnps498

## Corresponding Author

Ryo Sugitate,  
Department of Paediatrics,  
Japanese Red Cross Maebashi Hospital,  
389-1 Asakura-machi,  
Maebashi, Gunma 371-0811, Japan.  
E-mail:sugitate26@gmail.com

## Abstract

There have been few reports of mild encephalopathy with reversible splenic lesions (MERS) associated with COVID-19 in infants. Here, we present a case of MERS in a 23-month-old infant with COVID-19 in Japan during the Omicron variant epidemic. The increase in COVID-19 acute encephalopathy in infants, including those with MERS, should be considered in the future due to the prevalence of the Omicron variant strain. Meanwhile, whether the cause is COVID-19, acute encephalopathy with a lesion localized in the splenium of the corpus callosum can be treated with temporary anticonvulsant therapy, as is generally the case with MERS.

## Introduction

Acute encephalopathy (AE) is among the most serious complications of infectious diseases in children, the severity and prognosis of which depend on the type of AE. Among acute encephalopathies, mild encephalopathy with reversible splenic lesions (MERS) is characterized by hypodiffusion lesions detected using magnetic resonance imaging (MRI) that are primarily confined to the splenium of the corpus callosum, are reversible, and disappear without brain atrophy.<sup>1</sup> Although case reports of novel corona virus disease-2019 (COVID-19) associated MERS have emerged,<sup>2</sup> only a few reports of MERS in children with COVID-19 have been published, especially those involving infants. Here, we report a case of COVID-19-associated MERS in a 23-month-old Japanese female patient during the Omicron variant epidemic.

## Case Report

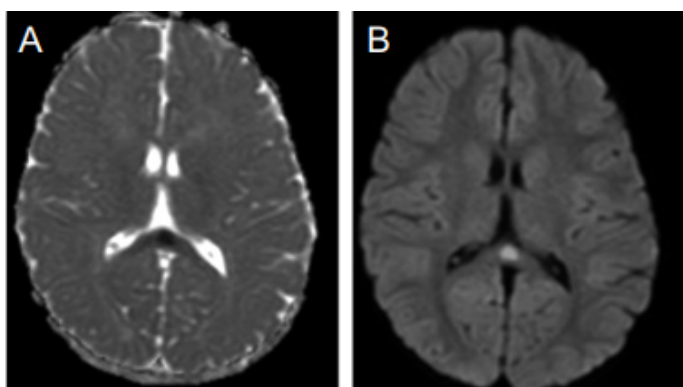
The patient, a 23-month-old Japanese female infant, had no perinatal abnormalities, developmental abnormalities, history of seizures, or family history and was unvaccinated against severe acute respiratory syndrome coronavirus 2 (SARS-CoV-2). Two days prior to admission, the patient had developed fever of approximately 39°C, and the SARS-CoV-2 polymerase chain reaction (PCR) test performed on a nasopharyngeal swab was positive. On third day, although her fever resolved to 37°C, she was rushed to the hospital due to status epilepticus. The patient exhibited three minutes of limb weakness with supination of the eyeballs and cyanosis, followed by 30 min of fixation of the eyeballs in the midline position and failure to respond to call. She had 15

This work is licensed under a Creative Commons Attribution-NonCommercial 4.0 International (CC BY-NC 4.0)



minutes of a generalized tonic–clonic seizure (GTCS). The seizure was aborted through buccal mucosa administration of 2.5 mg midazolam. Blood tests revealed no electrolyte abnormalities or hypoglycemia, and cerebrospinal fluid (CSF) analysis revealed normal findings. Moreover, CSF analysis using a multiplex PCR system for microbial detection provided unremarkable results. MRI showed reduced diffusion localized to the splenium of the corpus callosum (Fig. 1a, 1b). Two hours after the seizure was aborted using midazolam, the patient experienced another two minute GTCS and was infused with continuous intravenous midazolam. Although the seizure did not recur, the patient remained in a dazed state; therefore, midazolam was discontinued. Fosphenytoin was then initiated on fourth day, after which the patient remained conscious and exhibited no other neurological abnormalities. Although fosphenytoin was discontinued on seventh day and the patient was clinically stable, she was kept isolated in a private room in the COVID-19 ward until day 11. The electroencephalogram (EEG) machine could not be used during the hospitalization period to prevent nosocomial infection; thus, EEG findings were not obtained during the acute phase of the patient's illness. After discharge, EEG findings on day 14 and MRI on day 15 were unremarkable.

Fig. 1. Magnetic resonance imaging findings



MRI, magnetic resonance imaging; ADC, apparent diffusion coefficient; DWI, diffusion-weighted imaging

## Discussion

The frequency of AE in patients with COVID-19 is unknown. However, the frequency of febrile seizures has been reported to be higher in the Omicron variant of COVID-19 than in its Delta variant.<sup>3</sup> Thus, the Omicron variant may be prone to induce seizures; however, the detailed pathogenesis is unknown, including whether it invades nerve cells. Our

patient was diagnosed with MERS, which is the second most common pediatric acute encephalopathy in Japan after AE with biphasic seizures and late reduced diffusion.<sup>4</sup> However, the incidence of AE in COVID-19 and which type of encephalopathy is more common remain unclear, and further case accumulation is required.

The median age of the 29 cases of COVID-19-associated MERS reviewed by Kubo et al<sup>2</sup> was 40 years, with the lowest being 10 years. The patient in the current study was < 2 years old, and to the best of our knowledge, no cases of COVID-19-associated MERS in patients < 3 years of age have been reported in the literature as of January 30, 2023. Additionally, the average age of onset of MERS in Japan is approximately 5 years.<sup>5</sup> As COVID-19 becomes a more common disease, the number of complicated cases of COVID-19 - associated AE in younger children is expected to increase. Therefore, AE and MERS should be considered in younger children with COVID-19 - associated seizures.

Moreover, the present case suggests that AE with COVID-19 associated lesions of the splenium of the corpus callosum has a favorable prognosis similar to that of MERS. Various treatments have been attempted for acute encephalopathy, including intravenous corticosteroids, intravenous immunoglobulin, and hypothermia; however, with the exception of anticonvulsants for status epilepticus, no treatment with a high level of evidence has been established.<sup>6</sup> Although COVID-19 has been widely treated with steroids for infection-associated cytokine storms,<sup>7</sup> only conservative treatments such as temporary anticonvulsant therapy may be indicated in possible cases of MERS or AE with a lesion localized in the splenium of the corpus callosum.

## Conclusions

The number of MERS cases in infants with COVID-19 is expected to increase in the future due to the prevalence of the Omicron variant strain. However, MERS in COVID-19 is considered to have a good prognosis, as is MERS due to other causes; hence, conservative treatments such as temporary anticonvulsants alone may be sufficient to treat the disease.

## Acknowledgement

We thank the patient and her parents for providing their consent to publish this case report.

## References

1. Takanashi J. Two newly proposed infectious encephalitis/encephalopathy syndromes. *Brain Dev.* 2009;31:521-8.  
DOI: 10.1016/j.braindev.2009.02.012.
2. Kubo M, Kubo K, Kobayashi KI, Komiya N. Non-severe COVID-19 complicated by cytotoxic lesions of the corpus callosum (mild encephalitis/encephalopathy with a reversible splenial lesion): a case report and literature review. *Int J Infect Dis.* 2022;125:1-9.  
DOI:10.1016/j.ijid.2022.09.009
3. Iijima H, Kubota M, Ogimi C. Change in seizure incidence in febrile children with COVID-19 in the era of Omicron variant of concern. *J Pediatric Infect Dis Soc.* 2022;11:514-7. DOI:10.1093/jpids/piac085.
4. Kasai M, Shibata A, Hoshino A, Maegaki Y, Yamanouchi H, Takanashi J, et al. Epidemiological changes of acute encephalopathy in Japan based on national surveillance for 2014-2017. *Brain Dev* 2020;42:508-14.  
DOI: 10.1016/j.braindev.2020.04.006
5. Hoshino A, Saitoh M, Oka A, Okumura A, Kubota M, Saito Y, et al. Epidemiology of acute encephalopathy in Japan, with emphasis on the association of viruses and syndromes. *Brain Dev* 2012;34:337-43.  
DOI: 10.1016/j.braindev.2011.07.012.
6. Mizuguchi M, Ichiyama T, Imataka G, Okumura A, Goto T, Sakuma H, et al. Guidelines for the diagnosis and treatment of acute encephalopathy in childhood. *Brain Dev.* 2021;43:2-31.  
DOI: 10.1016/j.braindev.2020.08.001
7. Namazi N. The effectiveness of dexamethasone as a combination therapy for COVID-19. *Acta Pharm.* 2022;72:345-58.  
DOI: 10.2478/acph-2022-0030.