

ISSN: 2091-2749 (Print)  
2091-2757 (Online)

Submitted on: 1 Aug 2024  
Accepted on: 13 Aug 2024

<https://doi.org/10.3126/jpahs.v11i2.71699>

## Diagnostic accuracy of ultrasonography and mammography of breast lesions

Shreejana Shrestha<sup>1</sup>, Yogita Manandhar Dwa<sup>2</sup>, Pooja Jaiswal<sup>1</sup>, Prabhat Karki<sup>3</sup>, Sudeep KC<sup>3</sup>, Uday Raj Banjade<sup>3</sup>

<sup>1</sup>Assoc. Prof., <sup>2</sup>Asst. Prof., <sup>3</sup>Lecturer, Dept. of Radiology & Imaging, Patan Hospital, Patan Academy of Health Sciences, Lalitpur, Nepal

### Abstract

**Introduction:** Breast cancer is the most common malignant tumours in women, with over one million cases diagnosed globally each year, resulting in approximately 410,000 deaths. Early detection and treatment significantly reduce the risk of mortality. Ultrasound and mammography are widely used non-invasive, cost-effective imaging techniques for early breast cancer diagnosis. This study aims to identify the characteristics of breast lesions on ultrasound and mammography and correlate them with histological findings.

**Method:** This was a retrospective study conducted in Patan Hospital, with the data set from January 2019 to December 2022. All patient's data were collected regarding findings of ultrasound, mammography, BIRADS from radiological department and correlated with histopathological diagnosis. All findings were compared for the sensitivity and specificity of mammography with ultrasonography in diagnosing breast lesions.

**Result:** A total of 137 cases were found to have histopathology diagnosed benign and malignant breast lesions. Ultrasonography showed 91.58% sensitivity, 57.14% specificity, 82.86% positive predictive value, 75.00% negative predictive value, and 81.02% diagnostic accuracy. Mammography exhibited 92.63% sensitivity, 61.90% specificity, 84.62% positive predictive value, 78.79% negative predictive value, and 83.62% diagnostic accuracy. When combining mammography and ultrasonography, the results showed 93.63% sensitivity, 42.86% specificity, 78.76% positive predictive value, 75% negative predictive value, and 78.10% diagnostic accuracy.

**Conclusion:** Ultrasound and mammography are both highly sensitive in detecting benign and malignant breast lesions. While mammography has a slightly higher overall accuracy in diagnosis, it is recommended to complement ultrasonography with mammography for a more comprehensive detection of breast lesions.

**Keywords:** Breast neoplasm; Histopathology; Mammography; Ultrasound



**How to Cite:** Shrestha S, Manandhar Dwa Y, Jaiswal P, Karki P, KC S, Banjade UR. Diagnostic accuracy of ultrasonography and mammography of breast lesions. Journal of Patan Academy of Health Sciences. 2024 Aug;11(2):51-58.

**Correspondence:** Dr. Shreejana Shrestha, Dept. of Radiology & Imaging, Patan Hospital, Patan Academy of Health Sciences, Lalitpur, Nepal, **Email:** shreejanashrestha@pahs.edu.np

## Introduction

Breast cancer is the most common malignant tumour in women. Globally there are more than one million cases of breast cancer diagnosed each year<sup>1</sup> and approximately 410,000 of them died from breast cancer.<sup>1,2</sup> Early diagnosis and early treatment cause low risk of mortality. Most people seek for medical treatment at late stage of disease due to lack of knowledge and awareness-causing increased risk of mortality and morbidity.<sup>3</sup> Ultrasound and mammography are the most common cost effective and feasible modalities for early diagnosis of breast cancer. Breast cancer is the most common cancer in Nepal with age standardized incidence rate of 15.24 per 100,000 and the commonest in urban women aged 41-50 accounting for 15% of cancer in Nepal, many (60-70%) being diagnosed at advanced stage.<sup>4</sup> In India it is the second most common cause of cancer related mortality. Breast masses range from inflammatory, benign to malignant lesion.<sup>5</sup>

Ultrasonography and mammography are the most common non-invasive imaging modalities used in characterization of breast lesion. Mammography is cost effective and widely accepted to evaluate the clinically suspicious and for screening of breast cancer. Ultrasonography is a useful adjunctive modality and helps characterizing a mammographically non-detected palpable abnormality, especially in dense breast. With the use of ultrasound, mammography and Fine needle aspiration cytology (FNAC) can diagnose both benign and malignant lesion without surgery. Sensitivity and specificity of ultrasonography or mammography is higher if ultrasonography and mammography are both combined in diagnosis of breast lesion.<sup>6,7</sup> The aim of this study was to determine the characteristics of breast lesions on ultrasonography and mammography and correlate them with histology findings.

## Method

This cross-sectional study was done in Radiology and Imaging Department and Department of Pathology of Patan Hospital, with the data set of 4 years (from January 2019 to December 2022). All patients were referred for breast lesions from concerned departments and their ultrasound was performed using 7.5 to 10 MHz linear array transducer of Philips SD 40 machine. Mammography was done using a digital mammography with a Kilovoltage Peak (kVp) setting of 25-35 for average size and density breasts with focal spot of 0.3mm using a target and filter of Molybdenum. Cranio-caudal (CC) and Medio-lateral (ML) views of both the breasts were done after

adequate compression. All patients had BIRADS score data from the mentioned imaging findings.<sup>7</sup>

Approval of the study were obtained from the Institutional Review Committee (IRC) of PAHS (Ref. drs2401121831). This study included breast lesions who had ultrasound scan, mammography scan and histopathological report available and excluded the cases that had ultrasound scan only or mammography only. Based on specificity from a study from India 2020, the sample size calculated which were 129 for this study.<sup>6</sup>

FNAC of the lesion and the histopathological report assessment were classified as "Benign" and "Malignant" lesions by the pathology department. Breast lesions were categorized as "Benign" and "Malignant" using pre-determined Breast Imaging Reporting and Data System (BIRADS) score for ultrasonography and mammography findings by the study team members. These categorical variables were used to find association between ultrasonography and FNAC, mammography and FNAC and ultrasonography + mammography and FNAC using chi-square test. Finally, sensitivity and specificity along with positive predicted value and negative predicted value of each cross-tabulations were calculated. Data were entered in Microsoft Excel 2016 software and analysed using Statistical Package of Social Sciences (SPSS 20) software.

## Result

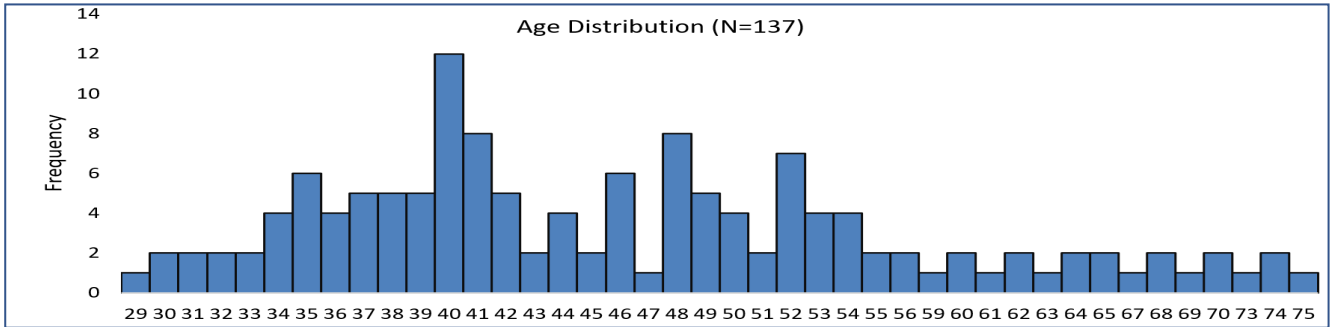
Total number of 278 cases who had both ultrasound and mammography studies in last four years were included in our study. Out of 278 cases, only 137 (49.28%) had histopathological diagnosis of either benign or malignant lesion. Out of 137, majority were benign cases 95 (69.34%) and rest were malignant 42 (30.66%). In this study, in ultrasound, out of 137 cases, 132 (96.35%) cases were diagnosed by ultrasound and 5 (3.64%) cases were normal or negative for lesion which were benign lesion whereas in mammography 119 (86.86%) cases were diagnosed by mammography and 18 (13.14%) cases were normal or negative for lesion. Among these 18 cases, 17 (94.4%) were benign and 1 (5.56%) was malignant. Out of 42 malignant lesions, 4 (9.52%) cases were of women below 40 years and 38 (90.48%) cases were of women above and equal 40 years, Table 1.

The histogram shows that the age was not normally distributed, which was also confirmed by the Kolmogorov-Smirnov test of normality (Test value = 0.122, p-value < 0.001). Thus, median age of women in this study was 44 years with IQR (interquartile range)

**Table 1. Table showing age group distribution and histopathologic examination findings (N=137)**

Age group in years	HPE Findings		Total N
	Benign	Malignant	
29-39	34(89.47%)	4(10.52%)	38
40-49	35(66.04%)	18(33.96%)	53
50-59	16(61.54%)	10(38.46%)	26
60-69	6(42.85%)	8(57.14%)	14
70+	4(66.67%)	2(33.33%)	6
<b>Total</b>	<b>95(69.34%)</b>	<b>42(30.66%)</b>	<b>137</b>

was 13 years (44±13). For benign lesion, median age was 43 years and IQR was 14 years and for malignant lesion median age was 48 years and IQR was 16 years. Minimum age was 29 years and maximum age was 75 years with most of the patients at 40 to 49 years that is 53(38.88%); 117(85.40%) of cases were below 60 years and only 20(14.60%)patients were above 60 years.



**Figure 1. Age distribution (N=137)**

**Table 2. Distribution of ultrasonography findings**

Natures of lesions	N (%)	Benign	Malignant	N	Chi square test
<b>Shape:</b>					
Round	108(67.08%)	77	7	84	
Oval	15(9.32%)	4	6	10	<.0001
Irregular	38(23.60%)	10	28	38	
<b>Orientation:</b>					
Parallel	119(73.91%)	79	13	92	<.0001
Non Parallel	42(26.09%)	12	28	40	
<b>Margin:</b>					
Circumscribed	138(85.71%)	89	22	111	<.0001
Not circumscribed	23(14.29%)	2	19	21	
<b>Boundary:</b>					
Halo	129(80.12%)	83	18	101	<.0001
Abrupt	32(19.88%)	8	23	31	
<b>Echo pattern</b>					
Hypoechoic	144(89.44%)	86	32	118	<.001
Isoechoic	7(4.35%)	2	3	5	
Hyperechoic	4(2.48%)	3	0	3	
Complex	6(3.73%)	0	6	6	
<b>Posterior Acoustic:</b>					
Enhancement	119(73.91%)	78	15	93	<.0001
Shadowing	42(26.09%)	13	26	39	
<b>Calcification:</b>					
Present	36(22.3%)	12	20	32	<.0001
Absent	126(77.8%)	80	21	101	
<b>BIRADS categories:</b>					
1	117(42.09%)	6	0	6	<.0001
2	79(28.42%)	54	1	55	
3	30(10.49%)	20	6	26	
4a	19(6.83%)	7	11	18	
4b	8(2.88%)	3	5	8	
4c	12(4.32%)	3	8	11	
5	13(4.68%)	2	11	13	

Table 3. Distribution of mammography findings

Natures of lesion	N(%)	Benign	Malignant	N	Chi-square test
<b>Composition</b>	<b>278</b>				
A	42(15.1%)	10	7	17	
B	180(50.4%)	44	19	63	0.350*
C	84(30.2%)	35	16	51	
D	12(4.3%)	6	0	6	
<b>Shape:</b>					
Round	22(20%)	12	3	15	<.0001
Oval	23(57.3%)	42	14	56	
Lobulated	20(18.2%)	4	15	19	
Irregular	5(4.5%)	1	4	5	
<b>Margin:</b>					
Indistinct	21(18.9%)	5	15	20	<.0001
Spiculated	13(11.7%)	4	8	12	
Microlobulated	73(65.8%)	49	11	60	
Circumscribed	4(3.6%)	2	22	24	
<b>Calcification:</b>					
Absent	183(65.8%)	65	17	82	<.0001
Micro	71(25.5%)	26	8	34	
Macro	24(8.6%)	4	17	21	
<b>Skin/Nipple retraction:</b>					
Present	31(11.2%)	7	14	21	<.0001
Absent	247(88.8%)	88	28	116	
<b>Axillary Lymphadenopathy:</b>					
Present	69(24.8%)	14	16	30	0.002
Absent	209(75.5%)	81	26	107	
<b>Architectural distortion:</b>					
Present	21(7.6%)	4	10	14	<.0001
Absent	257(92.4%)	91	32	123	
<b>BIRADS categories:</b>					
0	1(0.4%)	0	0	0	<.0001
1	76(27.3%)	17	1	18	
2	110(39.6%)	43	1	44	
3	41(14.7%)	25	3	28	
4a	15(5.4%)	3	11	14	
4b	12(4.3%)	3	9	12	
4c	6(2.2%)	2	4	6	
5	17(6.1%)	2	13	15	

Note: \* = Fisher's exact test

Table 4. Comparison of ultrasound and mammogram findings of breast lesions with FNAC findings

Diagnosis	Histopathology				Results		Diagnostic Accuracy
	Benign	Malignant	Sensitivity	Specificity	Positive predictive value	Negative predictive value	
<b>Ultrasound</b>							
Benign	87	18	91.58%	57.14%	82.86%	75%	81.02%
Malignant	8	24					
<b>Mammography</b>							
Benign	88	16	92.63%	61.90%	84.62%	78.79%	83.21%
Malignant	7	26					
<b>USG+Mammography</b>							
Benign	89	24	93.68%	42.86%	78.76%	75%	78.10%
Malignant	6	18					

There were no malignant lesions below 35 years. Out of 137 cases that underwent both ultrasound and histopathologic examination, 132(96.35%) were diagnosed by ultrasound and 5(4.81%) were normal or negative for lesion that was BIRADS 1 score. All 6 cases were benign lesion. In comparison, 119(86.86%) were diagnosed by mammography and 18(13.14%) was normal or negative for lesion that was BIRADS 1 score. Among these 18 cases, 17(94.44%) was benign and 1(5.56%) was malignant, Table 2.

Ultrasound findings revealed that a considerable number of malignant lesions displayed irregular shape, non-parallel orientation, non-circumscribed margins, abrupt margins, calcification, posterior acoustic shadow, and complex echotexture, with a statistically significant p-value of <0.0001. Conversely, a notable number of benign lesions exhibited round shape, parallel orientation, well-circumscribed margins, hypoechoic halo, hypoechoic features, and posterior acoustic enhancement, also with a statistically significant p-value of <0.0001.

The correlation between Ultrasound BIRADS score and histopathological findings of patients is presented in Table 2, showing a statistically significant relationship with a p-value of <0.0001. As the BIRADS score increases, the likelihood of malignant lesions also increases. Among the cases, one out of 55 cases with a BIRADS 2 score and six out of 26 cases with a BIRADS 3 score were found to have malignant lesions. The majority of cases with BIRADS 4 and 5 scores were associated with malignant lesions. Specifically, out of 37 cases with a BIRADS 4 score, 13(35.14%) cases were benign lesions and 24(64.86%) cases were malignant lesions. For the 13 cases with a BIRADS 5 score, only 2(15.38%) were benign lesions while 11(84.62%) were malignant lesions.

On mammography, breast composition was not found to be statistically significant ( $p=0.350$ ). A considerable number of malignant lesions exhibited lobulated and irregular shapes, while benign lesions displayed round and oval shapes. The majority of malignant lesions showed indistinct, speculated, and circumscribed margins, whereas benign lesions had microlobulation which was statistically significant ( $p<0.0001$ ). Benign lesions mostly lacked calcification or microcalcification, whereas malignant lesions had macrocalcification with a statistically significant p value of <0.0001. Malignant cases presented with skin/nipple retraction and architecture destruction, which were absent in benign cases, showing statistical significance of <0.0001. The majority of benign lesions did not have axillary lymphadenopathy, while malignant lesions did, with a statistically significant p value of 0.002(<0.05), Table 3.

The correlation between Mammography BIRADS score and histopathological findings was found to be statistically significant ( $p<0.0001$ ). Among the cases, one out of 44 BIRADS 2 scores and three out of 28 BIRADS 3 scores were identified as malignant lesions. The majority of BIRADS 4 and 5 scores were associated with malignant lesions. Specifically, out of 32 BIRADS 4 cases, 8(25%) were benign lesions and 24(87.5%) were malignant. For BIRADS 5 cases, only two out of 15 were benign, while the rest were malignant.

The diagnostic accuracy of mammography and ultrasound in detecting breast lesions, particularly BIRADS 4 and 5 scores, was found to be very good in our study. Out of 42 cases of malignant lesions, mammography detected 37(88.09%) and ultrasound detected 35(83.33%). For BIRADS 1 to 3 scores, out of 95 cases, mammography detected 85(89.47%) benign cases and ultrasound detected 80(84.21%).

Ultrasonography demonstrated a sensitivity of 91.58% and a specificity of 57.14%, with a positive predictive value of 82.86% and a negative predictive value of 75.00%. The diagnostic accuracy of ultrasonography was 81.02%. Mammography showed a sensitivity of 92.63% and a specificity of 61.9%, with a positive predictive value of 84.62% and a negative predictive value of 78.79%. The diagnostic accuracy of mammography was 83.21%. When combining mammography and ultrasonography, the sensitivity and specificity were 93.63% and 42.86% respectively, with a positive predictive value of 78.76% and a negative predictive value of 75.00%, and a diagnostic accuracy of 78.10%, Table 4.

Out of 42 cases of malignant lesions ultrasound had correctly diagnosed 24(57.14%) cases and mammography had correctly diagnosed 26(61.90%) cases. On combining both ultrasound and mammography only 18(42.85%) cases had diagnosed malignant lesions. Out of 95 cases of benign lesions ultrasound had correctly diagnosed 87(91.57%) cases and mammography had diagnosed 88(92.63%) cases. On combining both 89(93.68%) cases had correctly diagnosed for benign lesion.

## Discussion

This study was conducted on 278 cases for 4 years who had both ultrasound and mammography investigations and out of 278, only 137 cases had histopathology diagnosis of benign, 95(69.34%), and malignant lesion, 42(30.65%). Final assessment was done with BIRADS score which were correlated with histopathology findings. In this study, in ultrasound, out of 137 cases, 131 cases were diagnosed by ultrasound and 6 cases



were normal or negative for lesion which were benign lesion on histopathology whereas in mammography 119 cases were diagnosed by mammography and 18 cases were normal or negative for lesion. Among 18 cases, 17 were benign and 1 was malignant lesions on histopathology. In this study ultrasound can diagnosed most of the cases than mammography, in which 132 cases were diagnosed by ultrasound where as only 119 cases were diagnosed by mammography among diagnosed cases most of the lesions were benign lesions that is 95 (69.37%) cases and only 42 (30.65%) cases were malignant lesion. which is similar to study done at India (2020)<sup>6</sup> Benign lesions like cystic lesions which appears as radiolucent and are difficult to diagnosed by mammography whereas ultrasound can differentiate solid from cystic lesion which is similar to our study where ultrasound can detected more lesions than mammography and also ultrasound is superior to mammography for detecting breast lesion especially in dense breast.<sup>8,9</sup> Fibrocystic disease with predominant cystic component appears as dense breast in mammography which might read as normal which as in ultrasound appears as multiple small cystic lesions.<sup>6</sup>

The average age of female participants in this study was 46.51 years, with the youngest being 29 and the oldest 75 years. The majority of patients belong to age group of 40 to 49 years, accounting for 53(42.3%) individuals. A total of 117(85.4%) cases were under 60 years old, while only 20(14.5%) patients were 60 years or older. Notably, no malignant growths were found in individuals under 35 years old, and most cases of breast cancer occurred in patients over 40 years old, aligning with findings from previous studies done in 2020 and 2004.<sup>5,10</sup>

Significant number of malignant lesions displayed irregular shape, non-parallel orientation, non-circumscribed, abrupt margins, calcification, posterior acoustic shadow, and complex echotexture, with a statistically significant p-value of <0.0001. Conversely, a significant number of benign lesions exhibited round shape, parallel orientation, well-circumscribed, hypoechoic halo, hypoechoic, and posterior acoustic enhancement, which was also statistically significant. This finding aligns with a study conducted in Nigeria, which highlighted that hypoechoic mass with irregular margin, diffuse skin thickening, and posterior acoustic shadowing are common characteristics of malignant lesions.<sup>11</sup> In several studies done on 2000, 2007 and 2008 also found similar findings for benign and malignant lesion.<sup>12,13,14</sup> Some studies stated that hypoechoic or mixed hyper-hypoechoic mass with calcification and posterior acoustic enhancement were features of malignant lesions; however, in our

study, posterior acoustic enhancement are seen more in benign lesion.<sup>15</sup> Some studies showed ill-defined masses with calcification are associated with malignant lesion.<sup>16,17</sup>

The breast composition on mammography showed statistically insignificant findings in this study likely due to breast composition were varies with age of the patients. Malignant lesions exhibited lobulated, irregular shape, indistinct, spiculated margins, macrocalcification, skin thickening, nipple retraction, axillary lymphadenopathy, and architecture destruction. On the other hand, benign lesions displayed round and oval shape, circumscribed margins, microlobulation, and absence of calcification or microcalcification, which is statically significant and consistent with previous studies.<sup>6,14,15</sup> In this study, microcalcification were present more in benign lesion and macrocalcification in malignant lesion which is similar to study done on 2019,<sup>18</sup> whereas, previous study done on 1994 showed microcalcifications, linear branching or pleomorphic microcalcifications have a higher predictive of value of malignant lesion.<sup>19</sup> In this study, there are only 42 number of sample size to study for malignant lesion which might cause contrary to above mentioned study.

The diagnostic accuracy of mammograms and ultrasounds in detecting breast lesions, particularly BIRADS 4 and 5 scores, was found to be very high in this study. Out of 42 cases of malignant lesions, mammography detected 37 (88%) cases, while ultrasound detected 35 (83%) cases. For BIRADS 1 to 3 scores, out of 95 cases, mammography identified 85(89%) cases as benign, and ultrasound identified 80(84%) cases, consistent with previous studies on 2021 and 2022 India.<sup>5,20</sup> In terms of calcifications, mammography (n=95) showed better detection compared to ultrasound (n=36), aligning with findings from China.<sup>3</sup>

In this study, ultrasonography had sensitivity of 91.58% and specificity of 57.14% with positive predictive value of 82.86% and negative predictive value of 75% with diagnostic accuracy of 81.02% which is similar to study done by Kan, et al., found sensitivity of 91.67%, the specificity of 83.93%, positive predictive value 89.53%, negative predictive value 87.04%, and the diagnostic accuracy 88.57%.<sup>21</sup> Similar study done in 2011 study had reported sensitivity 92.1% and specificity 80% by ultrasound.<sup>22</sup> In 2009 another study reported that sensitivity of 72.6% and specificity 73.9%.<sup>23</sup> Another study done on 2018, stated that sensitivity 80.57%, specificity 88.43% and diagnostic accuracy 93.55%.<sup>3</sup>

In this study, on mammography, sensitivity of 92.63% and specificity of 61.90% , positive predictive value of 84.62% and negative predictive value of 78.79% with diagnostic accuracy of 83.21% .2019 study stated that sensitivity 83.2%, specificity 92.3% and diagnostic accuracy 91.24%.<sup>3</sup> In study done on 2022 found sensitivity of 87.88% which is similar to our study and specificity of 95% which is slightly different than our study.<sup>5</sup> Jahan, et al., found sensitivity of 80% which is similar to our study and specificity of 96.97 % which is also slightly different than this study by ultrasound.<sup>24</sup>

Combining the mammography and ultrasonography, sensitivity of 93.69% and specificity of 42.86%, positive predictive value of 78.76% and negative predictive value of 75% which were similar to study done by Mujagić S, et al., stated sensitivity 96.8%, specificity 55.3% and Negeri, et al., which stated sensitivity 88.9% and specificity 46%.<sup>22,25</sup> Overall diagnostic accuracy was 78.1% which is slightly less than ultrasound and mammography alone; however, sensitivity is slightly more by combining both ultrasound and mammography in this study. Zhang, et al., stated that combining ultrasound and mammography had sensitivity 97.45%, specificity 97.15% and diagnostic accuracy 97.22%.<sup>3</sup> This study shows overall sensitivity of ultrasound, mammography and ultrasound combined with mammography were higher in detecting breast lesions which was almost similar to other several studies.<sup>3,20,26</sup>

The study has several potential limitations. Histological subtypes of benign and malignant lesions were not characterized in our study. Axillary lymph nodes were not included in the ultrasound examination. Benign and malignant calcification appearances were not defined in mammography, and asymmetry of the breast was also not included. A large sample size could not be included in this study due to the COVID-19 crisis period. We hope to include a larger population group in the future to evaluate each subtype characteristics.

## Conclusion

Ultrasound and mammography are both highly sensitive in detecting benign and malignant breast lesions, assigning them BIRADS scores. While mammography has slightly higher overall diagnostic accuracy, ultrasound should be used in conjunction with mammography to effectively detect these lesions. In young patients with dense breasts, mammography may not be performed, in which case ultrasound can aid in lesion characterization. Mammography is particularly useful in characterizing calcifications, which are less visible on ultrasound.

## Conflict of Interest

None

## Funding

None

## Author Contribution

Concept, design, planning: SS, PJ, YD; Literature review: SS, YD, PK; Data collection/analysis: SS, SKC, PJ, PK; Draft manuscript: SS, SKC, YD, PJ; Revision of draft: SS, YD, PJ, PK; Final manuscript: SS, SKC; Accountability of the work: SS, YD, PJ.

## References

1. Coughlin SS, Ekwueme DU. Breast cancer as a global health concern. *Cancer epidemiology*. 2009 Nov 1;33(5):315-8. [Google Scholar](#)
2. Li T, Mello-Thoms C, Brennan PC. Descriptive epidemiology of breast cancer in China: incidence, mortality, survival and prevalence. *Breast cancer research and treatment*. 2016 Oct;159:395-406. [Google Scholar](#)
3. Zhang W, Xu C, Li R, Cui G, Wang M, Wang M. Correlation analysis between ultrasonography and mammography with other risk factors related to breast cancer. *Oncology Letters*. 2019 Jun;17(6):5511-6. [Google Scholar](#)
4. Pradhan M, Adhikari RC, Joshi A, Sigdel B, Basnet RB, Amatya V. Present Cancer Status in TU Teaching Hospital, Nepal. *JSSN*. 1999;2:13-23. [Google Scholar](#)
5. Thomas R, Das SK, Balasubramanian G, Chandrappa A. Correlation of Mammography, Ultrasound and Sonoelastographic Findings With Histopathological Diagnosis in Breast Lesions. *Cureus*. 2022 Dec 8;14(12):e32318. [DOI](#)
6. Raj Bhesdadiya, Jagruti Kalola, Maulik Jethva. Mammographic and ultrasonographic evaluation of breast lesions with pathological correlation. *International Journal of Contemporary Medicine Surgery and Radiology*. 2020;5(1):A158-A161. [DOI](#)
7. Sickles, E.A., D'Orsi, C.J., Bassett, L.W., et al. (2013) *ACR BI-RADS Mammography*. In: *ACR BI-RADS Atlas, Breast Imaging Reporting and Data System*, 5th Edition, American College of Radiology, Reston, VA, 134-136. [Weblink](#)
8. Fornage BD, Toubas O, Morel M. Clinical Mammographic and sonographic determination of preoperative breast cancer *Journal of Surgical Oncology* 2004;765-771. [DOI](#)
9. Lee JM, A Rao RF, Sprague BL, Kerlikowske K, Lehman CD, Smith RA, Henderson LM, et al. Performance of screening ultrasonography as an adjunct to screening mammography in women across the spectrum of breast cancer risk. *JAMA Int Med*. 2019;179:658-67. [DOI](#)
10. Hussain, Wells, Nockler PS, Lipsit ER, Blessman. Advantages and pitfalls of ultrasound in diagnosis of breast cancer. *Journal of Ultrasound* 2004;525-532. [DOI](#)

11. Olarinoye-Akorede SA, Aliyu H, Yunusa HG. Pattern of breast ultrasound findings in Zaria, North Western Nigeria. *Arch Int Surg*. 2018;8:54-8. [DOI](#)
12. Zonderland HM, Hermans J, Coerkamp EG: Ultrasound variables and their prognostic value in a population of 1103 patients with 272 breast cancers. *EurRadiol*. 2000, 10:1562-8. [DOI](#)
13. Costantini M, Belli P, Ierardi C, Franceschini G, La Torre G, Bonomo L: Solid breast mass characterisation: use of the sonographic BI-RADS classification. *Radiol Med*. 2007, 112:877-94. [DOI](#)
14. Kim SH, Seo BK, Lee J, Kim SJ, Cho KR, Lee KY, Je BK, Kim HY, Kim YS, Lee JH. Correlation of ultrasound findings with histology, tumor grade, and biological markers in breast cancer. *Acta Oncol*. 2008;47(8):1531-8. [DOI](#)
15. Shin HJ, Kim HH, Huh MO, Kim MJ, Yi A, Kim H, Son BH, Ahn SH. Correlation between mammographic and sonographic findings and prognostic factors in patients with node-negative invasive breast cancer. *Br J Radiol*. 2011 Jan;84(997):19-30. [DOI](#)
16. Thurfjell M, Lindgren A, Thurfjell E. Nonpalpable breast cancer: mammographic appearance as predictor of histologic type. *Radiology* 2002;222:165-70. [DOI](#)
17. Evans A, Pinder S, James J, Ellis I, Cornford E. Is mammographic spiculation an independent, good prognostic factor in screening-detected invasive breast cancer? *AJR Am J Roentgenol* 2006;187:1377-80. [DOI](#)
18. Grimm LJ, Miller MM, Thomas SM, Liu Y, Lo JY, Hwang ES, Hyslop T, Ryser MD. Growth Dynamics of Mammographic Calcifications: Differentiating Ductal Carcinoma in Situ from Benign Breast Disease. *Radiology*. 2019;292:77-83. [DOI](#)
19. Holland R, Hendriks JH. Microcalcifications associated with ductal carcinoma in situ: Mammographic-pathologic correlation *Semin Diagn Pathol* 1994 Aug;11(3):181-92. [PubMed](#)
20. Yamakanamardi S , Hiremath B. Accuracy of mammography and sonomammography and its correlation with histopathology in the detection of breast cancer *Int Surg J*. 2021 Feb;8(2):624-630. [DOI](#)
21. Zeeshan Khan, Muhammad Saleem, Muzammil Bhutta, Najeeb Ullah, Umaima Fatima, Muhammad Yousuf. Diagnostic Accuracy of Ultrasonography in the Diagnosis of Breast Carcinoma in Mammographically Dense Breasts: Histopathology as the Gold Standard *J SOGP*. 2023 Oct-Dec;13(4) :398-402. [Full Text](#)
22. Mujagić, S., Burina, M., Mustedanagić-Mujanović, J., & Šarkanović, G. (2011). The importance of combining of ultrasound and mammography in breast cancer diagnosis. *Acta Medica Academica* 2011, 40(1), 27-33. [DOI](#)
23. Devolli-Disha E, Manxhuka-Kërliu S, Ymeri H, Kutlllovci A. Comparative accuracy of mammography and ultrasound in women with breast symptoms according to age and breast density. *Bosnian J Basic Med Sci*. 2009;9(2):131-6. [DOI](#)
24. Jahan AB, Ahmed MU, Begum M, Hossain MM, Rahman MM, Sarwar JM, Hossain MZ, Begum F, Saha PL, Haque S, Muktadira M. Ultrasonographic Evaluation of Palpable Breast Mass and Correlation with Histopathology. *Mymensingh Med J*. 2017 Apr;26(2):223-229. [PubMed](#)
25. Negri S, Bonetti F, Capitanio A, Bonzanini M. Preoperative diagnostic accuracy of fine-needle aspiration in the management of breast lesions: comparison of specificity and sensitivity with clinical examination, mammography, echography, and thermography in 249 patients. *Diagn Cytopathol*. 1994;11:4-8. 14. [DOI](#)
26. Zhang H, Tan H, Gao J, Wei Y, Yu Z and Zhou Y: The use of sequential X-ray, CT and MRI in the preoperative evaluation of breast-conserving surgery. *Exp Ther Med*. 2016 Sep;12(3):1275-1278. [DOI](#)