



Case Report

# Adrenal involvement in Histoplasmosis

Nisha Sharma<sup>1</sup>, Ram Chandra Adhikari<sup>1</sup>

<sup>1</sup>Department of Pathology, Tribhuvan University Teaching Hospital, Kathmandu, Nepal

**Keywords:**

Adrenal;  
Diabetes;  
Immunocompromise;  
Histoplasmosis ;

**ABSTRACT**

Histoplasmosis is a fungal infection caused by a dimorphic, saprophytic fungus *Histoplasma capsulatum* with primary predilection for the lungs and disseminated infections occurring rarely. Our case illustrates the case of disseminated adrenal histoplasmosis in an immunocompromised 42-year-old diabetic man. Radiological diagnosis suggested bilateral malignant adrenal mass, most likely metastasis. FNAC yielded blood only. Excisional biopsy from left adrenal gland, Hematoxylin & Eosin staining along with special stains as Periodic Acid Schiff and Grocott's Methenamine Silver were performed to yield the concluding diagnosis of histoplasmosis.

**Correspondence:**

Dr. Nisha Sharma, MD

Lecturer, Department of Pathology

Tribhuvan University Teaching Hospital, Kathmandu, Nepal

ORCID ID: 0000-0001-8672-0137

Email: arcticnisha@gmail.com



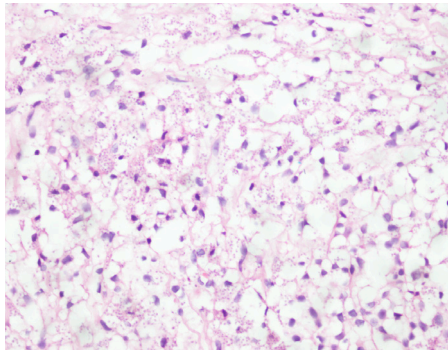
Received : January 19th 2019; Accepted : March 14th 2019; Published : March 29th 2019

Citation : Sharma N, Adhikari RC. Adrenal involvement in Histoplasmosis. J Pathol Nep 2019;9:1502-4. DOI 10.3126/jpn.v9i1.23381

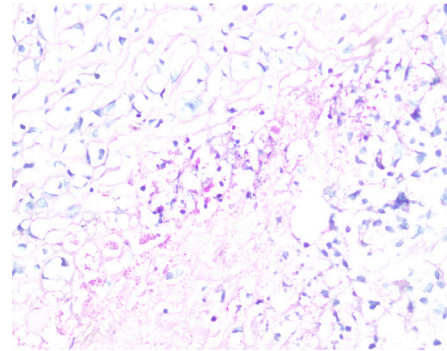
Copyright: This is an open-access article distributed under the terms of the Creative Commons Attribution 4.0 International License, which permits unrestricted use, distribution, and reproduction in any medium, provided the original author and source are credited.

## INTRODUCTION

Histoplasmosis is a fatal infectious granulomatous disease affecting people worldwide caused by a dimorphic saprophytic fungus *Histoplasma capsulatum*.<sup>1</sup> It is primarily a pulmonary infection often asymptomatic or presenting as a self-limiting flu like illness.<sup>2</sup> If infection cannot be cleared, for instance, in immunocompromised patients, the organism continues to reproduce intracellularly and disseminates throughout the body via lymphatic and hematogenous routes, hence causing disseminated histoplasmosis and mimicking metastasis.<sup>3</sup> Disseminated histoplasmosis occurs largely in immunocompromised patients but there have been cases reported in the literature in immunocompetent



**Figure 1:** Sheets of foamy histiocytes. Numerous intracellular (within the cytoplasm of macrophages) and extracellular forms of micro-organisms are noted (HE stain; X400).



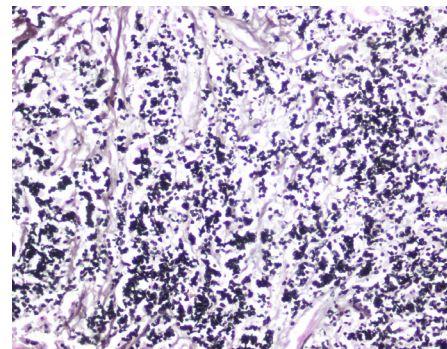
**Figure 2:** PAS stain reveals the micro-organisms (X400).

individuals as well. Adrenal gland is one of the most commonly involved sites in disseminated histoplasmosis and henceforth a meticulous work-up with close follow-up is indispensable.<sup>4</sup>

### CASE REPORT

The patient was a 52-year diabetic male who presented with intermittent fever with chills, and a significant weight loss of 20kg. He was initially treated with antimalarial drugs and antibiotics without any clinical improvement. Biochemical parameters mostly were normal except for random blood sugar level 280mg/dl ( $\leq 200$  mg/dl), urinary VMA 14.6 mg/24 hr ( $<13.6$ ) and LDH 550U/L ( $\leq 280$  U/L). Screening for serum PSA, CA 19-9 and CEA were all within normal limits. Suspecting metastasis, primary sites (lung, thyroid, prostate and GI tract) were searched. However, primary site was not found. USG showed heterogenous mass in both the adrenal glands with right and left adrenals measuring 6.3 cm x 3.8 cm and 7.8 cm x 5.2 cm respectively. Abdominal CT showed Right adrenal gland, 4.8 cm x 4 cm x 3.6 cm and Left adrenal gland, 6 cm x 4.2 cm x 3.2 cm. The initial diagnosis with all these findings was considered as secondary adrenal malignancy of unknown primary.

Image guided FNAC was performed yielding only blood. Incisional biopsy from left adrenal mass was done. Grossly, there were multiple pieces of grey white tissue measuring 3 cm x 2 cm x 0.8 cm. Microscopy showed abundant necrosis with sheets of foamy histiocytes. On a higher magnification, numerous tiny round to oval micro-organisms were noted. Both intracellular organisms within the cytoplasm of macrophages and extracellular forms were identified (fig.1). Special stains like Periodic Acid Schiff (PAS; fig. 2) and Grocott Methenamine Silver (GMS; fig. 3) were performed which helped in the confirmation of these organisms. The patient was convincingly diagnosed as adrenal histoplasmosis and started on Itraconazole with dramatic clinical improvement.



**Figure 3:** The organisms are revealed on Grocott Methenamine Silver stain (X400).

### DISCUSSION

Histoplasmosis is caused by the inhalation of dust particles from soil contaminated with bird and bat droppings that contain the small spores (microconidia), the infectious forms that cause the infection.<sup>5</sup> The growth of the organism in soil is enhanced by bird and bat excrement which expedite sporulation.<sup>6</sup>

The organism exists in the mould (mycelial) form at soil temperatures and switches to the yeast form at normal human body temperatures ( $37^{\circ}$  C) and resides within macrophages. The infection is acquired by the inhalation of spores which make their way into the alveoli and are later taken up by alveolar macrophages.<sup>7</sup>

Histoplasmosis is usually a self-limiting pulmonary infection, often asymptomatic and associated with flu like symptoms with spontaneous recovery. There are three major clinical presentations: pulmonary, progressive disseminated and primary cutaneous histoplasmosis. Progressive disseminated infection is rare and is usually seen in, but not limited to, immunocompromised patients. Adrenal infection is quite a common site of dissemination.<sup>8</sup> Adrenal histoplasmosis has diverse manifestations which could be grouped into: (I) isolated foci of parasitized macrophages,

(II) extensive necrosis with bilateral adrenomegaly, (III) infarction, (IV) granulomatous infection and (V) calcified lesion mimicking tubercular or metastatic lesions.<sup>1</sup>

The common differentials in a case of bilateral adrenal masses include leishmaniasis, tuberculosis, sarcoidosis, primary adrenal tumor, lymphoma, metastasis and uncommonly fungal infection.<sup>9</sup> Morphologically, these organisms are quite similar to *Leishmania donovani* (LD) bodies. Unlike the LD bodies which are PAS negative and stand out in wright stain, these are PAS positive. On radiological imaging, histoplasmosis of the adrenals usually show as bilateral symmetric adrenal enlargement with preservation of normal contour, peripheral enhancement, and low density areas of hemorrhage and necrosis.<sup>10</sup>

Possibility of histoplasmosis should also be kept in mind while dealing with a patient presenting with adrenal masses so as to avoid erroneous diagnosis and inaccurate treatment.

## CONCLUSION

Whenever a patient with bilateral adrenal masses is encountered, physicians should always be alert and think of adrenal histoplasmosis too in addition to other possibilities. It is imperative to obtain a cytological or histopathological examination in conjunction to other tests to confirm the diagnosis so that the appropriate treatment can be instituted at the earliest to avoid unnecessary procedures and fatal complications. Hence, accurate diagnosis with close follow up is mandatory.

**Conflict of Interest:** None

## REFERENCES

1. Gajendra S, Sharma R, Goel S, Goel R, Lipi L, Sarin H, et al. Adrenal histoplasmosis in immunocompetent patients presenting as adrenal insufficiency. *Turkish Journal of Pathology*. 2016;32:105-11. [Crossref](#)
2. Goodwin JR RA, Shapiro JL, Thurman GH, Thurman SS, Des Prez RM. Disseminated histoplasmosis: clinical and pathologic correlations. *Medicine*. 1980;59:1-33. [Crossref](#)
3. Doleschal B, Rödhammer T, Tsybrovskyy O, Aichberger KJ, Lang F. Disseminated Histoplasmosis: A Challenging Differential Diagnostic Consideration for Suspected Malignant Lesions in the Digestive Tract. *Case Rep Gastroenterol*. 2016;10:653-60. [Crossref](#)
4. Rog CJ, Rosen DG, Gannon FH. Bilateral adrenal histoplasmosis in an immunocompetent man from Texas. *Medical mycology case reports*. 2016;14:4-7. [Crossref](#)
5. Kumar Vinay AKA. *Pathologi basis of disease*. II. 9th ed: Reed Elsevier; 2015. p. 669-724.
6. Wheat J, Sarosi G, McKinsey D, Hamill R, Bradsher R, Johnson P, et al. Practice guidelines for the management of patients with histoplasmosis. *Clin Infect Dis*. 2000;30:688-95. [Crossref](#)
7. Subramanian S, Abraham O, Rupali P, Zachariah A, Mathews MS, Mathai D. Disseminated histoplasmosis. *JAPI*. 2005;53:185-9. [Crossref](#)
8. Vyas S, Kalra N, Das P, et al. Adrenal histoplasmosis: An unusual cause of adrenomegaly. *Indian J Nephrol*. 2011;21:283-5. [Crossref](#)
9. Ahuja A, Mathur SR, Iyer VK, Sharma SK, Kumar N, Agarwal S. Histoplasmosis presenting as bilateral adrenal masses: Cytomorphological diagnosis of three cases. *Diagn Cytopathol*. 2012;40:729-31. [Crossref](#)
10. Levine E. CT evaluation of active adrenal histoplasmosis. *Urologic radiology*. 1991;13:103-6. [Crossref](#)