

Distally Based Sural Faciocutaneous and Fascial (Adipofascial) Flap for Reconstruction of Distal Leg, Ankle and Foot Defects.

Parajuli NP,¹ Shrestha D,¹ Panse N²

¹Department of Orthopedics and Trauma

Dhulikhel Hospital

Kathmandu University School of Medical Sciences

Dhulikhel, Kavre

Nepal

²Department of Plastic Surgery

B.J Medical College & Sassoon Hospital,

Pune, India

Corresponding Author

Nirajan Prasad Parajuli

Department of Orthopedics and Trauma

Dhulikhel Hospital

Kathmandu University School of Medical Sciences

Dhulikhel, Kavre,

Nepal

E-Mail: parajulinirajan@gmail.com

Citation

Parajuli NP, Shrestha D, Panse N. Distally Based Sural Faciocutaneous and Fascial (Adipofascial) Flap for Reconstruction of Distal Leg, Ankle and foot defects. *Kathmandu Univ Med J* 2014;46(2):126-31.

ABSTRACT

Background

Any soft tissue defect in distal leg, ankle and hind foot is still a challenging problem. There are various options for coverage of such defects, but the distally based sural neurocutaneous and neurofascial flap based on the sural nerve and superficial sural artery has been an important option.

Objective

To evaluate the efficacy of distally based sural flap in reconstruction of the distal leg, ankle and hind foot soft tissue defects.

Method

Seventeen patients with soft tissue defects over distal leg, ankle and hind foot were included in this study. All patients were treated with distally based sural flap. Most of the cases were due to trauma (16 cases) which compromised tendon and bone. One case was of malignant melanoma of sole of hind foot which required wide excision and soft tissue reconstruction with sural flap.

Result

In all cases defects were successfully covered. Three showed venous congestion and partial necrosis. One developed secondary infection. One flap failed completely. Mean follow up of patients was 20 months (6 – 36 months).

Conclusion

Sural flap is a good option for reconstruction of distal leg, ankle and foot defects.

KEY WORDS

Ankle defect, distally based sural flap, heel defect, leg defect, lower limb reconstruction.

INTRODUCTION

Coverage of soft tissue defects of lower third of the leg, Achilles tendon, malleoli, ankle, and calcaneal area presents a challenging problem for orthopedic surgeons and plastic surgeons because of lack of local cutaneous, fasciocutaneous and muscle flaps in this area. Trauma and other deforming processes can involve soft tissue, underlying bone, ligamentous structures and defects that expose the tendon and bone directly. The heel is a weight bearing area, and this area is traumatized frequently. In addition, the skin over these areas is tight and has poor circulation. There are many possible coverage options, including skin grafts, local flaps, distant flaps and free flaps but their usage is limited and problems exist in these regions. Skin grafts are not suitable to cover the exposed bone, tendon, malleoli, heel, and weight bearing areas. Contraindications to local flaps include; absence of peripheral pulses, diabetes, and peripheral vascular thromboses. Free flaps provide excellent tissue coverage but require a microvascular team and equipment. In addition free flaps are lengthy procedures.

Ponten was first to describe and propose fasciocutaneous flap.¹ Masquelet et al coined the concept of 'neuro-skin island flap',² since then these flaps are used widely. Such flaps are based on the cutaneous branches of the vascular axis around a superficial sensory nerve. Superficial sural artery neurocutaneous flap is an island flap based on vascular axis of sural nerve which gets reverse vascular flow through communication with the septocutaneous perforating branch of the peroneal artery. Different types of flaps can be designed based on its pedicle and components, such as Faciocutaneous, Adipofascial, and fasciomyocutaneous flaps. This versatile flap has definitive advantage. Such as; being easy to raise, has wide range of arc of rotation, requires minimal expertise, does not compromise major artery of leg, takes less time for surgery and can be done in single stage. Sural neurocutaneous flap has been described for the reconstruction of soft tissue defects of lower leg, foot and ankle by many authors.³⁻¹⁰

This article presents the efficacy and experience of distally based sural neurocutaneous flap.

METHOD

Between June 2010 to September 2013, 17 distally based sural flaps were executed in 17 patients. Sixteen flaps were performed for road traffic accidents and one for post tumor excision. Among 17 flaps, 14 were fasciocutaneous and three were fascial. The location of defects were around distal leg, ankle, hind foot (heel), and fore foot (Table). Of the 17 patients, 11 were males and 6 were females. The age ranged from 5 to 60 years. The follow up ranged from 4 months to 22 months with average follow up of 13 months. The size of skin defect ranged from 12 x 8 cm to 6 x 3 cm. Islanded flaps were raised 12 to 26 cm in length from the tip

of lateral malleolus. The arc of rotation of the flaps ranged from 70° to 180°. In thirteen cases, flaps were rotated 180° to cover defects over Achilles tendon and Heel.

Relevant Surgical Anatomy:⁹

Sural nerve is a sensory nerve supplying the lateral aspect of foot. It is usually located 1.5 cm posterior to the lateral malleolus. It is formed by union of the Medial sural cutaneous (Tibial component) and Lateral sural cutaneous nerve (Peroneal component) and passes in between two heads of gastrocnemius muscle. The arterial supply to the reverse flow sural flap is provided by septocutaneous perforators arising from peroneal artery. The most distal of these is located 4 to 7 cm proximal to the lateral malleolus; passing in between Soleus and Peroneus Longus. These vessels connect directly with superficial sural arteries. The superficial sural artery and Sural Nerve run together in subfascial plane in proximal one third of leg and they become subcutaneous in the middle one third. During their course the superficial sural artery nourishes the sural nerve and gives numerous neurocutaneous perforators which supply the fascia and skin of the flap. The skin and fascia of the flap is primarily drained by lesser saphenous vein.

Surgical Procedure:

All flaps were raised in prone position. Flaps were designed over the calf region of the leg according to the size of the defect. The axis of the flap was marked between mid point of popliteal fossa to mid point between lateral malleolus and Achilles tendon. The pivot point was kept at 7cms above the tip of lateral malleolus. Flap planning was then done in reverse, depending upon the size and site of the defect. Flap was raised in a Subfascial manner and sural nerve and lesser saphenous vein is ligated and elevated with the flap so the flap contained skin, fascia, lesser saphenous vein and sural nerve. In fascial (Adipofascial) flap; flap contained only subcutaneous fat, fascia, lesser saphenous vein and sural nerve. Sural nerve is transected early on and included in the flap harvest. The skin overlying the fascial pedicle is undermined and the dissection is carried out up to pivot point. In all cases the pedicle contained subcutaneous fat, fascia, lesser saphenous vein and sural Nerve. Pedicle width ranged from 4 cm to 6 cm.¹⁸ The flap is rotated over the pivot point and transferred to the recipient area through an open or close subcutaneous tunnel. Open tunnel was preferred in those cases where subcutaneous tunnel was tight. The fascial flap is covered with skin graft after transfer to recipient site. The donor area is covered with skin graft.

Post operatively all cases were splinted in a above knee plaster of Paris splint. The limb was kept elevated by help of Posts attached to the splint (Fig. 1). This helped in prevention of compression of flap as well as pedicle when patients were supine. After suture removal at two weeks time the splint is removed and crepe bandage is applied. Range of motion of ankle is started at this time. Full weight bearing is allowed for cases where the recipient area is

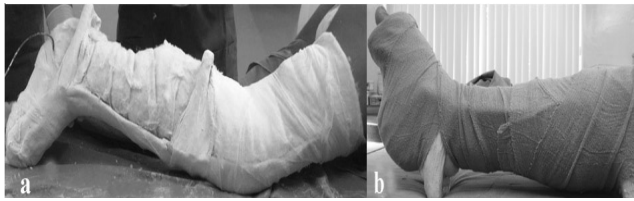


Figure 1. Post Operative splinting.

not at the weight bearing area. For fracture and fracture dislocation cases weight bearing is started as fracture healing was evident (6-8 weeks). For those cases where recipient area was at weight bearing area, weight bearing was started after six weeks. In such cases a silicon heel insert or a silicon sole insert was given to prevent ulceration in the flap.

RESULT

The flap survived in 16 cases. There was partial flap loss in three patients and complete flap loss in one patient. In one case flap had complete necrosis (Fig: 2); which required multiple debridement and skin grafting. In this case the defect was over forefoot and the flap length was 24 cm from the tip of lateral malleolus; with arc of rotation of 180°. Three out of sixteen cases had venous congestion and superficial skin necrosis at the tip of flap which required debridement and resuturing (2 cases) or skin grafting (one case). One case had post operative recipient area infection with out flap complications which settled with debridement and antibiotics. All donor sites healed uneventfully with skin grafting. Almost all patients were satisfied with the results. Two patients complained of excessive bulk of flap over Achilles tendon coverage area. One of them required debulking procedure and was satisfied after that. One patient complained of hair growth over sole area at flap site (Fig: 3); which required Epilation in Dermatology department. None of the patient had any complain over sural nerve distribution. In general, overall result of reverse sural flap in this series was satisfactory. (Table 1)

DISCUSSION

Soft tissue defects exposing bone, tendon and neurovascular elements in lowers extremity has been a constant problem to orthopedic surgeons. Orthopedic surgeons due to lack of expertise in soft tissue coverage like flaps, usually rely on plastic surgeons. Due to lack of expertise in our set up those patients having soft tissue defects either were referred to other centre or those defects were skin grafted with compromise to vital structures of foot and ankle. Transfer of patients to centers with availability of plastic surgeons leads to delay in coverage, and may lead to multiple other complications. In this series all the cases were performed by orthopedic surgeon with some experience in soft tissue coverage.

Coverage of soft tissue defects in lower limb has been

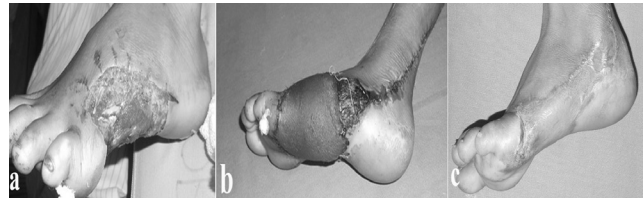


Figure 2. a,b,c – Complete necrosis of flap.

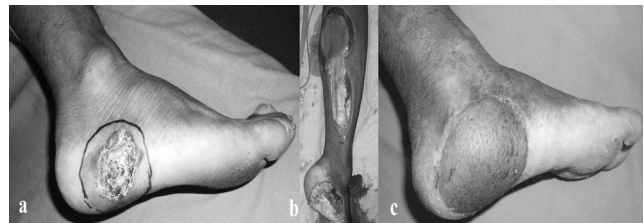


Figure 3. (a) Case of Malignant Melanoma of right sole. (b) Intra operative picture after wide excision and sural flap elevation. (c) Post operative 9 months with well settled flap.

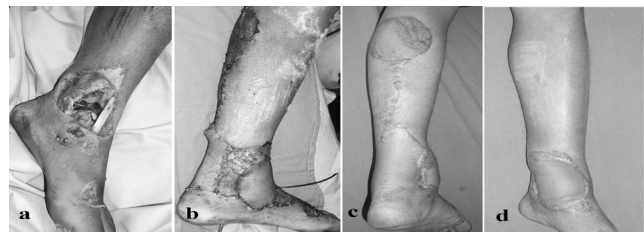

Figure 4. (a) Motor vehicle accident with open ankle injury. (b) Post Operative 3rd day after sural flap coverage. (c and d) six month follow up with well settled flap.

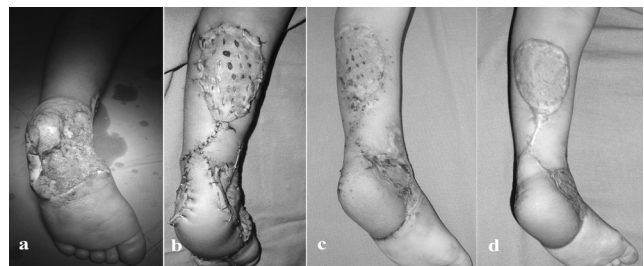


Figure 5. Heel pad avulsion in a five year girl due to RTA. (a) Pre operative picture (b) Post operative 3rd day after sural flap coverage and skin grafting. (c) Post operative 6 weeks. (d) Post operative six months.

common due to increase in motor vehicle accidents. There are large variety of flaps like; lateral supramalleolar skin flap, posterior tibial perforator flap, sural flap and free flaps for reconstruction of post traumatic defects of lower limbs, which are not familiar to orthopedic surgeon. Even though with good hands flap failure and donor site morbidity can occur.⁴⁻⁶

Reverse sural flap being a useful and versatile flap can be raised easily with minimum expertise to reconstruct soft tissue defects of distal leg, ankle and foot.⁴⁻⁸ Major advantages of this flap are; its largest arc of rotation where the flap pedicle can be rotated 180°. In this series out of seventeen flaps thirteen flap pedicles were rotated 180° with some negligible complications. Raising flap is relatively

Table: 1 Demographic property of patients wounds and flap. (M= Male, F=Female, RTA=Road Traffic Accidents, cm=centimeters).

S. No	Age/Sex	Location of Recipient site	Etiology of defect	Flap size	Complication	Remarks
1	40/M	Gustilo IIIb Open left Tibia fracture Distal 1/3 rd	RTA	11 x 8 cm	None	Complete healing
2	32/M	Open left Ankle Injury with exposed lateral malleolus	RTA	10 x 8 cm	Partial superficial flap necrosis	Skin Grafted
3	14/F	Skin Defect with Exposed Achilles Tendon Right	RTA	8 x 6 cm	None	Complete healing
4	60/M	Degloving injury right foot with loss of heel pad	RTA	12 x 8 cm	Partial superficial skin necrosis	Resuturing
5	22/F	Skin defect with exposed Achilles Tendon right	RTA	9 x 6 cm	Bulky	Debulking
6	17/F	Skin Defect with exposed Achilles Tendon right	RTA	7 x 5 cm	None	Fascial flap
7	31/M	Degloving Injury of Right Foot	RTA	10 x 6 cm	None	Complete healing
8	17/M (Fig:3)	Open ankle Injury left	RTA	8 x 8 cm	None	Complete healing
9	31/F	Skin defect with exposed Achilles Tendon right	RTA	6 x 5 cm	None	Fascial flap
10	45/M	Skin defect with exposed Achilles Tendon left	RTA	7 x 5 cm	None	Complete healing
11	55/M (Fig:4)	Malignant Melanoma of Right foot (sole)	Tumor	8 x 8 cm	Hair growth over flap	Epilation
12	5/F (Fig:2)	Degloving injury left foot with loss of heel pad	RTA	11 x 7 cm	None	Complete healing
13	12/M	Skin defect exposing Achilles Tendon	RTA	6 x 3 cm	None	Complete Healing
14	14/F (Fig:5)	Traumatic wound over left fore foot with open 5th Metatarsal fracture	RTA	10 x 8 cm	Complete Necrosis of flap	Debridement and skin grafting
15	25/M	Skin Defect exposing Achilles Tendon right	RTA	7 x 5 cm	None	Complete Healing
16	42/M	Degloving injury right foot with loss of heel pad	RTA	11 x 9 cm	Partial superficial skin necrosis	Resuturing
17	27/M	Skin defect with exposed Achilles tendon left	RTA	7 x 4 cm	None	Fascial flap

easy, and loupe magnification was not used in this series except for pediatric cases. The learning curve for harvesting the flap is relatively small as compared to microsurgery. In our initial flaps operative time was around 180 minutes but with experience operative time in later flaps was around 60 to 90 minutes. More importantly reverse sural flap does not depend on microsurgery like free flaps which require vascular anastomosis and it does not sacrifice any major artery of lower limb.⁹⁻¹¹

The versatility and efficacy of flap has been explained by many authors.^{10,11,14,22,23} It has proven its versatility and efficacy in two of our cases (Fig: 4 and 5). In both the cases first choice of coverage of such defects would have been a free flap. But reverse sural flap has replaced free flap in those two cases.

Reverse sural flap can be chosen to cover soft tissue defect of distal leg, ankle, hind foot and mid foot. In some instances with caution it can be used in covering soft tissue defects of forefoot. Long pedicle with 180° pedicle rotation can result in flap failure, which was observed in one of the case in this series (Fig: 2). The adipofascial pedicle width of 4 cm or more is important to assure survival of the flap.¹⁶ In this series all flaps had 4 cm or more width of adipofascial pedicle.

Venous congestion of flap because of inadequate venous drainage is one of the reasons for partial or complete failure of flap. Most of the authors emphasize on the importance of including lesser saphaneous vein to ensure good venous drainage.¹⁷⁻¹⁹ As demonstrated by Imanishi et al;¹⁷ small caliber net work of veins surround the sural nerve,

which run along the length of the lesser saphaneous vein accompanying the superficial sural artery, which allow the bypass of valves of the lesser saphaneous vein. Some author like Xu et al recommended ligation of lesser saphaneous vein at the pivot point.¹⁹ In his series he observed venous congestion due to intact lesser saphaneous vein which was not sufficient to provide venous drainage and after ligation at the pivot point congestion was not seen. Many techniques are described to decrease venous congestion including opening intervening skin, venous supercharging and exteriorizing pedicle.^{20,21} In this series the intervening skin was opened in seven cases where subcutaneous tunnel was tight. In none of the cases supercharging or exteriorizing was done. In our series we included lesser saphaneous vein in all cases. Three flaps (17%) showed venous congestion and partial superficial skin necrosis which required debridement and resuturing/skin grafting. The rate of flap necrosis varies from 15% to 16%.²³

Many authors recommend early wound coverage with in 72 hrs in open fractures after stabilization of fracture. They observed lesser infection rates, rapid healing and early restoration of function.^{13,24-26} In this series most of the flaps were done for traumatic soft tissue defects. One case was of distal tibia open fracture covered with sural flap after external fixation. We achieved complete healing of fracture without second intervention with early restoration of function.

With exception to few cases, all cases showed fewer rates of infection, rapid healing and early restoration of function with satisfactory outcome.

Cosmetic deformity including graft over calf and contour deformity which is visible is one of the problems after sural flap. But considering the risk benefit ratio, with no microsurgical facilities, sural flap is the best option in our setup as those deformities can be covered with long clothing.

CONCLUSION

Reverse sural flap has been used for multiple reasons like open fracture, osteomyelitis, pressure sores, traumatic wounds and diabetic ulcers around foot and ankle. In this series we have used reverse sural flap for traumatic wound coverage and reconstruction of soft tissue defect after malignant melanoma excision successfully. In our experience reverse sural flap is a versatile flap for reconstruction of soft tissue defects of distal leg, ankle and foot.

In country like Nepal, availability of Plastic surgeons is very less. Orthopedic surgeons managing trauma have to take on this responsibility of covering such defects. Harvesting this flap is very easy and learning curve is small. Orthopedic surgeon if they take some training, they can easily cover these defects.

REFERENCES

- Ponten B. The fasciocutaneous flap. Its use in soft tissue defects of lower leg. *Br J Plast Surg* 1981; 34: 215.
- Masquelet AC, Romana MC, Wolf G. Skin island flap supplied by the vascular axis of the sensitive superficial nerve. Anatomic study and clinical experience in the leg. *Plast Reconstr Surg* 1992; 89: 1115- 1121.
- Chang SM, Zhang K, Li HF, Huang YG, Zhou QZ, Yuan F, et al. Distally based sural fasciomyocutaneous flap. Anatomical study and modified technique for complicated wound of lower third and weight bearing heel. *Microsurgery* 2009; 29: 205-213.
- Amador EV. Distally based superficial sural Neurocutaneous flap for reconstruction of the Ankle and Foot in children. *J Plast Reconstr & Aesthetic Surg* 2009; 62: 1087- 1093.
- Shahzad MN, Ahmed N. Distally based sural flap: Experience with 50 flaps. *Ann Pak Inst Med Sci* 2012; 8(2):117-121.
- Hamdi MF, Kalti O, Khelifi A. Experience with distally based sural flap: A review of 25 cases. *The Journal of Foot and Ankle Surgery* 2012; 51:627-631.
- Zhang FH, Chang SM, Lin SQ, Song YP, Lineaweaver WC, Zhang F. Modified Distally based Sural Neuro- Veno- Fasciocutaneous Flap: Anatomic study and clinical application. Wiley- Liss, Inc, *Microsurgery* 2005; 25: 543- 550.
- Hassanpour SE, MohammadKhan N, Arasteh E. Is it safe to extract the reverse sural artery flap from the proximal third of leg? *Arch Iranian Med* 2008; 11(2): 179- 185.
- Follmar K E, Bacarani A, Baumeister S P, Levin L S, Erdmann D. The Distally Based Sural Flap. *Plast Reconstr Surg* 119: 138e, 2007.
- El-din AB, El-Bassioni L, El-Habiby AM. Distally based sural cutaneous flap for coverage of foot defects. *Egypt J Plast Reconstr Surg* 2006;30(2):93-99.
- Alam MK, Shaheen MS, Hossain S, Anam S, Rahmin S. Sural Island flap-A good option for coverage of the exposed heel(Tendo Achilles).*J Dhaka Med Coll* 2010;19(1):19-24.
- Riedl O, Frey M. Anatomy of sural nerve: Cadaver study and literature Review. *Plast Reconstr Surg* 2013; 131: 802.
- Hsieh CH, Liang CC, Kueh NS, Tsai HH, Jeng SF. Distally based Sural Island flap for the reconstruction of a large soft tissue defect in an open tibia fracture with occluded Anterior and Posterior Tibial arteries- a case report. *Br J Plast Surg* 2005; 58(1): 112-5.
- Hasegawa M, Torii S, Katoh H, Esaki S. The Distally based superficial sural artery flap. *Plast Reconstr Surg* 1994; 93: 1012.
- Fodor L, Horesh Z, Lerner A, Ramon Y, Peled IJ, Ullmann Y. The Distally based Sural Musculoneurocutaneous flap for treatment of Distal Tibia Osteomyelitis. *Plast Reconstr Surg* 2007; 119: 2127.
- Buluc L, Tosun B, Sen C, Sarlac AY. A modified technique for transposition of the reverse sural Artery flap. *Plast Reconstr Surg* 2006; 117: 2488.
- Imanishi N, Nakajima H, Fukusumi S. Venous drainage of the distally based lesser saphaneous-sural-veno-neuroadipofascial pedicle fasciocutaneous flap. A radiographic perfusion study. *Plast Reconstr Surg* 103 (1999); 494.
- Tanaka Y, Tajima S. The influence of arterial inflow and venous outflow on the survival of reversed flow island flap: an experimental study. *Plast Reconstr surg* 1997; 99 (7): 2021-9.

19. Xu G, Jin LL. The coverage of skin defects over the foot and ankle using the distally based sural neurocutaneous flaps: Experience of 21 cases. *J Plast Reconstr & Aesthetic Surg* 2008; 61 (5): 575-7.
20. Fujiwara M, Nagata T, Matsushita Y, Ishikawa K, Ohta Y, Fukamiju H. Delayed distally based sural flap with temporary venous supercharging. *Microsurgery*. 2013; 33: 534-8.
21. Maffi TR, Knoetgen J, Turner NS, Moran SL. Enhanced survival using the distally based sural artery Interpolation flap. *Ann Plast Surg* 2005; 54: 302-5.
22. Raveendran SS, Parera D, Happuharachchi T, Yoganathan V. Superficial sural artery flap-a study in 40 cases. *Br J Plast Surg* 2004; 57(3): 266-9.
23. Akhtar S, Hameed A. Versatility of the sural fasciocutaneous flap in the coverage of lower third leg and hind foot defects. *J Plast Reconstr & Aesthetic Surg* 2006; 56 (8): 839- 45.
24. Byrd HS, Cierny G, Tebetts JB. The management of open tibial fractures with associated soft tissue loss. External pin fixation with early flap coverage. *Plast Reconstr Surg* 1981; 86: 73-82.
25. G. Cierny, HS Byrd, RE Jones. Primary versus delayed soft tissue coverage for severe open tibial fractures. A comparison of results. *Clin Orthop* 178(1983), 54- 63.
26. Fischer MD, Gustilo RB, Varecka TF. The timing of flap coverage, bone grafting and intramedullary nailing in patients who have a fracture of the tibial shaft with extensive soft tissue injury. *J Bone Joint Surg* 73-A (1991), 1316-22.