

Original article

Amniotic membrane transplantation (AMT) without the use of sutures/fibrin glue

Ajai Agrawal¹, VB Pratap²

¹Department of Ophthalmology, Kalpana Chawla Government Medical College, Karnal, India

²Regional Institute of Ophthalmology and Eye Hospital, Sitapur, India

Abstract

Introduction: Amniotic membrane transplantation (AMT) has been used for a wide variety of ocular surface problems. Current techniques for the AMT involve suturing of the graft or patch over the ocular surface or use of fibrin glue. **Objective:** To describe a new sutureless technique of amniotic membrane transplantation (AMT) without the use of sutures/fibrin glue. **Materials and methods:** Amniotic membrane transplantation as overlay or patch was done in fourteen eyes of eight patients with severe dry eye due to Stevens Johnson syndrome for ocular surface reconstruction, promotion of epithelization, reduction of inflammation and symptomatic relief from dry eye. In this new technique of amniotic membrane transplantation, we mount the amniotic membrane with its epithelial side up on a conformer & place it on the ocular surface without applying any sutures. **Conclusion:** In all the fourteen eyes of eight patients operated at our centre, the amniotic membrane take up was satisfactory, with significant reduction of inflammation and symptomatic relief from dry eye. This is a simple, fast effective technique with surgical outcomes comparable to amniotic membrane transplantation using sutures/ fibrin glue.

Keywords: AMT, sutureless technique, graft, fibrin

Introduction

Amniotic membrane transplantation (AMT) has been used for a wide variety of ocular surface problems. The spectrum of its use has widened over the years. It is currently being used for conjunctival surface reconstruction in patients with chemical burns, cicatrizing conjunctivitis, ocular surface squamous neoplasia (OSSN), symblepharon release, fornix formation, socket reconstruction and pterygium surgery in

addition to its use in corneal & ocular surface reconstruction (Burman et al,2004;Honavar et al,2000).

The human amniotic membrane is the innermost layer of the placenta which is 0.02 mm to 0.5 mm in thickness and is a five layered membrane. It consists of an epithelial monolayer resting on a basement membrane and has an avascular hypocellular stromal matrix.

Amniotic membrane transplants work well for ocular surface reconstruction by decreasing inflammation, scarring and vascularisation and provide a new basement membrane for the expansion of surviving epithelial stem cells. AMT may be used as an inlay or graft

Received on: 26/01/15

Accepted on: 30/06/15

Address for correspondence

Dr. Ajai Agrawal
Associate Professor,
Department of Ophthalmology,
Kalpana Chawla Government Medical College, Karnal.
Phone:0091-860759322
E-mail:ajaiagrwal@rediffmail.com

(Sippel et al, 2001) to act as a scaffold for the epithelial cells, or as an overlay or patch (Azuaara-Blanco et al,1999; Letko et al,2001) to protect underlying healing surface and reduce inflammation.

Current techniques for AMT involve suturing of the graft or patch over the ocular surface using 10-0 monofilament nylon with /without 8- 0 polyglactin / vicryl sutures or use of fibrin glue We describe below the first such reported technique of sutureless AMT which is fast, simple & effective.

Materials and methods

Amniotic membrane procurement, processing and preservation

Amniotic membrane was obtained from donors undergoing elective Caesarean section, who were negative for communicable diseases including HIV, hepatitis and syphilis. The procured placenta was cleaned with balanced salt solution containing a cocktail of antibiotics (50microgm/ ml penicillin, 50 microgm/ml streptomycin, 100 microgm/ml neomycin and 2.5 microgm/ml of amphotericin –B) under sterile conditions as recommended by Kim (Kim and Tseng,1995). The amnion was separated from the chorion by blunt dissection and stored in 50% glycerol for a period of upto 24 hours.

Indications for use and outcome measures

Amniotic membrane transplantation as overlay or patch was done in fourteen eyes of eight patients with severe dry eye - Level 4 disease (DEWS classification) due to severe Stevens Johnson syndrome(in post inflammatory stage with extensive symblepharon formation) at our tertiary care centre in North India during a three year period from April 2009 to March 2012. The cases included in the study had a total/diffuse limbal stem cell deficiency. The AMT was done for ocular surface reconstruction, reduction of inflammation (post symblepharon release) and symptomatic relief from dry eye.

Surgical technique

Informed consent was obtained from all patients prior to surgery. After giving peribulbar anesthesia, the surgical area was cleaned & draped to ensure proper asepsis. Single lid sutures (6–0 silk) were placed in upper & lower lid for retraction of the lids. The ocular surface bed was prepared by removing adhesions like symblepharon and keratoblepharon. The corneal surface was also meticulously cleaned. The amniotic membrane stored in 50% glycerol was again rinsed with balanced salt solution and a cocktail of antibiotics as previously described, and spread over a wooden block/ glass plate with epithelial side up. A square piece of amniotic membrane with epithelial side facing upwards and approximately 5 by 5 cm in size was cut out. The free ends of the amniotic membrane were held with artery clamps. Both lids were retracted by the preplaced lid sutures and the conformer of predetermined size with donor amniotic membrane patch was placed over the cleaned host ocular surface (figures 1&2). No sutures were used to secure the amniotic membrane over the host bed. The lid sutures were then tied together to ensure that the conformer with amniotic membrane patch remained in place (figure 3). Any extra amniotic membrane was cut at the level of the lid margins. Postoperatively, the patient was asked to instill moxifloxacin 0.5% eye drops & povidone iodine (betadine) 5% eye drops each three times a day. The lid sutures were removed after 10 days. The conformer was also removed after 10 days of surgery when the lid sutures were removed. There were no complications related to AMT on removal of the conformer in any of the cases. The amniotic membrane was not removed, but was allowed to fall off on its own over the next few weeks. The patients were kept on topical antibiotic (moxifloxacin 0.5% eye drops) three times a day for four weeks, topical steroid (dexamethasone 0.1% eye drops) four times a day for four weeks and tapered over the next four weeks and

topical lubricant (carboxy methyl cellulose 1% eye drops) four times a day for a duration of three months. All patients were subjected to Schirmer's testing with topical anesthesia preoperatively and post operative Schirmer's testing was done one week after removal of the lid sutures and conformer (Post op day-17) and three months postoperatively, for objective evaluation of their dry eye disease.

Table 1: Schirmer's test readings (Basal secretions)

| Time period | Pre-operative | Post-operative (Day seventeen) Test readings (mm) Post-operative | (Three months) |
|------------------|---------------|--|----------------|
| Patient 1 (R.E) | 1 | 2 | 2 |
| (L.E.) | 2 | 4 | 4 |
| Patient 2 (R.E) | 0 | 2 | 3 |
| (L.E.) | 0 | 2 | 2 |
| Patient 3 (R.E.) | 2 | 3 | 3 |
| (L.E.) | 0 | 1 | 2 |
| Patient 4 (R.E.) | 1 | 3 | 3 |
| (L.E.) | 2 | 3 | 3 |
| Patient 5 (R.E.) | 2 | 4 | 4 |
| (L.E.) | 2 | 3 | 3 |
| Patient 6 (R.E.) | 0 | 2 | 3 |
| (L.E.) | 0 | 2 | 2 |
| Patient 7 (R.E.) | 1 | 3 | 3 |
| Patient 8 (R.E.) | 0 | 2 | 2 |

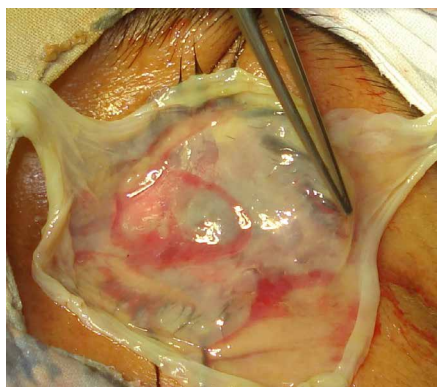


Figure 1: Peroperative photograph showing amniotic membrane of appropriate size ready to be mounted on conformer.

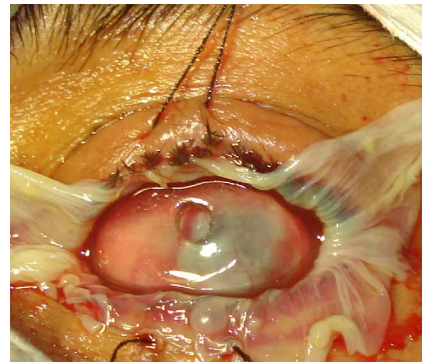


Figure 2: Peroperative photograph showing amniotic membrane mounted on conformer and placed over ocular surface.

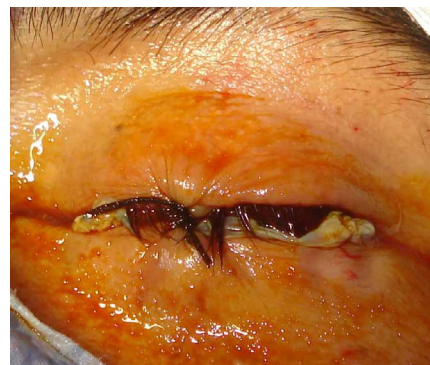

Figure 3: Photograph at completion of surgery with both lid sutures tied to each other to keep conformer and amniotic membrane in place.

Results

Fourteen eyes of eight patients with severe dry eyes (Schirmer's test values with topical anesthesia less than 5mm) due to Stevens Johnson syndrome underwent sutureless AMT surgery. The patients were in the age group of 25-46 years (mean age 34 years). Six of the patients were male and two patients were of female gender. Five of the male patients and one female patient underwent bilateral surgery at an interval of ten days. The other two patients (one male and one female) underwent surgery of their right eye. In all the fourteen eyes of the eight patients operated at our centre, the amniotic membrane take up was satisfactory, with significant reduction of inflammation after symblepharon release and

symptomatic relief from dry eye. There was also some objective improvement in the basal tear secretion on Schirmer's testing (Table-1). However the Schirmer's test values did not differ significantly with AMT. We did not encounter any postoperative complications with the above technique. All the eight patients had a complication free three month follow up. Since the purpose of our article is to highlight our surgical technique, we did not perform any other investigations or tests on the patients.

Discussion

The usefulness of amniotic membrane for ocular surface reconstruction is undeniable. However, we have felt that the current technique of suture fixation of amniotic membrane is time consuming and cumbersome. Use of sutures for AMT cause corneal irritation, scarring, graft loss due to membrane shrinkage and the need for subsequent suture removal (Szurman et al,2006). Various researchers have used fibrin glue instead of suturing amniotic membrane to the host bed both in rabbit models & humans (Szurman et al,2006; Kheirkhah et al,2007;Kaufman et al,2003;Duchesne et al, 2001) .

Szurman et al. have successfully done ocular surface reconstruction in rabbits by suture less amniotic membrane fixation using fibrin glue. Kheirkhah et.al have used fibrin glue for AMT in human subjects with conjunctivochalasis. Kaufman and co – workers have conducted a pilot study on human fibrin tissue adhesive for suture less lamellar keratoplasty and scleral patch adhesion. Duchesne et al. have used human fibrin glue and amniotic membrane transplants in cases with corneal perforation. These techniques have done away with suture related complications, but focal conjunctival inflammation and pyogenic granuloma can still occur with the above techniques.

Conclusion

Our technique of sutureless AMT without using any adhesive is simple, safe, fast and effective as compared to conventional suture fixated AMT. The added advantage is that no suture or fibrin glue related complications occur with this new technique. However, randomized controlled studies need to be done in the future to assess the universal acceptability of sutureless AMT.

References

- Burman S, Tejwani S, Vemuganti GK, Gopinathan U , Sangwan US (2004). Ophthalmic applications of preserved human amniotic membrane: A review of current indications. *Cell Tissue Bank*; 5: 161- 175.
- Honavar SG, Bansal AK, Sangwan VS, Rao GN(2000).Amniotic membranetransplantation for ocular surface reconstruction in Stevens Johnson syndrome. *Ophthalmology* ; 107 :975-979.
- Sippel KC, Ma JJ, Foster CS (2001). Amniotic membrane surgery. *Curr Opin Ophthalmol* ; 12: 269-281.
- Azuara-Blanco A, Pillai CT, Dua HS (1999). Amniotic membrane transplantation for ocular surface reconstruction. *Br J Ophthalmol* ; 83:300-302.
- Letko E, Stechschulte SU, Kenyon KR, Sadeq N, Romero TR, Samson CM, et al.(2001). Amniotic membrane inlay and overlay grafting for corneal epithelial defects and stromal ulcers. *Arch Ophthalmol* ; 119:659-663.
- Kim JC, Tseng SC (1995). Transplantation of preserved human amniotic membrane for surface reconstruction in severely damaged rabbit corneas. *Cornea* ; 14: 473-484.
- Szurman P, Warga M, Grisanti S, Roters S, Rohrbach JM, Aisenbrey S, et al.(2006). Sutureless amniotic membrane fixation using fibrin glue for ocular surface reconstruction in a rabbit model. *Cornea* ; 25(4): 460-466.



Kheirkhah A, Casas V, Blanco G, Li W, Hayashida Y, Chen YT, et al.(2007). Amniotic membrane transplantation with fibrin glue for conjunctivochalasis. *Am J Ophthalmol* ; 144(2): 311-313.

Kaufman HE, Inslar MS, Ibrahim-Elzembely HA, Kaufman SC (2003). Human

fibrin tissue adhesive for sutureless lamellar keratoplasty and scleral patch adhesion: a pilot study. *Ophthalmology* ; 110(11): 2168-2172.

Duchesne B, Tahi H, Galand A (2001). Use of human fibrin glue and amniotic membrane transplantation in corneal perforation. *Cornea* ; 20: 230-232.

Source of support: nil. Conflict of interest: none