

## Bilateral Keratomalacia Secondary to Xerophthalmia

Jyoti Sapkota<sup>1</sup> , Rachana Rana<sup>2</sup><sup>1</sup>Rapti Eye Hospital, Dang, Nepal<sup>2</sup>Tilganga Institute of Ophthalmology, Kathmandu, Nepal

### ABSTRACT

**Introduction:** Vitamin A deficiency leads to a wide spectrum of ocular manifestations ranging from conjunctival xerosis to corneal ulceration and perforation. Penetrating keratoplasty along with vitamin A supplementation can save the eye and useful vision.

**Case:** A 10-year-old boy presented with decreased vision in both eyes for 3 months. Slit-lamp examination with diffuse light revealed bilateral corneal thinning with iris prolapse at inferior aspect of cornea. He underwent therapeutic penetrating keratoplasty in both eyes. Vitamin A supplementation was given as per national protocol. Till 1 year postoperatively visual acuity in RE was 6/18 and LE was pre-phthisical.

**Conclusion:** Vitamin A deficiency is potentially a sight threatening condition, which may lead to keratomalacia and corneal perforation if neglected. Timely management with Vitamin A supplementation and penetrating keratoplasty can save the eye and vision.

**Key words:** Keratomalacia, Penetrating Keratoplasty, Vitamin A.

### INTRODUCTION

The hypovitaminosis A is a leading cause of avoidable blindness in children in developing countries (Thylefors et al., 1995). It is a major nutritional public health problem-affecting children, pregnant and lactating women. However, vitamin A deficiency is rare in developed countries (Smith et al., 2000; Agarwal, 2007).

The xerophthalmia is the clinical spectrum of ocular manifestation of vitamin A deficiency ranging from conjunctival xerosis to severe blinding complications such as keratomalacia. The liquefaction of cornea owing to keratomalacia can be localized or diffused and can be easily perforated spontaneously or following trivial trauma. Therefore, the management of keratomalacia in the late

Financial Interest : Nil

Received : 06.03.2022

Conflict of Interest : Nil

Accepted : 13.05.2022

#### Corresponding Author

Dr. Jyoti Sapkota  
Rapti Eye Hospital, Dang, Nepal.  
E-mail: jyoti.ss100@gmail.com



Access this article online

Website: [www.nepjol.info/index.php/NEPJOPH](http://www.nepjol.info/index.php/NEPJOPH)

DOI: <https://doi.org/10.3126/nepjoph.v14i2.43679>

Copyright © 2022 Nepal Ophthalmic Society

ISSN: 2072-6805, E-ISSN: 2091-0320



This work is licensed under a Creative Commons Attribution-NonCommercial-NoDerivatives 4.0 International License (CC BY-NC-ND).

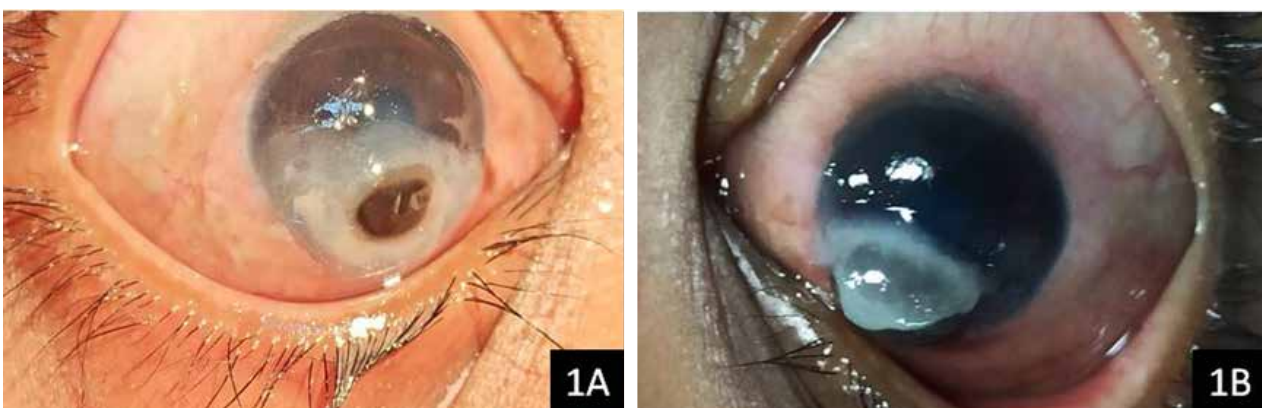
stage of Hypovitaminosis A is challenging and no definite treatment has been developed. However, various modifications of keratoplasty procedures have been reported to improve the outcome.

In this case report we present the clinical features and post operative management of a young boy with bilateral keratomalacia. This case report is an attempt to highlight the severe manifestations of vitamin A deficiency, its early diagnosis and management.

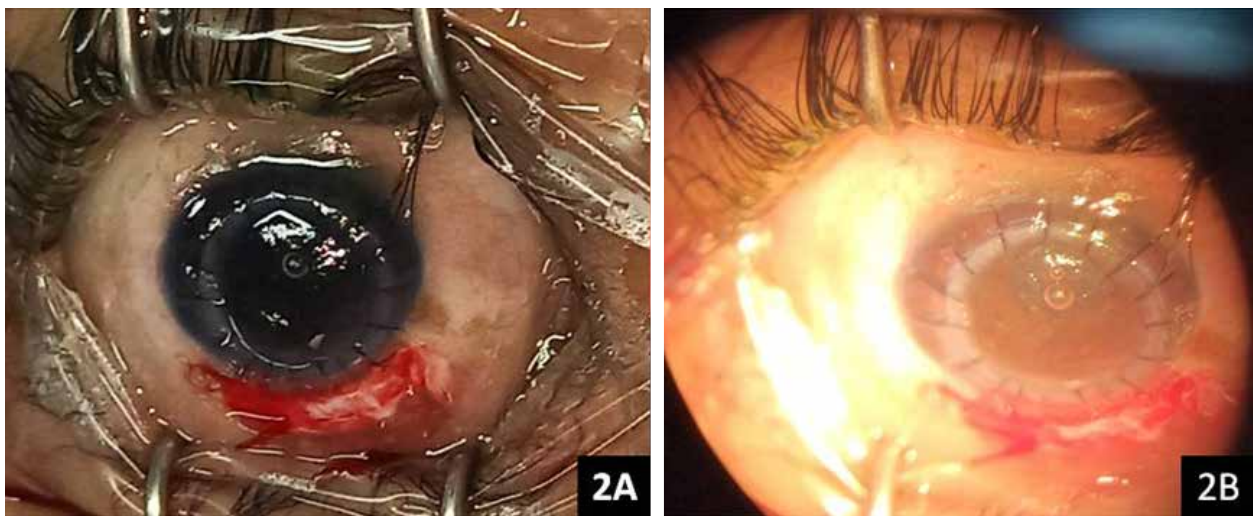
### CASE REPORT

A 10-year-old boy from terai region came with a history of painful diminution of vision which was insidious in onset and gradually progressive over 3 months. Prior to his presentation, he had consulted in an eye clinic where he was treated for an ocular allergy for redness, photophobia and itching. He did not get better and the condition was worsening. There was

no history of defective night vision, diarrhea, ocular trauma or previous surgery in either of the eyes. However, he had poor nutritional history attributed with poor economic status. On examination, best-corrected visual acuity (BCVA) was counting fingers close to face (CFCF) in both eyes with intact extra ocular motility. The Slit lamp examination revealed lusterless conjunctiva in both eyes. There was a dense infiltrate located at 5-8 o'clock position with iris plugging the perforation of size 2 mm x 2 mm in the inferior quadrant of the right eye (Figure 1A). Similarly, melting of cornea with uveal tissue prolapse was noticed at 4-8 o'clock hours' position in the left eye (Figure 1B). Anterior chamber was shallow at the perforation site in both eyes. Intraocular pressure was approximately normal on digital palpation in both eyes. The fundus details were not visible. B-scan ultrasonography was done gently through the lids in both eyes which revealed no abnormality.



**Figure 1: (A) Dense infiltrate and perforation 2 mm \* 2 mm with iris plug in the inferior quadrant of right eye; (B) Superficial melting of cornea with uveal tissue prolapse at 4-8 o'clock position of left eye.**



**Figure 2: Immediate postoperative appearance after therapeutic penetrating keratoplasty of right eye (A) and left eye (B).**

As the patient looked malnourished and after thorough clinical history he was diagnosed as bilateral keratomalacia X3B in both eyes secondary to vitamin A deficiency. The keratomalacia was managed temporarily with Bandage Contact Lens (BCL) and oral supplements of Vitamin A (2,00,000 IU Day 0, Day 1, Day 14) as per national protocol and dietary advice was given to the patient. He was advised for a physician checkup. Prophylactic topical broad-spectrum antibiotics were also prescribed. The patient was prepared for Therapeutic Penetrating Keratoplasty (TPK) for both eyes under General Anesthesia.

Both eyes underwent large TPK with donor corneal size of 8.5 mm over 8 mm size recipient's corneal trephination (Figure 2A and 2B). He was prescribed oral antibiotics and analgesics and advised for follow-up on next day and after 3 days with culture sensitivity report. The microbiological test of BCL of the right eye

revealed *Streptococcus pneumoniae* sensitive to Gentamicin, Vancomycin, Tobramycin, Cefazolin. However, no organism was isolated in culture after 72 hours in the left eye.

Postoperatively in the first week, the graft was healthy and the anterior chamber was well formed in RE whereas melting and fragile rim of recipient cornea was noticed in LE. The patient's guardian was well explained about the possibility of further intervention in the left eye and topical antibiotics and steroid were continued.

At 1 year follow-up his visual acuity improved to 6/18 in RE while LE was a pre-phthisical eye. Patient was informed and consent was taken for reporting the case in a journal.

## DISCUSSION

Corneal perforation is one among the foremost vision-threatening consequences of vitamin

A deficiency (Su et al., 2003). Vitamin A regulates mucin production which is essential for the integrity of ocular surface epithelium and ocular surface defense. All patients with rapid progressive corneal ulcer should be examined thoroughly for other signs of vitamin A deficiency. Supplementation of vitamin A should be initiated as early as possible to stop the disease progression (Heinz et al., 2004). Since our patient had a particularly poor socioeconomic status which can contribute to the event of keratomalacia secondary to vitamin A deficiency. Regarding the management of corneal perforation secondary to keratomalacia, it is often both conservative and invasive.

The conventional treatment for keratomalacia secondary to vitamin A deficiency includes bandage contact lenses, vitamin A supplementation, and cycloplegic eye drops (Feroze et al., 2021). Regarding the surgical management of perforation, to date no gold standard technique has been defined. In these conditions, TPK often creates difficulties in wound closure due to excessive thinning of mid-peripheral cornea and disparity between graft and host thickness. Additionally, pediatric eyes have decreased scleral rigidity, increased fibrin reaction and positive vitreous pressure making the procedure more challenging. Vitamin A supplementation helps in better healing of the wound. In our case, vision was

restored in the right eye but the left eye was pre-phthisical. Frequent follow-up visits and careful evaluation at each subsequent visit are needed for an honest surgical outcome. Early diagnosis and treatment of keratomalacia is vital for both vision and wound integrity. Large limbus-to-limbus keratoplasty has the advantage of avoiding placement of graft-host junctions at mid-periphery so as to promote healing and tectonic stability. However, immunological privilege of keratoplasty is lost as limbal stem cells are disrupted (Vajpayee et al., 2003). Graft suturing was still challenging as more sutures were required compared to the standard PK technique. Since no standard method has yet been defined and no large series regarding the surgical management of corneal perforation are available in the literature, one additional report could contribute to the present objective.

## CONCLUSION

Proper nutrition, early diagnosis and timely management of vitamin A deficiency is the most important preventive measure for preventable and treatable causes of blindness due to Hypovitaminosis A. Oral vitamin A supplementation and penetrating keratoplasty has better visual as well tectonic outcome.



## REFERENCES

---

- Agarwal K (2007). Eliminating vitamin A deficiency through early supplementation. *Indian Journal of Pediatrics*; 74(10): 963-4. PMID: 17978462
- Feroze KB, Kaufman EJ, Xerophthalmia.[Updated 2021 April 25] StatPearls Publishing; 2021 January.
- Heinz C, Steuhl KP, Meller D (2004). Hornhaut perforationen bei Vitamin-A-Mangel. *Der Ophthalmologe*; 101(6): 614-7. DOI: 10.1007/s00347-003-0963-3
- Smith J, Steinemann TL (2000). Vitamin A deficiency and the eye. *International Ophthalmology Clinics*; 40(4): 83-91.
- Su WY, Chang SW, Huang SF (2003). Amniotic membrane transplantation for corneal perforation related to vitamin A deficiency. *Ophthalmic Surgery, Lasers and Imaging Retina*; 34(2): 140-4.
- Thylefors B, Négrel AD, Pararajasegaram R, Dadzie KY (1995). Global data on blindness. *Bulletin of the World Health Organization*; 73(1): 115. PMID: 7704921
- Vajpayee RB, Vanathi M, Tandon R, Sharma N, Titiyal JS (2003). Keratoplasty for keratomalacia in preschool children. *British Journal of Ophthalmology*; 87(5): 538-42. DOI:10.1136/bjo.87.5.538
-