

Case report

Extreme Ophthalmomyiasis externa with simultaneous facial and scalp involvement

Syed Wajahat Ali Rizvi, Sardar Mohd Akram, Humayoun Ashraf, Mohammed Azfar Siddiqui
Institute of Ophthalmology, Jawahar Lal Nehru Medical College, India

Abstract

Background: Ophthalmomyiasis is a rare entity seen mainly in immunocompromised host with neglected wounds under poor hygienic conditions. **Case:** We report a case of extreme ophthalmomyiasis with extensive facial and scalp involvement in an old rural inhabitant following evisceration. **Conclusion:** Proper wound care and personal hygiene are of paramount importance for good wound healing.

Key words: ophthalmomyiasis, tropics, *Musca domestica*

Introduction

Myiasis is invasion of living tissue by fly larvae of the order Diptera. Involvement of eye or ocular adnexa is known as ophthalmomyiasis, and it accounts for less than 5% of all cases of myiasis (Denion, 2004). The condition is common in tropics with poor sanitation and presence of devitalised body tissue as major contributing factors.

Case report

A 60-year-old man from a rural area presented with painful swelling around eyes and scalp with discharge and crawling sensation for twelve days. The patient is known to have undergone evisceration of right eye a year ago following trauma.

On examination lids were found to be swollen and grossly inflamed with extensive tissue loss. Multiple swellings over forehead and right side of scalp [Figure 1a] with deep tissue defects filled with maggots could be seen over

lacrima sac area on both sides with exposed orbital bones (Figure 1b). No ocular structure could be identified on right side, while left eye examination was normal except for senile cataractous changes. Large tissue defects over right temple (Figure 1c) and mandibular region just below the right ear were also present. Large pockets of maggots were seen on exploration of tissue defects. Approximately 300 larvae (Figure 2) were manually removed after application of turpentine oil over a period of 4 days. The wounds were regularly cleaned and dressed; broad spectrum systemic antibiotics were also given. CT scan showed collections in ethmoid and maxillary sinuses with no evidence of maggots. The general condition of patient started to improve and wounds healed well with healthy granulation tissue over the time. The larvae were identified as those of *Musca domestica*.

Received: 27/07/15

Accepted: 09/12/15

Address for correspondence

Dr Syed Wajahat Ali Rizvi
Assistant Professor, JNMCH Aligarh, India
Email: wajahatrzv@gmail.com

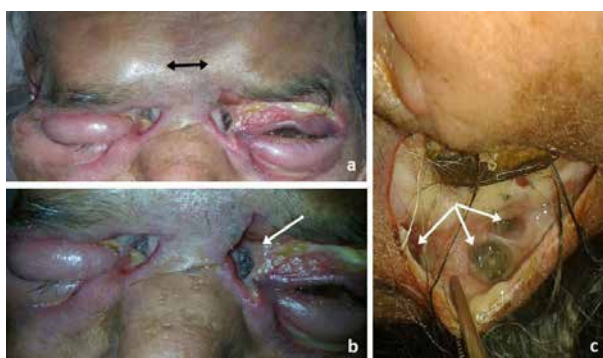


Figure 1: (a) Subcutaneous forehead collections of maggots (black arrows); (b) Periorbital tissue defects with deep maggots pockets (white arrow); (c) Large skin defect over right temple with multiple maggots pockets (white arrows)



Figure 2: Retrieved maggots from the wounds

Discussion

When larvae invade the eye, it is referred to as Ophthalmomyiasis or ocular myiasis. It can be external (lids or conjunctiva), internal (eyeball) or orbital Ophthalmomyiasis (Denion, 2004; Pandey, 2009). Flyspecies of genera *Hypoderma*, *Musca*, *Cuterebra*, *Dermatobia*, *Chrysomyia*, *Wohlfahrtia*, and *Cochliomyia* are known to cause ophthalmomyiasis in humans. *Oestrus ovis* is by far the most common cause of external Ophthalmomyiasis (Sreejith, 2010). Despite being common, infestation with *Musca domestica* is of rare occurrence (Latif, 2008; Tomy, 2013).

The treatment consists of manual removal of the larvae using turpentine oil, chloroform or ether, along with use of systemic antibiotics and proper wound care.

Ophthalmomyiasis is known to occur in tropical conditions in individuals of low socio-economic status and poor personal hygiene. The devitalised tissue, poor nutritional status and other contributing factors might have led to such presentation in our patient. We therefore conclude that proper wound care and apt sanitary conditions are highly emphasized especially in rural inhabitants.

References

Denion E, Dalens P-H, Couppie P, Aznar C, Sainte-Marie D, Carme B et al (2004). External ophthalmomyiasis caused by *Dermatobia hominis*. A retrospective study of nine cases and a review of the literature. *Acta Ophthalmol Scand*; 82: 576–584.

Latif I, Qamar RR, Attaullah I, Zaman Soomro MU (2008). Ocular myiasis. *Pak J Ophthalmol*; 24: 151-152.

Pandey A, Madan M, Asthana AK, Das A, Kumar S, Jain K (2009). External ophthalmomyiasis caused by *Oestrus ovis*: a rare case report from India. *Korean J Parasitol*; 47: 57–59.

Sreejith RS, Reddy AK, Ganeshpuri SS, Garg P (2010). *Oestrus ovis* ophthalmomyiasis with keratitis. *Indian J Med Microbiol*; 28: 399-402.

Tomy RM, Prabhu PB (2013). Ophthalmomyiasis externa by *Musca domestica* in a case of orbital metastasis. *Indian J Ophthalmol*; 61(11):671-673.

Source of support: nil. Conflict of interest: none

Letter to editor

Ideal preservation of amniotic membrane to be used in ocular surface

Sangeeta Shah, MD
Assistant Professor
Department of Ophthalmology, BPKIHS
Dharan, Nepal

Dear editor,

We read with great interest, the article “ Amniotic membrane transplantation with and without limbal stem cell transplantation in chemical eye injury” by Kafle PA, Singh SK, Sarkar I, Surin L {vol 7, no 1 (2015)} and congratulate them for the same.

However, we have some concerns and comments on the case report.

According to the author, the amniotic membrane (AM) was preserved in 100% glycerol for 3 months on whatman filter paper at a temperature of 4° C. The most common way of storing AM is in 50% glycerol that is mixed with Dulbecco’s Modified Eagle’s Medium (DMEM) in a ratio of 1:1 at a temperature of -80 degree C for several months (Lee SH et al, 1997). Even 50% glycerol alone has been used by some scientists during cryopreservation (Thomassen H et al, 2011).

Although 100% glycerol is one of the most effective biological preservation for food materials, we would like to be briefed about the method of preservation of AM in 100% glycerol and its outcome in this case since there’s scarcity of the data about using 100% glycerol as an intermediate storage for amniotic membrane. There’s also a question of viability of the membrane (Prabhasawat P et al, 2000, 2001)

It is to be noted that even though glycerol is a cryoprotective agent, due to its high osmotic pressure it extracts interstitial water from the amniotic membrane. Therefore, preservation in cold glycerol consists of 80% glycerol which is used for drying the AM and then preserved at 4 ° C for few weeks. This method causes loss of some of its biologic properties and is thus used for dressing burn wounds (Baradaran-Raffi A, 2007). But then, its low-cost and simple method may be suitable for developing countries (Maral T et al, 1999)

It has also been seen that amniotic membrane laid on filter paper instead of nitrocellulose acetate paper contains fibres when using it. Did the surgeon face any such problem?

References

Baradaran-Raffi A, Aghayan H-R, Arjmand B, Javadi M (2007). Amniotic membrane transplantation. Iran J Ophthalmic Res. 2(1):58-75.

Address for Correspondence

Sangeeta Shah, MD
Assistant Professor
Department of Ophthalmology, BPKIHS
Dharan, Nepal
Email: drsangeetashah@hotmail.com
Phone no: 9841411036



Lee SH, Tseng SC (1997). Amniotic membrane transplantation for persistent epithelial defects with ulceration. *Am J Ophthalmol.* 123:303-12.

Maral T, Borman H, Arsalan H (1999). Effectiveness of human amnion preserve long term in glycerol as a temporary biological dressing. *Burn.* 25:625-635.

Prabhasawat P, Kosrirukvongs P, Booranapong W, VajaradulY(2000). Application preserved human amniotic membrane for corneal surface reconstruction. *Cell Tissue Bank.* 1:213-22.

Prabhasawat P, Tseng SC (2001). Impression cytology study of epithelial phenotype of ocular surface reconstructed by preserved human amniotic membrane. *Arch Ophthalmol.* 115:1360-7.

Thomasen H, Pauklin M, Noelle B, Geerling G, Vetter J, Steven P, et al(2011). The effect of long-term storage on the biological and histological properties of cryopreserved amniotic membrane. *Curr Eye Res.* 36:247-55. Epub 2011 Jan 28.

Source of support: nil. Conflict of interest: none