

Original Article

Bal K Thapa, MS

BP Koirala Memorial Cancer Hospital
Bharapur, Chitwan
Chitwan Hospital Pvt Ltd and Alive Hospital Pvt, Ltd
Bharatpur, Chitwan

Address for correspondence:

Bal K Thapa, MS
BP Koirala Memorial Cancer Hospital
Bharapur, Chitwan
Chitwan Hospital Pvt Ltd and Alive Hospital Pvt, Ltd
Bharatpur, Chitwan
Email: drbkthapa2002@gmail.com

Received, 21 April, 2016

Accepted, 6 May, 2016

Is Open Lumbar Micro-Discectomy Safe at Periphery of Nepal ?

Lumbar disc surgery is performed exclusively for disc herniation. Either low back pain, or sciatica or both are common presentations depending upon the levels of compressed nerve roots. Indications for surgery and MRI needs to be carefully judged upon keeping the economic status of our patients into consideration. Open lumbar (micro) discectomy is safe and successful method for lumbar disc herniations at periphery. Results in these hundred thirteen initial cases with minimum follow up of 5 years indicate that this is not only feasible but safe in these 57 males and 56 female patients aged between 12 and 93. Redo surgeries were not that difficult in this series and were safe. There were 18 cases with Multiple and 95 single levels. Of the single levels it gradually increased as the level gradually decreased in terms of the vertebral counts. L3/4: 3 cases, L4/5: 28 cases and L5/S1 : 64 cases . There were 18 cases of more than one level discs. There were 96 (Micro) discectomies, 11 Laminotomies and 6 Laminectomies.

Key Words: Lumbar disc surgery, periphery, safe discectomy

Low back pain is common in Nepali community more so in the periphery. Current or chronic pain was present in 50.1% of the Eastern Nepali sample population (n=882) of which 61.0% were women and 39.0% were men.¹ There will be hardly any person who doesn't have at least one episode of Low back pain in life time, in the western population at least 80%.⁷ There is no single most cause for the low back pain. But it is hypothesized that this is the result of us being bipedal from four pedal animals. At times it used to be considered a disease of porters and armies. But now a day by no means it is restricted. Our own experience states as early as 12 year of age and as much as 93 years of age people have been operated for Lumbar disc herniation. And a man of 103 has been recorded to have significant lumbar disc herniation. In the past patients would have been operated

on the clinical ground that followed Myelogram based surgery which revolutionized in lumbar disc surgery. Though CT scan is not that good for disc it gives good picture of the bones and lateral recess stenosis. Today most of us agree that it should be operated on the basis of MRI wherever available and possible. Failure of medical treatment, intolerable low back pain, and cauda equina syndrome are common indications.^{3,6} At present most of the time it is the doctor patient joint decision is very crucial for lumbar disc surgery. Most of the time L5/S1 followed by L4/5 are the sites operated for herniated intervertebral disc (HID). Even though Chitwan is now metropolis, at the beginning of this surgery it was not more than at any rural periphery of Nepal, so far as adequate set up for Neurosurgery is concerned. Still at the level of mentality and management level it is considered a periphery. As we

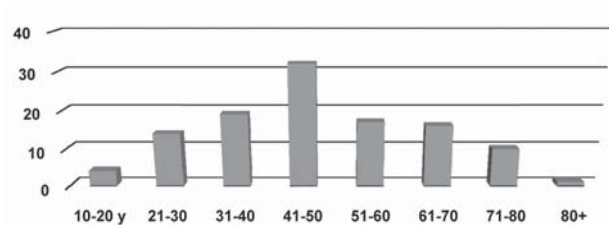


Figure 1: Age distribution of the patients (n=113)

perceive the periphery is not a remote location or distance from capital it is the social and technical set ups. I had to operate with a handful of general rather than specific equipments, without any aid of intraoperative imaging (x-ray or fluoroscopy) for localization. Locally made retractors were used, the almery chair was leg cut and fitted for the knee chest position to the operation table etc.

Materials and Methods

A prospectively collected data were analyzed retrospectively so that the minimum follow up would be 4 years and based on this the initial 113 cases of open (micro) lumbar disc surgery are included in this analysis. These are all operated between 2005 to 2011 AD in private hospitals of Chitwan (Chitwan Hospital Pvt Ltd and Alive Hospital and trauma center, Pvt Ltd). Digital photos, videos and discharge records all were analyzed. In addition to the clinical judgment, x-ray and MRI were chosen for the diagnosis. All patients had pre operative MRI. Operating loupes were used in place of Microscope.

Data gathered were enlisted in Microsoft x-cel and the analyzed.

Summary of Treatment protocol

This has remained same from the beginning as set in, 2005AD. Clinical Sciatica + x ray positive (meaning there is suspicion of disc or canal stenosis), were investigated with MRI, a trial with conservative management for about 6 weeks. That includes Physio &/or Acupuncture. A clinical sciatica with MRI negative for or minor disc bulge were treated with Physio/ Acupuncture/ &/or Epidural steroids before Decompressive surgery. Clinical Sciatica with MRI Positive for disc herniation were tried with Medication and physio, acupuncture followed by surgery

Caste	No of patients
Brahmin	50
Chetri	26
Baisya	19
Sudra	18

Table 1: Frequency of HID among different castes

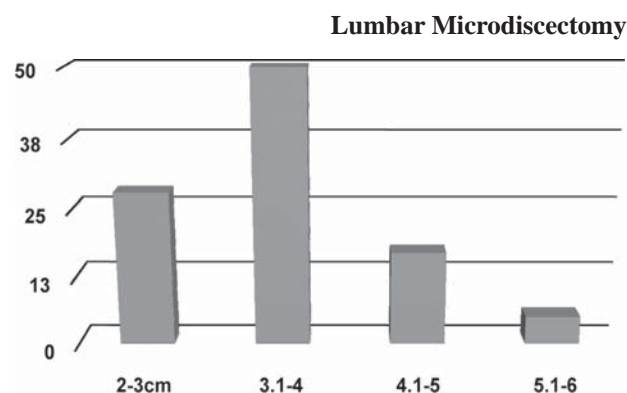


Figure 2: size of the incision

if needed except in cases of cauda equine syndrome. weakness and neural claudication were subjected for surgery. Common Indication for an MRI in this series were Typical sciatica not responding to NSAID and Failed conservative management, Presence of cord and /or root signs or Bladder and / or bowel involvement.

Purely disc disease were treated with fenestration and discectomy, spinal stenosis with bilateral sciatica were treated with laminectomies and tight lateral recess were treated with discectomy and foraminotomy with or without minimal laminotomy. The recess stenosis was judged intraoperatively by passing a nerve hook after discectomy.

Results

There were 57 males and 56 females. Right side was involved in 63% cases. Most of patients were in economically productive age group (31-60years) (Figure 1). There were 18 cases with multiple levels (17 with two and one at three). Incisions were Minimum 2.5cm and maximum 6 cm, half the cases had 3-4 cm long incision while three quarter had less than 4 cm incisions. 2-3cm in 28% , 3.1-4cm in 50%, 4.1-5cm in 17% and 5.1-6 cm in 5% patients (Figure 2). We did not do a formal analysis but the general impression is smaller the incision early is acceptance for post op mobilization, There is no

Symptom	Frequency	remarks
Sciatica + back pain	92	Back pain with radiation included
Back pain only	7	
Neural claudication	9	With or without back pain
Weakness / foot drop	3	
Cauda equina syndrome	2	With bladder involvement

Table 2: Primary Clinical presentation

Thapa

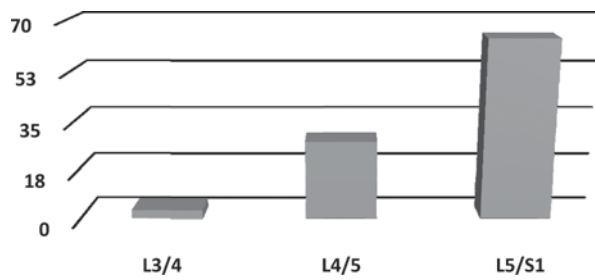


Figure 3: Level of involvement

difference in hospital stay (5 days) though. One case had Tarlov cyst as well.

Most common level being L5/S1 followed by L4/L5 (Figure 3). Multiple level : 18, (two level : 17 and three level : 1), L3/4: 3, L4/5: 28, L5/S1 : 64 Open (micro) discectomy with fenestration was done in 96 cases while Laminotomy in 11 cases and Laminectomy in 6 cases. The district wise distribution was as follows, Chitwan : 61, NP: 20, Rupandehi:8, Makwanpur : 6, Dhading: 4, Kavre: 2, Dang: 2 and Other :11 (Figure 4). Other includes one each from 9 districts and one from UK and One from Japan. Western limit was Banke and eastern limit was Morang districts. Interestingly the Brahmins were operated more frequently than the others according to our social caste system. Table 1 shows the frequencies among other castes. There is no reason other than education and awareness in addition to affordability to this even very cheap surgery here in. Table 2 shows the Primary Clinical presentation

Following success stories reflect the safety profile in this series from periphery.

The first ever case 2062 BS was L5/S1 discectomy, and was done in a guy coming from Japan. With frank saying that he was my first patient in Chitwan to get open lumbar (micro) discectomy. He is now in USA and comes for follow up every 3 years.

A 30-year-old male patient had previously been operated for the same problem came with a sudden severe agonizing pain. Orthopedician referred the case as reoperation was not possible in his hand, was successfully operated (24/3/2065), but the problem was with a big skin incision, and it was hard for me to find the evidence of deeper incision in Muscle and ligaments in the past. After removal of the disc in an emergency surgery, this man is

Outcome	Nos
Excellent	99
Good	10
Fair	4
Poor	0

Table 3: Outcome

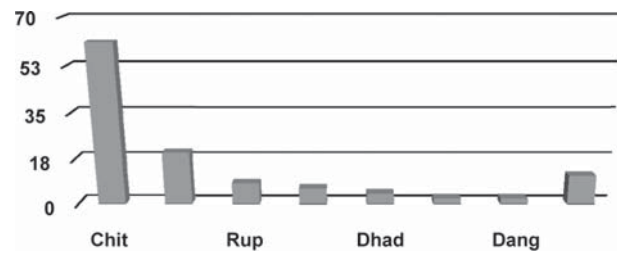


Figure 4: District wise distribution

farming with 7 buffaloes for last 7 years.

A twelve year old girl from western Nepal had L3/4 disc (30/3/2065) and a 78 year old male from same region with multilevel disc disease which were treated surgically with good results, thus clearing up of the issue of age bar in disc surgery.

A teacher by profession had been operated for lumbar disc and was bed ridden for at least 2 years with his foot drops, was re-operated (2064BS), the adhesions were removed with removal of residual disc. Now any one can witness his motorbike ride and kicks every day completing his service to earn the pension in Nawal parasi. Another redo case, operated somewhere else, with a big scar, came for acute severe pain and got operated with success.

An interesting event has occurred in one of the disc surgery in this series. A cardiac patient being treated from cardiologist, then based in Kathmandu had been decided for a discectomy. Just before the surgery there were more than 32 people gathered to ask for the risk and success of the surgery in her. They were counseled for at least 35 minutes and finally a new guy who did not participate in counseling comes and asks to contact cardiologist in Kathmandu right then and take his word of guaranty that cardiac condition would by no means affect her surgical outcome. I had then disagreed to operate on her but she cried in our front asking for surgery at any cost. Then I asked all the people present to sign in a consent form for me to operate in her. More than half of them disappeared and 16 of them signed in the consent form. She is on regular follow up without any problem related to surgery in her 6 year follow up now.

There was no mortality in this series due to surgery or directly related to surgery. One patient of note here had developed tingling after 3 months of surgery and on MRI done casually by another neurosurgeon showed a Peripheral Nerve Sheath Tumor. Post of Histopathology showed malignant peripheral nerve sheath tumor and she was given radiotherapy. She died after 9 months of radiotherapy. There was no significant infection of the wound except one stitch abscess.

Outcomes were rated as excellent (early recovery no complication at 3 months, and no disability), Good

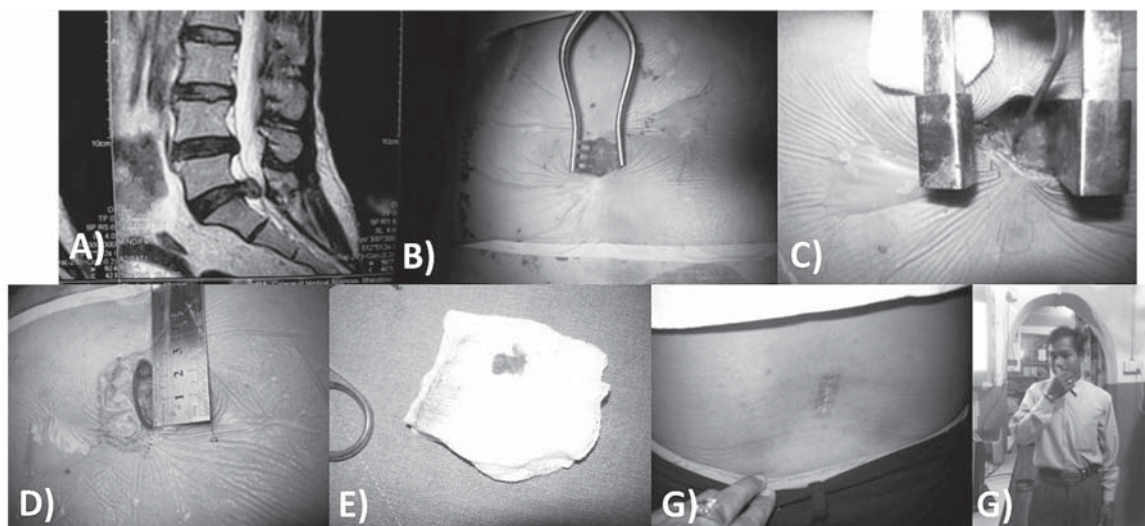


Figure 5: Steps of operation, this typically shows the gross steps in open (micro) discectomy at periphery, A)MRI L5/S1 Disc, B) Incision, C) decompressed root, D)size of incision, E)Disc removed, F)Scar, G)Pt at Follow up

(early recovery with some post op complaints but no complications) Fair, (post op complications but no disability) and poor (With disability) all on a clinical and radiological ground. The outcome results were as shown in **Table 3**.

Having illustrated all these events, it is not that easy for anybody to operate and motivate people to get operated at periphery for lumbar disc surgery for several reasons. It's not the money that matters it is the concept and content of the society and so called intellectuals who hate themselves, are the constraints for the periphery to remain under developed in all respects more so for medical practice.

There is a paucity of literatures from Nepal to compare the results of open (micro) Lumbar disc surgery particularly from the periphery.

Complications

Altogether 7 patients had complications. 4, had discitis including one delayed after 2 months : 2 had back pain developed later and one had persistent pain at 3 months, all of them improved with time and conservative treatment.

Discussion

Controversy remains for the treatment of low back pain except in case of cauda equine syndrome.² The cause of disc herniation remains obscure in many patients. The loss of flexibility and ability to absorb the physical forces by the disc has been accepted as the main pathophysiology.⁸ There is more evidence coming up for the differentiation in the conservative, nonsurgical and surgical management of the disc herniation and low back pain. More and more less invasive procedures like endoscopic and needlosopic

discectomies are coming up in practice. These less invasive procedures have better immediate recovery and satisfaction but evidence regarding the effectiveness is insufficient⁹ in comparison to open discectomies. In the context of Nepal particularly in periphery open discectomy remains the most feasible and safe. Alternative medicine for the management like AYUSH has been rated with variable success but most of them are non surgical candidates and difficult to compare with surgical procedures.^{4,5,10}

Conclusion

It is clear that there is a very high need of lumbar disc surgery at periphery. Despite a great possibility and prospect of this surgery it is very limited in the periphery. The concept and the content of the society is so diverse and detrimental at times one need to select cases very well. Most of the peripheral set ups do not have high resolution microscopes but they can always use magnifying loupe for the purpose, making the surgery cheaper and better. Lumbar disc surgery doesn't ask for high level of competence but it demands a very high level of conscience and attention with each seconds' critical awareness. Finishing surgery and making patients able to walk doesn't complete a surgeons job, they need to be followed up sufficiently enough years after it. Complications are bound to happen. Absence of complications should raise some suspicion of not having enough number of cases operated or something else including the greatest luck. Lumbar disc surgery at periphery is safe technically, but at times not safe sociopolitically for the fact that there have now been professional dealers available for medical practice and non judicial suits in this country.

Thapa

Acknowledgements

My anesthesiologists and anesthesia technician colleagues need acknowledgment for their involvement in the surgery and Neurosurgeons Dr. Benju Rashmi Pradhan and Dr. Binod Bhattarai, and Medical officers Dr. Hari Saran Malakar are thankful for their assistance in some surgeries.

References

1. Bhattarai Balkrishna, Paras K Pokhrel, Mukesh Tripathy et al. Chronic Pain and Cost: An epidemiological study in the communities of Sunsari District of Nepal. **Nepal Medical College Journal** **9 (1)**: 8-15, 2007
2. Borczuk, Pierre. An Evidence-Based Approach to the Evaluation and Treatment of Low Back Pain in the Emergency Department. *Emergency Medicine Practice* **15 (7)**: 2013
3. Chou R, Baisden J, Carragee EJ, Resnick DK, Shaffer WO, Loeser JD. Surgery for low back pain: a review of the evidence for an American Pain Society Clinical Practice Guideline. **Spine** **34 (10)**: 1094–1109, 2009
4. Dagenais S, Mayer, J; Wooley, J; Haldeman, S. “Evidence-informed management of chronic low back pain with medicine-assisted manipulation”. **The Spine Journal** **8 (1)**: 142–149, 2008
5. Dagenais, S Gay, RE; Tricco, AC; Freeman, MD; Mayer, JM. NASS Contemporary Concepts in Spine Care: spinal manipulation therapy for acute low back pain. **The spine journal**: **10 (10)**: 918–940, 2010
6. Henschke N, Ostelo RW, van Tulder MW, et al. Behavioral treatment for chronic low-back pain”. *Cochrane Database of Systematic Reviews* . CD002014. PMID 20614428. 2010
7. Low back pain fact Sheet, National Institute of Neurological Disorders and Stroke. Pubmed, 2016
8. Manusove EG. Evaluation and diagnosis of low back pain. **Prim. Care** **39 (3)**: 471-479, 2012
9. Manusove EG. Surgical treatment of low back pain. **Primary care** **39 (3)**: 525–531, 2012
10. Rubinstein SM, van Middelkoop M, Assendelft WJ, de Boer MR, van Tulder MW. Rubinstein, Sidney M, ed. “Spinal manipulative therapy for chronic low-back pain”. *Cochrane Database of Systematic Reviews*(2): CD008112. Pub2 . 2011