

An Infant with Infected Cephalohematoma


Shodip Shrestha MBBS¹, Bibesh Pokhrel MS², Amit Thapa MCh³

^{1,2,3}Department of Neurosurgery, Kathmandu Medical College Teaching Hospital, Kathmandu, Nepal

Date of submission: 8th September 2020

Date of acceptance: 13th November 2020

Date of publication: 1st December 2020



Abstract

Cephalohematoma is a benign medical condition affecting 1 to 2% of all live births, which resolves spontaneously in most of the cases. Infected cephalohematomas are very rare and serious as they can cause sepsis, osteomyelitis and meningitis.

We report a case of a 40-day male who presented to our outpatient clinic with ruptured scalp swelling. Deep seated scalp abscess was incised and drained. Culture proved E.Coli infection which was managed with intravenous antibiotics for five days during hospital stay and was later discharged on oral antibiotics. The wound completely healed with no evidence of residual abscess on 1-week follow-up.

Infected cephalohematoma has a good prognosis if appropriately drained and managed on culture guided antibiotics.

Key words: Cephalohematoma, *Escherichia coli*, Infant, Infected cephalohematoma

Introduction

Cephalohematoma (CH) is the collection of blood between the periosteum and the skull, which is confined to the boundary of the underlying bone without crossing the suture lines or midline. It is secondary to rupture of emissary and diploic veins crossing the periosteum, leading to accumulation of blood or serosanguineous fluid.¹ Since the bleeding is gradual, CH takes hours to days to develop and might not be evident at birth. The incidence of CH accounts for 1-2% during

spontaneous vaginal delivery, which increases to 3-4% in cases where there is a need of using forceps or other vacuum assisted devices due to prolonged second stage of labor.² Normally, it resolves itself over weeks to months but can get infected spontaneously, through skin lesion or secondary to needle aspiration.³

Case report

Our index case was born to a 30-year, primi-gravida female at 40 weeks of gestation through vaginal delivery with episiotomy. During delivery, the 2nd stage of labor was prolonged. A fluctuant swelling was seen at birth which gradually increased in size. Ultrasound of the head on the 12th day revealed collection of fluid in the right parieto-occipital area with size of 6.5cm x 1.9cm x 6.2 cm, for which warm compression was advised. His total bilirubin on the same day was 171umol/L (10mg/dl) which gradually resolved on phototherapy. On the 35th day of life, she developed fever and oral antibiotics were started. After 5 days of antibiotics, the patient's mother presented to our neurosurgical clinic. Physical examination revealed an afebrile and well-appearing infant with a large, boggy, uniform, fluctuant swelling on the right parieto-occipital region of the scalp (Figure 1). Ultrasound was repeated which showed hematoma size of 4.9cm x 3.7cm x 1.7cm (Figure 2). Patient's mother was advised for admission but she refused.

On the subsequent day, the patient again presented to the clinic after gross rupture of the scalp swelling (Figure 3).

On examination, overlying skin was red, tender, deep seated abscess was found which was drained and pus

Access this article online

Website: <https://www.nepjol.info/index.php/NJN>

DOI: <https://doi.org/10.3126/njn.v17i3.33131>

HOW TO CITE

Shrestha S, Pokhrel B, Thapa A. An Infant with infected Cephalohematoma. NJNS. 2020;17(3):68-70



¹ORCID id: 0000-0003-1867-599X

²ORCID id: 0000-0002-1997-9859

³ORCID id: 0000-0003-1896-3115

Address for correspondence:

Prof Dr. Amit Thapa
Department of Neurosurgery,
Kathmandu Medical College Teaching Hospital,
Sinamangal, Kathmandu, Nepal
E-mail: dramitthapa@yahoo.com
Phone: +977-9851177995

Copyright © 2020 Nepalese Society of Neurosurgeons (NESON)

ISSN: 1813-1948 (Print), 1813-1956 (Online)



This work is licensed under a Creative Commons Attribution-Non Commercial 4.0 International License.

sent for culture. *Escherichia coli* was isolated; culture based intravenous antibiotics (Intravenous Cefotaxime) was given for 5 days. She was later discharged on oral antibiotics (Syrup Amoxicillin and Clavulanate). On 1-week follow-up, the wound was found to be completely healed (Figure 4).

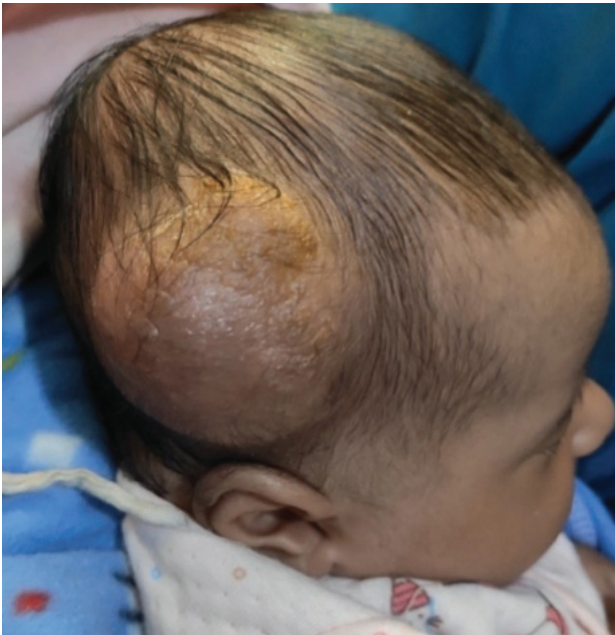

Figure 1: Right parieto-occipital scalp swelling

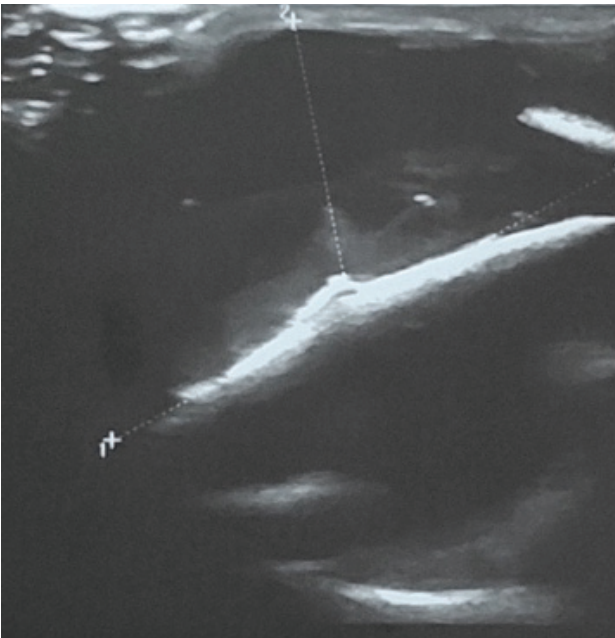


Figure 2: Ultrasound of the scalp swelling measuring 5cm x 5cm

Discussion

Occurring in 1-2% of all deliveries, cephalhematoma are caused by traumatic rupture of subperiosteal vessels and

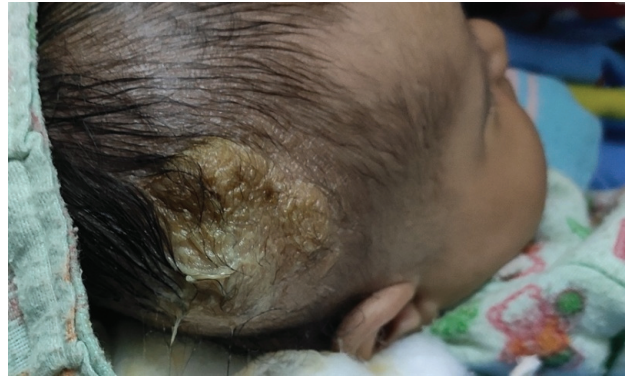

Figure 3: Rupture of previous right parieto-occipital swelling

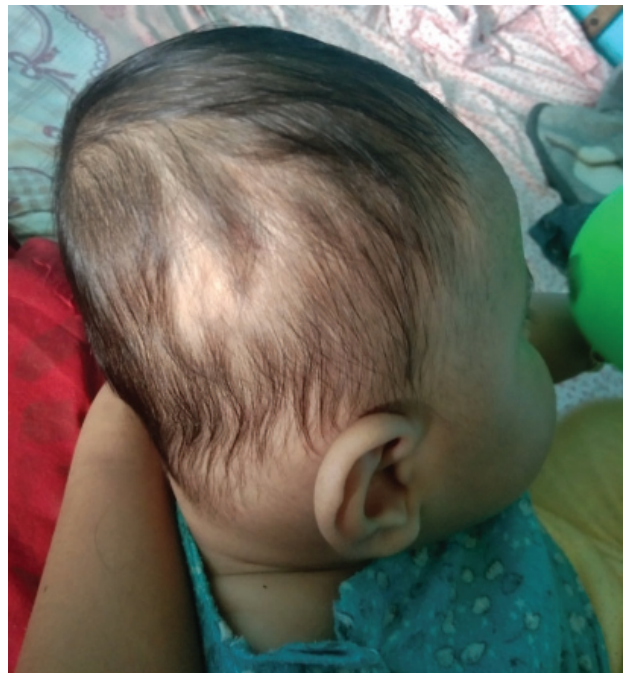

Figure 4: Condition of the index case after 3 months

are more common when the delivery is assisted by forceps, vacuum or scalp electrode.^{2,4} Most cephalhematoma resolve spontaneously within weeks and infection is a rare complication. In addition to instrumentation-assisted delivery, risk factors for infected cephalhematoma include neonatal bacteremia with secondary seeding and overlying cellulitis.^{4,5} Early infection within the first two weeks of life is often the result of hematogenous seeding, whereas infection of a cephalhematoma after 3 weeks is typically related to an overlying cellulitis.⁵ In a retrospective study of 28 cases, *E. coli* is the most common pathogen isolated from infected cephalhematoma and accounts for 57% of cases.⁶ Although other common pathogens are *S. aureus* and *Proteus spp.* However, infection due to Group E *Salmonella*, Coagulase-negative *Staphylococcus*, Group B *Streptococcus*, *Klebsiella pneumoniae*, *Streptococcus*

pneumonia, *Morganella morganii* and *Escherichia hermannii* have also been reported.^{3,4,6,7}

The differential diagnosis of an infantile scalp swelling includes liquefying cephalhematoma forming a seroma, vascular tumors and malformations such as infantile hemangiomas and lymphatic malformations, benign and malignant neoplasms, such as myofibromas, congenital juvenile xanthogranulomas and rhabdomyosarcomas. Furthermore, panniculitis, such as subcutaneous fat necrosis of the newborn and embryologic cysts with an abscess, such as dermoid cysts may be considered.⁸

Presentation of infected cephalhematoma varies from purely local findings suggestive of infection, such as erythema, fluctuance, tenderness and purulent discharge to systemic manifestations, such as fever, irritability and jaundice.^{2, 9,10} Serious complications of infected cephalhematoma include sepsis, meningitis, osteomyelitis and death.⁶ Surgical drainage and antibiotic therapy guided by cultures is standard therapy. When osteomyelitis is suspected, magnetic resonance imaging is preferred imaging modality and debridement of underlying necrotic bone is treatment modality.^{2,4,6} Likewise, when meningitis is suspected, a lumbar puncture is an important diagnostic tool and treatment should include antibiotics with penetration of the blood-brain barrier.^{6,7,10,11}

Conclusion

Infection of cephalhematoma, though rare, should be considered when abscess is formed. *Escherichia coli* is the most common pathogen. Surgical drainage and culture based antibiotics provides best results.

Conflict of Interest: None

Source(s) of support: None

References

1. Raines DA, Krawiec C, Jain S. Cephalohematoma. 2020 Aug 13. In: StatPearls [Internet]. Treasure Island (FL): StatPearls Publishing; 2020 Jan. PMID: 29262234.
2. Kao HC, Huang YC, Lin TY. Infected cephalohematoma associated with sepsis and skull osteomyelitis: report of one case. *Am J Perinatol*. 1999;16(9):459-62. <http://doi.org/10.1055/s-1999-6803>
3. Staudt MD, Etarsky D, Ranger A. Infected cephalohematomas and underlying osteomyelitis: a case-based review. *Child's Nervous System*. 2016;32(8):1363-9. <http://doi.org/10.1007/s00381-016-3084-4>
4. Listinsky JL, Wood BP, Ekholm SE. Parietal osteomyelitis and epidural abscess: a delayed complication of fetal monitoring. *Pediatric Radiology*. 1986;16(2):150-1. <https://doi.org/10.1007/bf02386641>
5. Wong CS, Cheah FC. Cephalhematoma infected by *Escherichia coli* presenting as an extensive scalp abscess. *Journal of Pediatric Surgery*. 2012;47(12):2336-40. <http://doi.org/10.1016/j.jpedsurg.2012.09.029>
6. Chang HY, Chiu NC, Huang FY, Kao HA, Hsu CH, Hung HY. Infected cephalohematoma of newborns: Experience in a medical center in Taiwan. *Pediatrics International*. 2005;47(3):274-7. <https://doi.org/10.1111/j.1442-200x.2005.02062.x>
7. Dahl KM, Barry J, DeBiasi RL. *Escherichia hermannii* Infection of a Cephalohematoma: Case Report, Review of the Literature, and Description of a Novel Invasive Pathogen. *Clinical Infectious Diseases*. 2002;35(9):e96-e98. <http://doi.org/10.1086/342304>
8. Wang JF, Lederhandler MH, Oza VS. *Escherichia coli*-infected cephalohematoma in an infant. *Dermatol Online J*. 2018 Nov 15;24(11):13030/qt456083v1. PMID: 30695981
9. Mohon RT, Mehalic TF, Grimes CK, Philip AG. Infected cephalhematoma and neonatal osteomyelitis of the skull. *Pediatr Infect Dis*. 1986;5(2):253-6. <http://doi.org/10.1097/00006454-198603000-00018>
10. Blom NA, Vreede WB. Infected cephalhematomas associated with osteomyelitis, sepsis and meningitis. *Pediatr Infect Dis J*. 1993;12(12):1015-7. <http://doi.org/10.1097/00006454-199312000-00011>
11. Weiss KJ, Edwards MS, Hay LM, Allen CH. *Escherichia coli*-infected cephalohematoma in an infant. *Clin Pediatr (Phila)*. 2009;48(7):763-6. <http://doi.org/10.1177/0009922809335669>