

A rare case of brain metastasis

Vijay Kumar Gupta *MCh*¹, Neeraj Basantani *MCh*², AS Carvalho *MCh*³, Ekata Gupta *MBBS*⁴, Nitesh Kumar Goyal *MCh*⁵


¹Department of Neurosurgery, National Institute of Medical Sciences and Research, Jaipur, India,

²Department of Neurosurgery, Ram Raghu Hospital, Agra, India, ³Department of Neurosurgery, Command Hospital, Lucknow, India, ⁴Health Care Clinic, Shree Gopal Nagar, Jaipur, India, ⁵Department of Plastic Surgery, Santokba Durlabhji Memorial Hospital, Jaipur, India

Date of submission: 1st November 2019

Date of acceptance: 11th June 2020

Date of publication: 12th August 2020



Abstract

Head and neck squamous cell carcinoma metastasis to brain is unusual and rare. We present a case of a 61-year-old man with a primary oral squamous cell carcinoma who was referred to our department for evaluation of decreased sensorium and hemiparesis. Magnetic resonance imaging of the brain revealed a ring enhancing central hypo-intense lesion with surrounding perilesional oedema on T1WI in the left frontal lobe. Left frontal craniotomy with gross total tumour removal was performed. Histopathological examination confirmed metastatic squamous cell carcinoma. The patient was subsequently offered adjuvant radiation therapy. To the best of our knowledge, few such cases have been reported.


Key words: Brain metastasis, Craniotomy, Oral squamous cell carcinoma, Radiotherapy

Introduction

Metastases to the brain from oral squamous cell carcinomas (OSCC) are rare, probably due to the protection provided by the blood brain barrier. Very few cases have been reported till date.^{1,2} In contrast, direct intracranial invasion of the skull base is not uncommon in

patients with locally advanced head and neck carcinoma.³ There is an increase in the incidence of brain metastases from head and neck carcinoma, which may be due to advancements in the treatment and earlier detection of systemic disease using more sensitive imaging modalities.⁴ The incidence of brain metastases from head and neck malignancy is as follows: hypopharynx (60%, highest incidence), base of tongue (53%) and the anterior tongue (50%).⁵ Squamous cell carcinoma metastasize to brain rarely, however common locations for brain metastases are from lungs (80%), mediastinal nodes (34%), liver (31%) and bones (31%).⁶ Therefore, preoperative tumour staging should be done using relevant investigations like CT scan of chest, ultrasound of the liver focuses and radionuclide bone scan. In the following case study, we present a patient who developed a histopathological examination (HPE) confirmed brain metastasis from squamous cell carcinoma (SCC) of tongue. The patient presented with symptoms of cerebral metastasis, 12 months after the primary disease.

Access this article online
Website: https://www.nepjol.info/index.php/NJN
DOI: https://doi.org/10.3126/njn.v17i2.30167
HOW TO CITE
Gupta VK, Basantani N, Carvalho AS, Gupta E, Goyal NK. A rare case of brain metastasis. <i>NJNS</i> . 2020;17(2):55-59



¹ ORCID id: 0000-0002-3959-3363

² ORCID id: 0000-0003-3974-5723

³ ORCID id: 0000-0001-9558-7008

⁴ ORCID id: 0000-0002-3365-5148


⁵ ORCID id: 0000-0003-3329-8168

Address for correspondence:

Dr. Vijay Kumar Gupta
K-301, Pearl Green Acres,
Shree Gopalnagar, Gopalpura Bypass,
Jaipur, Rajasthan, India-302019
Contact number: +91-9602702924
E-mail: drvijaygupta.neurosurg@gmail.com

Copyright © 2020 Nepalese Society of Neurosurgeons (NESON)

ISSN: 1813-1948 (Print), 1813-1956 (Online)

 This work is licensed under a Creative Commons Attribution-Non Commercial 4.0 International License.

Case description

A 61-year-old man presented with a year long history of painless ulcer on right tongue which was gradually increasing in size, was referred to the surgical oncology department. Following the confirmation with biopsy, the oncosurgeon decided to perform a radical surgical resection of ulcer with supraomohyoid and functional neck dissection in-continuity and reconstruction with a radial forearm free flap and split skin graft (SSG).

Histopathological study revealed an invasive well-differentiated squamous cell carcinoma of tongue stage pT2N0Mx (Figure 1).

Histopathology staging was reported as pT-3.8 x 2.5 x 1cm, well differentiated squamous cell carcinoma, depth of infiltration 11mm, cut margin free, PN1 negative, LV1 negative, LN 0/27 involved. Adjuvant radiotherapy was then planned using cobalt 3DRT technique with a total dose of 60Gy delivered in 30 fractions over 6 weeks to both sides of the neck and face (including primary site). Post radiotherapy, he remained stable and complaint-free for about a year after which he developed right sided hemiparesis and altered sensorium. He underwent further investigations to determine the nature and severity of the disease.

MR imaging revealed a large cystic lesion in the left

frontal lobe showing peripheral irregular enhancement and perilesional vasogenic oedema causing midline shift toward right side (Figure 2).

The patient's tumor was re-staged as T3N3M1 for which surgical resection was advised. Preoperative computed tomography (CT) of the chest was normal. A craniotomy was performed and microscopic gross total excision of the tumour (Figure 3) was achieved.

Histopathology revealed a well differentiated metastasis of the primary OSCC (Figure 4).

The patient was advised whole brain radiation therapy (30Gy) which he refused. He survived for 10 months and succumbed later due to progression and pulmonary spread of the disease. There was no cerebral recurrence of the lesion (Figure 5).

Discussion

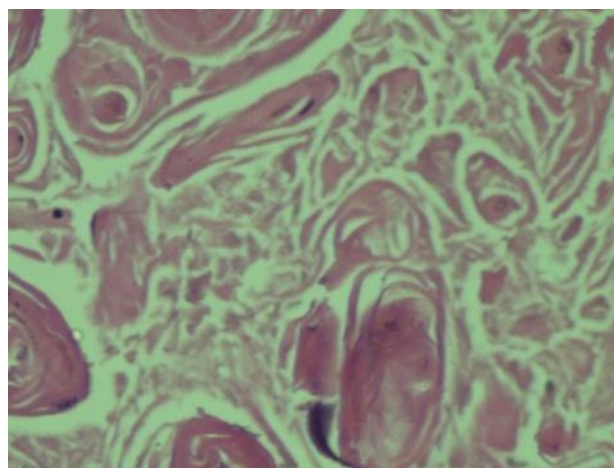
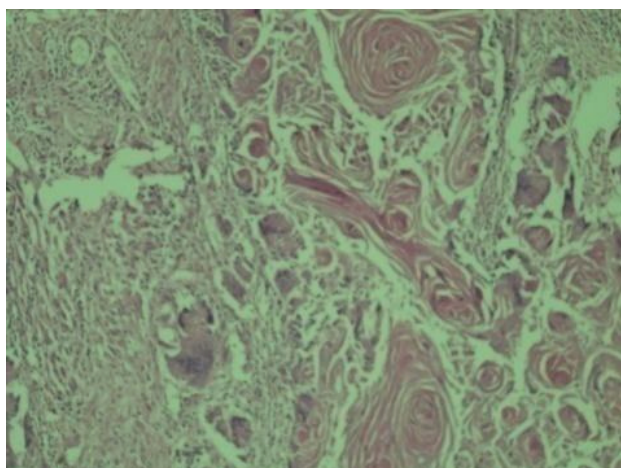


Figure 1: Histology of 10X & 40X view of Squamous cell carcinoma of tongue, 5 µm thick serial sections of primary tumour were stained with H&E. Sections showing keratin pearls and dysplastic squamous cell

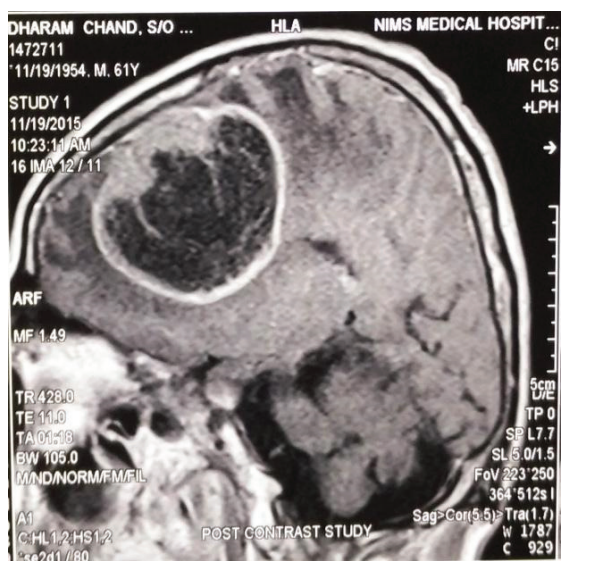
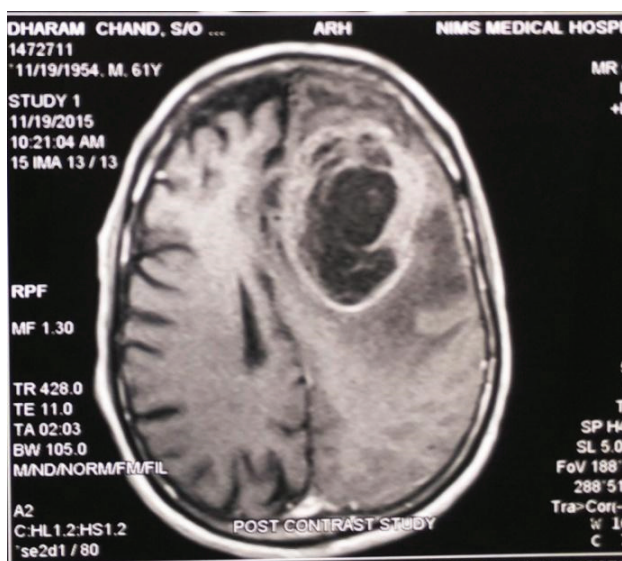


Figure 2: Axial (a) and sagittal (b) magnetic resonance scans (T1WI with Gd) reveal a large cystic lesion in the left frontal lobe showing peripheral irregular enhancement and perilesional vasogenic oedema causing midline shift toward right side

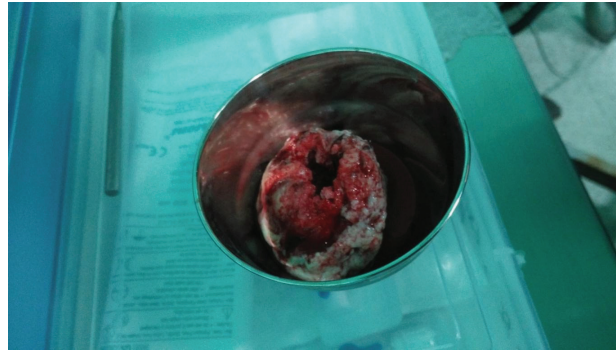


Figure 3: Specimen of brain tumor following gross total excision

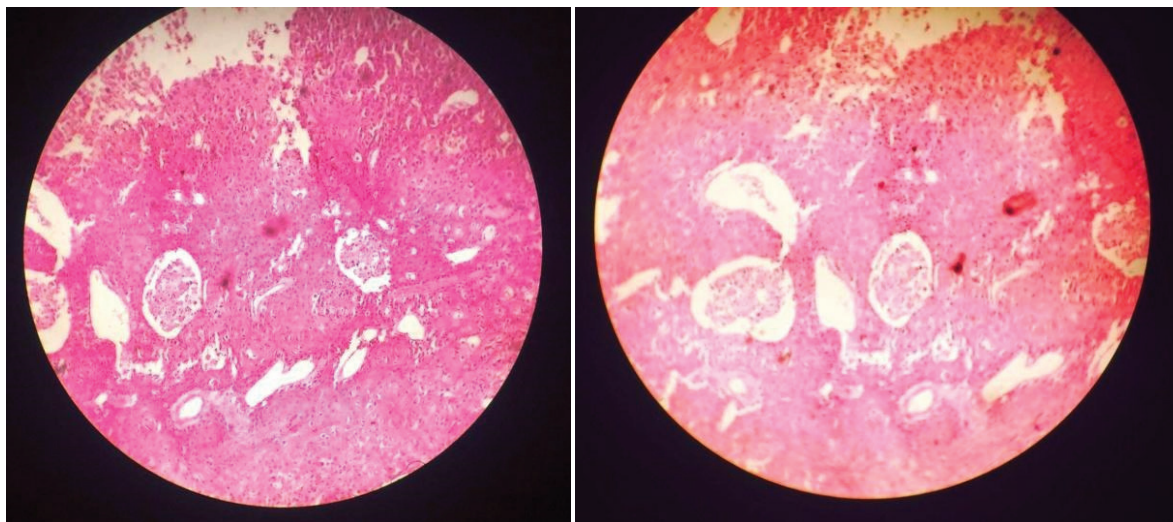


Figure 4: HPE of the cerebral metastasis section revealed a well differentiated squamous cell carcinoma with nests of neoplastic squamous epithelial cells, pleomorphic nuclei, and numerous mitosis, adjacent to edematous brain tissue with extensive reactive gliosis. Neoplastic squamous epithelial cells have high N/C ratio. (H and E stain)

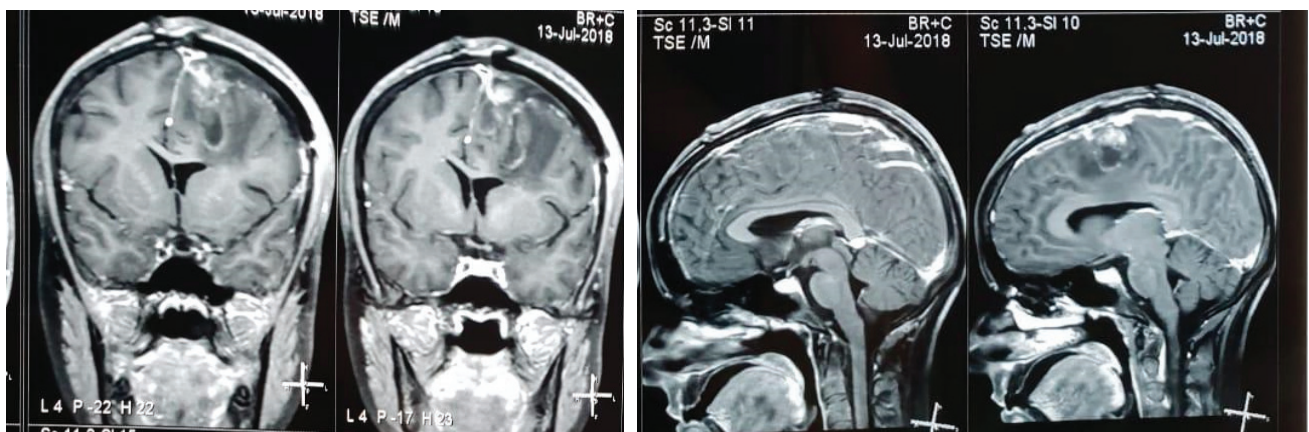


Figure 5: (Post op) Coronal (a) and sagittal (b) magnetic resonance scans (T1WI with Gd) reveal postoperative changes-gliosis in the left frontal lobe without any cerebral recurrence

Malignant oral SCC can metastasize to any part of the brain. Factors that affect the tendency of primary oral SCC tumours to metastasize into the brain are many and unknown. Malignant oral SCC tumours can indirectly metastasize to the brain by first metastasizing to the cervical lymph nodes and then to the brain, the mechanism of metastasis probably being lymphatic. Late presentation of brain metastatic disease from oral SCC are more frequently reported. Metastases are most likely to cause death after loco-regional control of the primary tumour has been achieved.⁷ Evidences suggest that late-occurring brain metastases result from differences in the proliferative potential of a subgroup of cells in the growth-arrested metastatic tumour.⁸ It has been found in head and neck squamous cell carcinoma (HNSCC) along with other epithelial malignancies that over expression of epidermal growth factor receptor (EGFR) has a direct association with increased tumour growth and metastasis, and this also shows resistance to chemotherapeutic agents. It carries a poor prognosis. Epidermal growth factor receptor (EGFR) is a potential target for anti-tumoral therapy and many EGFR inhibitors have been investigated in pre-clinical or clinical settings.⁹ EGFR expression can be significantly down regulated and cell growth of HNSCC can be inhibited by treatment with EGFR inhibitors along with chemotherapy. Therefore, in the treatment of HNSCC, EGFR inhibitors are frequently used. A recent published retrospective study of seven cases of HNSCC patients with cerebral metastases showed presence of human papillomavirus (HPV) in four out of seven cases.² In patients of systemic cancer, with remote brain metastasis either parenchymal or leptomeningeal can cause epilepsy.¹⁰ Optimal treatment for patients of single brain metastases, with systemic disease under control or absent is surgical removal of the lesion followed by external adjuvant radiotherapy.¹¹ Other methods for treating brain metastasis, such as surgery, WBRT, and SRS, compete and complement one another. Recent ablative treatments like Laser interstitial thermal therapy (LITT), magnetic resonance (MR)-guided focused ultrasound surgery (MRgFUS)—as well as those currently in development—which can be visualized in real-time, promise to further strengthen the neuro-oncologic management options.¹²

Our case report is in agreement with the earlier ones reporting occurrence of cerebral metastases of oral SCC. Therefore in case of neurological deterioration in such patients, brain metastasis should be taken into consideration. Patient's symptoms and disease control can be achieved with surgery and/or radiotherapy. There is a major role of stereotactic radiosurgery in treating brain metastases of less than 2.5cm in size with no significant

mass effect or for those located in eloquent area.

Conclusion

Metastasis to the brain should be considered and looked for in all cancer patients with large infiltrative lesions, with aggressive disease, and in late survivors with initially advanced disease. In presence of brain metastasis even after aggressive therapy, the ultimate survival depends on control of extracranial disease.

Conflict of Interest: None

Source(s) of support: None

References

1. Hardee PS, Hutchison IL. Intracranial metastases from oral squamous cell carcinoma. **British Journal of Oral and Maxillofacial Surgery.** 2001;39(4):282-5. <https://doi.org/10.1054/bjom.2001.0648>
2. Ruzevick J, Olivi A, Westra WH. Metastatic squamous cell carcinoma to the brain: an unrecognized pattern of distant spread in patients with HPV-related head and neck cancer. **Journal of neuro-oncology.** 2013;112(3):449-54. <https://doi.org/10.1007/s11060-013-1075-9>
3. Ngan RK, Yiu HH, Cheng HK, Chan JK, Sin VC, Lau WH. Central nervous system metastasis from nasopharyngeal carcinoma: a report of two patients and a review of the literature. **Cancer.** 2002;94(2):398-405. <https://doi.org/10.1002/cncr.10179>
4. Wen PY, Loeffler JS. Brain metastases. **Current treatment options in oncology.** 2000;1(5):447-58. <https://doi.org/10.1007/s11864-000-0072-3>
5. Kotwall C, Sako K, Razack MS, Rao U, Bakamjian V, Shedd DP. Metastatic patterns in squamous cell cancer of the head and neck. **The American Journal of Surgery.** 1987;154(4):439-42. [https://doi.org/10.1016/0002-9610\(89\)90020-2](https://doi.org/10.1016/0002-9610(89)90020-2)
6. Calhoun KH, Fulmer P, Weiss R, Hokanson JA. Distant metastases from head and neck squamous cell carcinomas. **The Laryngoscope.** 1994;104(10):1199-205. <https://doi.org/10.1288/00005537-199410000-00003>
7. Taillibert S, Delattre JY. Palliative care in patients with brain metastases. **Current opinion in oncology.** 2005;17(6):588-92. <https://doi.org/10.1097/01.cco.0000183673.15133.e2>
8. Kirsch M, Schackert G, Black PM. Angiogenesis, metastasis, and endogenous inhibition. **Journal of Neuro-oncology.** 2000;50(1-2):173-80. <https://doi.org/10.1023/A:1006453428013>

9. Nozawa H, Tadakuma T, Ono T, Sato M, Hiroi S, Masumoto K, Sato Y. Small interfering RNA targeting epidermal growth factor receptor enhances chemosensitivity to cisplatin, 5-fluorouracil and docetaxel in head and neck squamous cell carcinoma. **Cancer science**. 2006;97(10):1115-24. <https://doi.org/10.1111/j.1349-7006.2006.00287.x>
10. Bromfield EB. Epilepsy in patients with brain tumors and other cancers. **Reviews in neurological diseases**. 2004;1:S27-33. PMID:16400292
11. Patchell RA, Tibbs PA, Walsh JW, Dempsey RJ, Maruyama Y, Kryscio RJ, Markesbery WR, Macdonald JS, Young B. A randomized trial of surgery in the treatment of single metastases to the brain. **New England Journal of Medicine**. 1990;322(8):494-500. <https://doi.org/10.1056/nejm19900223220802>
12. Lin J, Jandial R, Nesbit A, Badie B, Chen M. Current and emerging treatments for brain metastases. **Oncology**. 2015;29(4). PMID:25952487