

Spontaneous Rupture of an Ovarian Dermoid Cyst Associated with Intra-Abdominal Chemical Peritonitis: Characteristic CT Findings

Koirala S, Adhikari K, Khadka S

Department of Radio Diagnosis and Imaging, BPKIHS, Dharan, Nepal

Received: September 20, 2019

Accepted: September 30, 2019

Published: January 31, 2019

Cite this paper:

Koirala S, Adhikari K, Khadka S. Spontaneous Rupture of an Ovarian Dermoid Cyst Associated with Intra-Abdominal Chemical Peritonitis: Characteristic CT Findings. *Nepalese Journal of Radiology* 2019;9(14):52-54. <http://dx.doi.org/10.3126/njr.v9i2.27433>

ABSTRACT

Spontaneous rupture of mature cystic teratoma is a rare complication which results in leakage of the liquefied sebaceous contents into the peritoneum leading to acute or chronic peritonitis. We report a case of a 23-year-old female who presented with pain abdomen, abdominal distension and fever. Contrast enhanced abdominal CT scan showed right adnexal complex cystic lesion with discontinuity in its wall along with features of peritonitis.

Keywords: *Mature; Peritonitis; Rupture; Teratoma*

INTRODUCTION

Dermoid is the most common ovarian neoplasm comprising between 10 to 25 percent of ovarian tumours. The tumor can rupture causing leakage of the sebaceous contents into the peritoneum and resulting in peritonitis. However, this is a rare complication, occurring in less than 1% of cases.¹ We present the CT findings of a case of spontaneous rupture of mature cystic teratoma causing chemical peritonitis.

CASE REPORT

A 23 years female presented to the OPD with history of pain in right iliac fossa for one month with increased intensity in last five days. Patient also complained of abdominal distension and constipation for last 3 days. Patient had fever for one day. On physical examination abdomen was soft and non-tender with mild distension. No mass was

Correspondence to: Dr. Sapana Koirala
Senior Resident
Department of Radiodiagnosis and Imaging
BPKIHS
Dharan, Nepal
Email: ksapana11@gmail.com



Licensed under CC BY 4.0 International License which permits use, distribution and reproduction in any medium, provided the original work is properly cited

palpable on abdominal examination. On USG there was a cystic lesion of size ~6x5.5cm in right adnexal region with internal echoes and septations within along with mild fluid collection with internal echoes in abdomen and pelvis. Her medical and family history were unremarkable. Contrast enhanced abdominal CT scan showed thick irregular walled cystic lesion with fat content and soft tissue component with focus of calcification within (s/o rokitansky nodule) in right adnexa. These features were consistent with dermoid cyst. There was a focal defect in superior aspect of the wall of cyst (likely the site of rupture). The CT also showed diffusely thickened peritoneal lining along with inflamed omentum and mesentery with moderate free fluid in abdomen and pelvis along with focal fat attenuating areas in bilateral sub-diaphragmatic region (s/o chemical peritonitis).

Operation

Patient underwent emergency exploratory laparotomy. There was a multilobulated cystic lesion of size measuring 15x15cm with ruptured wall and containing cheesy material along with hair within. The omentum and mesentery was grossly inflamed with adherent bowel loops with cheesy material present in all quadrants of abdomen and pelvis. Patient underwent right salpingo-oophorectomy followed by adhesiolysis of bowel loops followed by thorough peritoneal lavage.

Pathology

Histopathological findings were consistent with mature cystic teratoma.

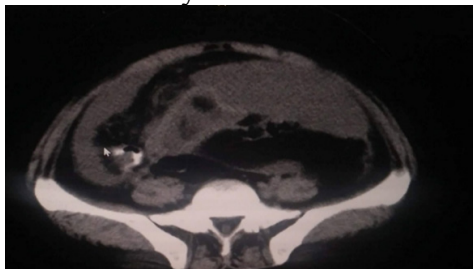


Figure 1: Axial CT scan of pelvis shows right adnexal dermoid with focus of calcification.

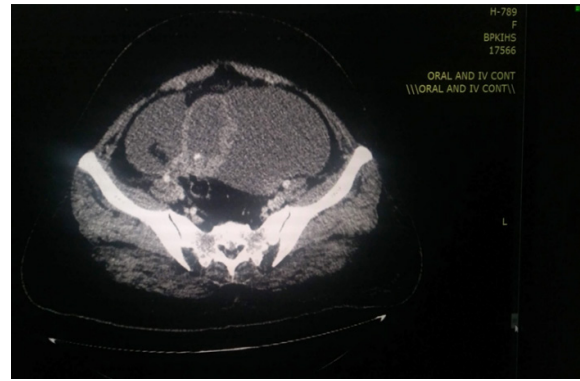


Figure 2: Axial CT scan at the level of pelvis showing defect in the wall of the dermoid.

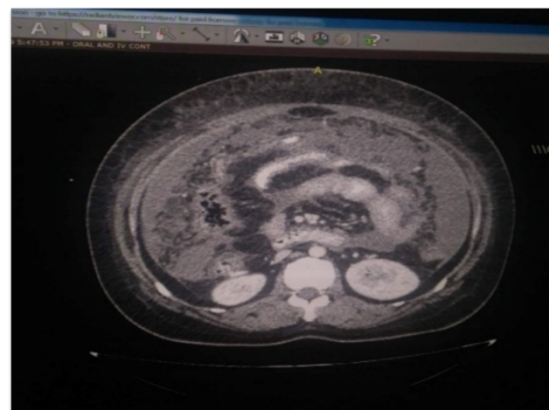


Figure 3: Axial CT scan showing peritoneal thickening and stranding of omentum and ascites.

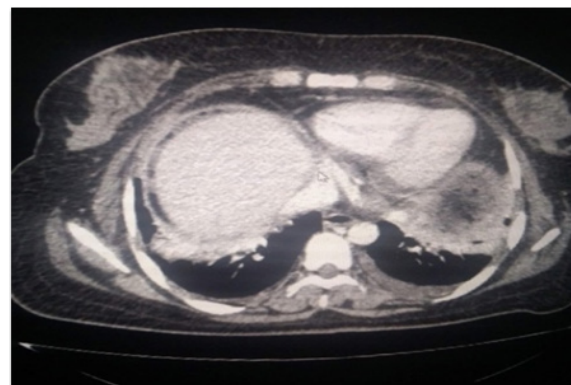


Figure 4: Axial CT at level of liver showing focal fat attenuating areas in right sub-diaphragmatic region

DISCUSSION

Mature cystic teratomas are one of the most common benign ovarian neoplasms

accounting for 10 to 20% of all ovarian tumours.² The peak incidence is reported between 20 and 40 years of age.³ The complications include torsion (16% of ovarian teratomas), rupture (1%-4%), malignant transformation (1%-2%), infection (1%), and autoimmune hemolytic anemia (<1%).⁴ Rupture causes leakage of the liquefied sebaceous contents into the peritoneum, which irritates the peritoneum and leads to acute or chronic inflammation.⁵ At US, CT, and MR imaging, accurate diagnosis of a ruptured ovarian teratoma can be accomplished when the discontinuity of the wall is noted. The presence of ascites and a distorted or flattened shape of the tumor suggest tumor rupture, thereby indicating surgery. Acute or chronic peritonitis can manifest as ascites, diffuse or focal omental infiltration, and inflammatory masses involving the omentum and bowel.⁶ Whenever imaging findings of peritonitis are seen in case of mature cystic teratoma, the possibility of rupture should be kept in mind and the integrity of the tumor wall should be carefully evaluated.

CONCLUSION

Rupture of mature cystic teratoma is a rare complication and can cause life threatening chemical peritonitis. Timely diagnosis and intervention can be lifesaving.

CONFLICT OF INTEREST

None

SOURCES OF FUNDING

None

REFERENCES

1. Comerci JJ, Licciardi F, Bergh PA, Gregori C, Breen JL. Mature cystic teratoma: a clinicopathologic evaluation of 517 cases and review of the literature. *Obstet Gynecol* 1994;84(1):22-28. Available from: <https://europepmc.org/article/med/8008317> [Accessed 23rd June 2019].
2. MATZ MH. Benign cystic teratomas of the ovary. *Obstet Gynecol Surv* 1961;16(5):591-605. <https://doi.org/10.1097/00006254-196110000-00001>
3. Lakkis WG, Martin MC, Gelfand MM. Benign cystic teratoma of the ovary: a 6-year review. Canadian journal of surgery. *Journal canadien de chirurgie* 1985;28(5):444-446.
4. Park SB, Kim JK, Kim KR, Cho KS. Imaging findings of complications and unusual manifestations of ovarian teratomas. *Radiographics* ;28(4):969-983. <https://doi.org/10.1148/rg.284075069>
5. Rha SE, Byun JY, Jung SE et al. Atypical CT and MRI manifestations of mature ovarian cystic teratomas. *AJR Am J Roentgenol* 2004;183(3):743-750. <https://doi.org/10.2214/ajr.183.3.1830743>
6. Fibus TF. Intraperitoneal rupture of a benign cystic ovarian teratoma: findings at CT and MR imaging. *Am J Roentgenol* 2000;174(1):261-262. <https://doi.org/10.2214/ajr.174.1.1740261>