

Orthodontic Management of Anterior and Unilateral Posterior Crossbite: A Case Report

Nabin Kumar Chaudhary

Consultant Orthodontist, Dental Unit, Hetauda Hospital, Hetauda, Nepal

Corresponding Author:

Dr. Nabin Kumar Chaudhary, Email: cnabin39@gmail.com

ABSTRACT

Crossbite refers to abnormal labiolingual and buccolingual relations between the opposing teeth. This results in the imbalanced facial appearance of the patient causing varied degrees of distress based on the individual's values and self-esteem. The management of skeletal class III malocclusion with anterior and posterior crossbite can be challenging. This case report describes a case of skeletal class III malocclusion complicated with an anterior, and unilateral posterior crossbite, and severe crowding which was managed satisfactorily with a fixed orthodontic appliance. The proper clinical examination, diagnosis, problem list, and formulation of the treatment plan are of utmost importance for the proper management of the case. The diagnosis can be done through proper history, clinical examination, an orthopantomogram, and a lateral cephalogram. The patient's grin was transformed from a non-consonant to a consonant smile, and the profile was transformed from slightly concave to straight.

Keywords: Anterior crossbite, Fixed orthodontic appliance, Posterior crossbite, Skeletal class III malocclusion.

INTRODUCTION

The lingual location of the maxillary anterior teeth in relation to the mandibular anterior teeth causes anterior crossbite.¹ Posterior crossbite results from abnormal buccolingual relation between opposing molars and premolars.² The common occurrence of anterior crossbite is 66.1% while posterior crossbite is 19.6% and both anterior and posterior crossbite is 14.3%.³ The common etiological factors for the development of crossbite include inadequate space for permanent successors results in a buccal or lingual eruption route, functional shift, defective eruption sequence, deciduous teeth retention for a longer period of time, an anomaly in tooth anatomy, aberrant growth of craniofacial complex bones caused by hereditary and environmental factors.³ The diagnosis can be done through proper history, clinical examination, an orthopantomogram (OPG), and a lateral cephalogram.⁴ Untreated crossbite may result in tooth damage in crossbite due to attrition, gingival recession, loss of alveolar bone support for the lower incisor, temporomandibular dysfunction, mobility of teeth in crossbite, and potential harmful consequences on mandible and maxilla growth.⁵ This could also result in an imbalanced facial appearance,⁶ which could cause varied degrees of distress, based on the individual's values and self-confidence.⁴ Crossbites are also associated with speech issues such as decreased speech intelligibility and increased nasality.⁴

Posterior crossbite can be corrected with quad helix (fixed) or expansion plate (removable) in children while in adolescents Hyrax or Haas type of expansion can be used.⁶ Another technique for widening the upper arch that can result in additional skeletal expansion in adult patients with a totally fused mid-palatal suture is surgically assisted rapid palatal expansion. However, its drawbacks include root resorption and condyle damage.⁷ Anterior crossbite can be managed utilizing removable appliances with z-spring, functional appliances, cemented appliances, fixed appliances, and a combination of these techniques.⁵ Fixed appliances are bonded to the teeth, while removable appliances can be taken out of the mouth by patients.⁶

This case report describes a class III malocclusion with anterior and posterior crossbite which was managed with a fixed orthodontic appliance. This case is unique as it explains how the skeletal class III malocclusion complicated with anterior and posterior unilateral crossbite was successfully managed with a fixed orthodontic appliance.

CASE REPORT

An 18-year-old female patient approached with the primary complaint of irregular teeth in the upper and lower front region of the jaw. The patient had no history of thumb-sucking or mouth-breathing habits. This patient's medical history, past history, and family history were insignificant. Built was mesomorphic, head brachycephalic

Article information		
Received: 7 August 2022	Accepted: 9 August 2023	Published: 31 August 2023
<p>Copyright © 2023 by the author(s), wherein the author(s) are the only owners of the copyright of the published content</p> <p>Licensing: This published content is distributed under the terms of the Creative Commons Attribution International License (CC BY 4.0) license, and is free to access on the Journal's website. The author(s) retain ownership of the copyrights and publishing rights without limitations for their content, and they grant others permission to copy, use, print, share, modify, and distribute the article's content even for commercial purposes.</p> <p>Disclaimer: This publication's claims, opinions, and information are the sole creations of the specific author(s) and contributor(s). Errors in the contents and any repercussions resulting from the use of the information included within are not the responsibility of the publisher, editor, or reviewers. Regarding any jurisdictional assertions in any published articles, their contents, and the author's institutional affiliations, the Journal and its publisher maintain their objectivity.</p>		

(Cephalic Index: 88.2%), face mesoprosopic (Facial Index: 86.2%), and facial form oval. The profile of the patient was slightly concave, the facial divergence posterior, and the lip was competent. On functional examination, there was a forward path of closure due to incisor interference to achieve maximum intercuspation. Clinically there were 28 teeth present. All third molars were unerupted. Crossbites were present with respect to (w.r.t.) 41 (mandibular right central incisor), 12 (maxillary right lateral incisor), 22 (maxillary left lateral incisor), 25 (maxillary left second premolar), and 26 (maxillary left first molar) (**Figure 1**). Maxillary arch was ovoid, with severe crowding. 12 and 22 were palatally placed. 13 (maxillary right canine) and 23 (maxillary left canine) were labially placed. The mandibular arch was oval and crowded anteriorly. Molar relation was super class I and class I on right side and left side respectively. Canine relation was end-on on right side and class I on left side. Overjet was 0.5 mm and overbite was 1 mm which was 14.2% of lower central incisor suggestive of decreased overjet and overbite. The upper dental midline was moved to the right by 0.5 mm, while the lower dental midline was moved to the left by 0.5 mm.

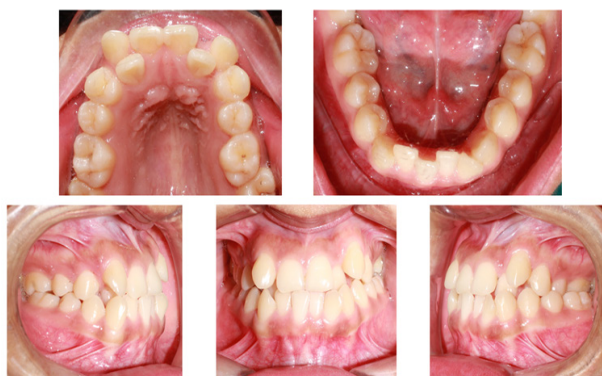

Figure 1: Pre-treatment intra-oral photographs

Lip line was evocative of an average smile, and non-consonant smile arc on smile analysis (**Figure 2**). Orthopantomogram showed no pathologies associated with teeth and their surrounding structures (**Figure 3**). Lateral cephalogram (**Figure 4**) revealed Cervical Vertebrae Maturation (CVM) stage 5. On cephalometric analysis, Sella-Nasion-point A (SNA) angle was 77° and Sell-Nasion-point B (SNB) angle 79° with point A-Nasion-point B (ANB) angle -2° suggestive of skeletal class III malocclusion. Frankfort mandibular plane angle (FMA) was 31° suggestive of a vertical growth pattern. Upper incisor to Nasion-point A (NA) plane angle was 41° and placed at the distance of 7 mm suggestive of proclined and forwardly placed upper incisors. Lower incisor to Nasion-point B (NB) plane angle was 23° and placed at the distance of 4 mm suggestive of retroclined, and normally placed lower incisors. Upper and lower lips were placed at the distance of 0.5 mm and 2.5 mm from Steiner's S-line indicative of protrusive upper and lower lips (**Figure 5**). Model analysis revealed molar relation of super class I on right side and class I on left side. According to Ashley Howe's analysis, premolar basal arch width was greater than premolar diameter, indicating that arch extension was probable in this circumstance. Thus, the diagnosis of the patient was skeletal class III, Angle's class III (right) subdivision, and slightly protrusive upper and lower lips.




Figure 2: Pre-treatment extra-oral photographs

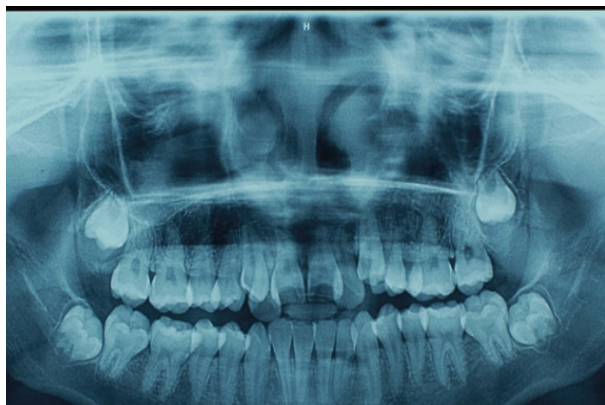

Figure 3: Pre-treatment Orthopantomogram

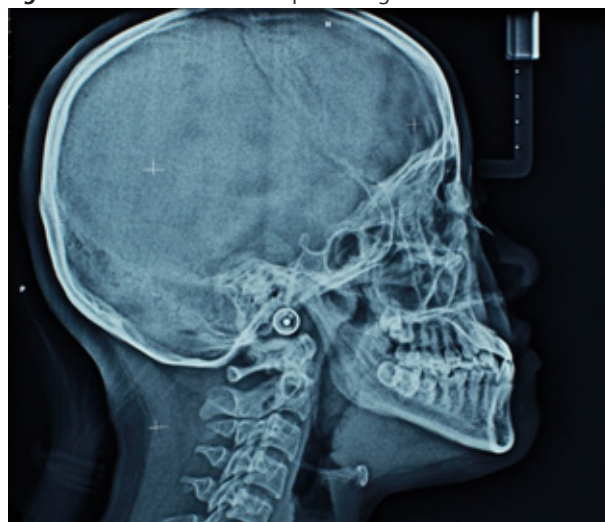

Figure 4: Pre-treatment lateral cephalogram

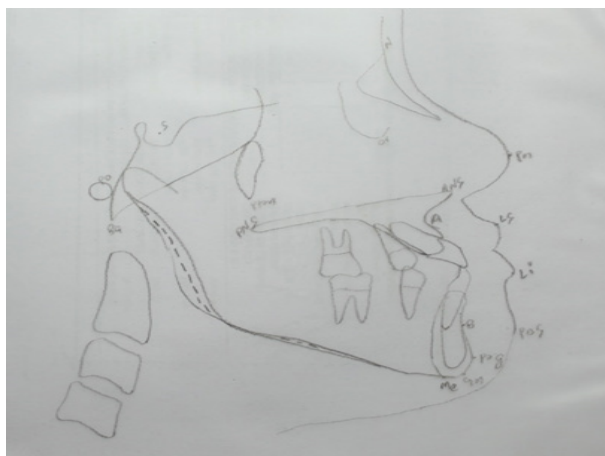


Figure 5: Pre-treatment cephalometric tracing

The treatment objective included crowding correction in the upper and lower arch, decreased overjet and overbite, and crossbite w.r.t. 41, 12, 22, 25, and 26. The ANB angle, H angle, wits appraisal, and incisor mandibular plane angle was suggestive of not severe skeletal class III malocclusion. Since the patient had skeletal class III malocclusion, growth modification was not possible as the CVM stage was stage 5, orthodontic camouflage was planned with extraction 14 (maxillary right first premolar), 24 (maxillary left first premolar), 34 (mandibular left first premolar), and 44 (mandibular right first premolar) as the space required for correction of crowding was not possible without extraction. To strengthen the anchorage, lingual holding arch (LHA) and transpalatal arch (TPA) were put in the mandible and maxilla, respectively. Maximum anchorage was planned on both sides of mandible and maxillary left side whereas moderate anchorage was planned on maxillary right side. The MBT 0.022 slot bracket was installed in both the upper and lower arch. Upper and lower arch alignment and leveling were performed using 0.014" Nickel-Titanium (NiTi), 0.016" NiTi, and 0.017" x 0.025" NiTi. Initially, 13 and 23 retractions were performed using 0.018" stainless steel (SS) archwire. Posterior crossbite was corrected through the dentoalveolar expansion through the archwire. Glass Ionomer Cement (GIC) was placed in 36 and 46 to raise the anterior bite for correction of anterior crossbite. OPG was done at the conclusion of treatment which showed parallel roots with each other (**Figure 6**). Lateral cephalogram (**Figure 7**) was taken before the debond of the appliance. The Pre and post treatment cephalometric values showed that the inclination of incisors was improved (**Table 1**). Finally, with normal overjet and overbite, class I molar and canine relations were obtained. Cranial base superimposition showed that the position of lips was maintained (**Figure 8**). Fixed upper and lower retainer was placed in maxilla and mandible after debonding of fixed appliance (**Figure 9**). The smile and profile of the patient were improved towards the conclusion of therapy (**Figure 10**). The entire treatment period lasted 26 months. The proper torque of 12 was not achieved which is the limitation of this case report since the patient was exhausted to go any further treatment due to long treatment duration.

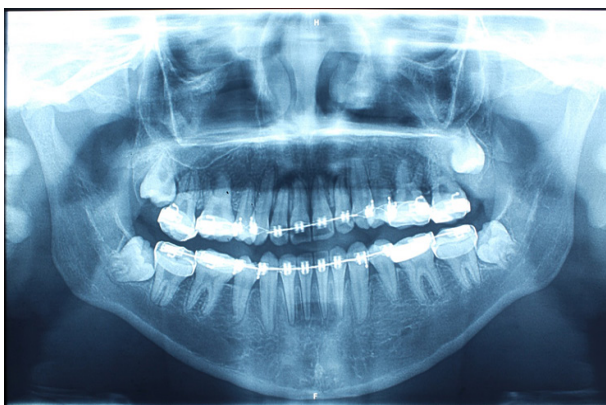


Figure 6: Orthopantomogram before debond of appliance

DISCUSSION

At the conclusion of treatment, the treatment objectives were met. The decrowding of upper and lower arch was achieved. Normal overjet and overbite were achieved. Both anterior and posterior crossbite correction was

Table 1: Comparison of the cephalometric values before and after the treatment

Parameters	Normal value	Pre-treatment	Post-treatment	Difference
Sella-Nasion-point A (SNA, degree)	82±2	77	78	1+
Sella-Nasion-point B (SNB, degree)	80±2	79	79	0
Point A-Nasion-point B (ANB, degree)	2±2	2-	1-	1+
Frankfort Mandibular plane Angle (FMA, degree)	25	31	34	2+
Upper incisor to Nasion-point A (NA, degree/mm)	22/4	41/7	36/5	5-/-2
Lower incisor to Nasion-point B (NB, degree/mm)	25/4	23/4	24/3	1+/-1
Steiner (S) line to				+0.5
Upper lip (mm)	-4mm	0.5mm	1mm	
Lower lip (mm)	-2mm	2.5mm	3mm	+0.5

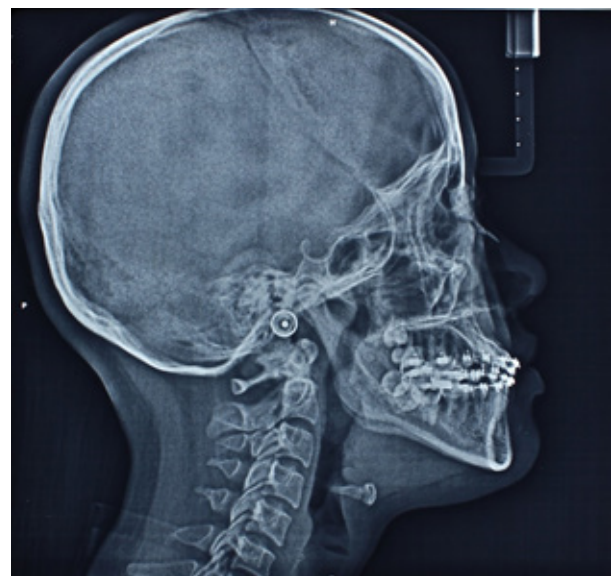

Figure 7: Lateral cephalogram before debond of appliance



Figure 8: Cranial base superimposition

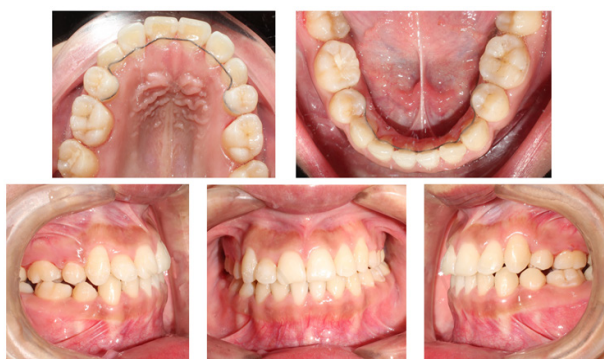

Figure 9: Post-treatment intra-oral photographs

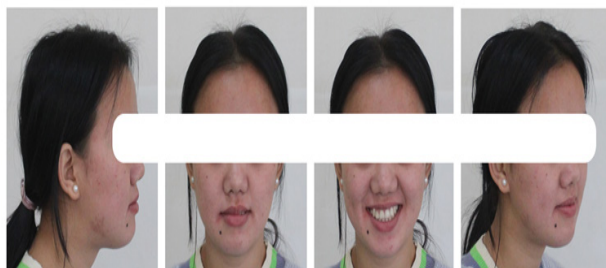


Figure 10: Post-treatment extra-oral photographs

achieved (**Figure 9**). The patient's smile transformed from non-consonant to consonant (**Figure 10**). The patient's profile was changed from slightly concave to straight without increasing the protrusion of the lips.

Crossbites should be treated as soon as clinically visible as it may result in compensatory changes in the temporomandibular articulation, the development of skeletal asymmetries, changes in soft tissue growth, and primary and secondary teeth attrition.⁸ The early treatment also has advantages such as reducing unfavorable growth, re-establishing adequate muscle balance before degrading effects become well entrenched, enhancing maxillary lip posture and facial appearance if rectified in the mixed dentition, and giving space for canine eruption.⁵ However this was not possible for this presented case as the patient came for treatment only after all the permanent teeth had erupted. There is no scientific evidence to demonstrate that any of the therapy approaches are more effective.⁹

Although various methods were available for the correction of posterior crossbite, archwire was used in this case for the dentoalveolar expansion similar to the study by Atik et al.¹⁰ They showed that following treatment, the maxillary intercanine, interpremolar, and intermolar widths were significantly higher.¹⁰ However, they discovered that the teeth had a statistically significant labial proclination which was not the same in this presented case. This may be because Atik et al,¹⁰ treated the patient using non-extraction method, however in the case being discussed, extraction method was used.¹⁰ Fixed appliances offer benefits such less discomfort, a decreased need for patient cooperation, improved control over tooth movements, and cost effectiveness.¹ Fixed appliance also gives more predictable results.¹¹ Yaseen and Acharya,¹ treated the anterior and posterior crossbites with a modified quad helix appliance. However, the case treated by them was different as their case was in the mixed dentition but this case was in the permanent dentition stage. Alogaibi et

al,⁷ performed surgery on both jaws, involving bilateral sagittal split osteotomies in the mandible and Le Fort I osteotomies in the maxilla, to treat skeletal class III malocclusion with both anterior and posterior crossbites. Their case was different from the presented case in terms of severity which was beyond the scope of orthodontic treatment alone. The conservative orthodontic solution for the patient presented in this case report can potentially shorten the duration of treatment and lessen the risk of patient burnout.⁷ Tanaka et al,¹² treated complete maxillary crossbite using Haas expansion. It was, nevertheless, distinct from the presented case because it was more severe and in the period of mixed dentition.¹²

For the anterior crossbite correction, GIC bite block was placed in lower molars to raise the anterior bite similar to the study by Zalan et al.¹³ This method of treatment was similar to the study by Skeggs and Sandler,¹¹ as the treatment was done with fixed appliance. This was different from the study by Ulusoy and Bodrumlu,¹⁴ as they treated the case by employing two successive removable acrylic appliances. Removable appliance was possible for successful treatment as the maxillary arch had some spacing, and there was enough mesiodistal space for the maxillary central incisors to shift labially which was different from this case. Abraham et al,¹⁵ treated the anterior crossbite through the use of modified transparent tray aligners. Although this is an esthetic option for the treatment, its downsides include exorbitant prices and some restrictions on tooth movement.¹⁵

The described case was a skeletal class III malocclusion complicated with anterior and posterior unilateral crossbite which was managed successfully with the fixed orthodontic appliance which is the strength of this case report. The patient was satisfied as the problems of the patient were addressed at the end of treatment. The patient was pleased with the new smile and the ability to bite normally without any impediment. This case's shortcoming was its prolonged treatment period. But this was inevitable because of the COVID-19 lockdown which didn't allow for the proper regular follow-up.

CONCLUSION

Skeletal class III malocclusion with anterior and posterior crossbite can be challenging for its management. The proper clinical examination, diagnosis, problem list, and formulation of the treatment plan are of utmost importance for the proper management of the case. This case report has explained how the malocclusion with anterior and unilateral posterior crossbite and severe crowding was successfully managed with a fixed orthodontic appliance.

Consent: Informed consent from the patient was taken for the publication of this article including the photographs as a case report.

Competing interests: The author declares that there are no competing interests.

Funding: None

Acknowledgments: I would like to acknowledge the patient for being cooperative throughout the course of treatment.

REFERENCES

1. Yaseen SM, Acharya R. Hexa helix: modified quad helix appliance to correct anterior and posterior crossbites in mixed dentition. *Case Rep Dent.* 2012;2012:860385. [\[DOI\]](#)

- PubMed]
2. Andrade AS, Gameiro GH, Derossi M, Gavião MB. Posterior crossbite and functional changes. A systematic review. *Angle Orthod.* 2009;79(2):380-86. [DOI | PubMed]
 3. Dacosta OO, Utomi IL. A clinical review of crossbite in an orthodontic population. *West Afr J Med.* 2011;30(1):24-28. [DOI | PubMed]
 4. Malandris M, Mahoney EK. Aetiology, diagnosis and treatment of posterior cross-bites in the primary dentition. *Int J Paediatr Dent.* 2004;14(3):55-66. [DOI | PubMed]
 5. Borrie F, Bearn D. Early correction of anterior crossbites: a systematic review. *J Orthod.* 2011;38(3):175-84. [DOI | PubMed]
 6. Agostino P, Ugolini A, Signori A, Silvestrini-Biavati A, Harrison JE, Riley P. Orthodontic treatment for posterior crossbites. *Cochrane Database Syst Rev.* 2021;12: CD000979. [DOI | Full Text]
 7. Alogaibi YA, Alsulaimani FF, Jamal B, Mitwally R. Combined Orthodontic and Surgical Management for Treatment of Severe Class III Malocclusion with Anterior and Posterior Crossbites. *Case Rep Dent.* 2021;2021:5579077. [DOI | PubMed]
 8. Binder RE. Correction of posterior crossbites: diagnosis and treatment. *Pediatr Dent.* 2004;26(3):266-72. [PubMed | Full Text]
 9. Petrán S, Bondemark L, Söderfeldt B. A systematic review concerning early orthodontic treatment of unilateral posterior crossbite. *Angle Orthod.* 2003;73(5):588-96. [PubMed | Full Text]
 10. Atik E, Akarsu-Guven B, Kocadereli I, Ciger S. Evaluation of maxillary arch dimensional and inclination changes with self-ligating and conventional brackets using broad archwires. *Am J Orthod Dentofacial Orthop.* 2016;149(6):830-37. [DOI | PubMed]
 11. Skeggs RM, Sandler PJ. Rapid correction of anterior crossbite using a fixed appliance: a case report. *Dent Update.* 2002;29(6):299-302. [DOI | PubMed]
 12. Tanaka OM, Fornazari IA, Parra AX, de Castilhos BB, Franco A. Complete Maxillary Crossbite Correction with a Rapid Palatal Expansion in Mixed Dentition Followed by a Corrective Orthodontic Treatment. *Case Rep Dent.* 2016;2016:8306397. [DOI | PubMed]
 13. Zalan AK, Maxood A, Dalili MH, Zaman H, Zubairy KK, Babar P, et al. Effect of bite opening on the correction of dental anterior cross bite – A novel approach. *J Pak Dent Assoc.* 2021;30(2):107-12. [Full Text]
 14. Ulusoy AT, Bodrumlu EH. Management of anterior dental crossbite with removable appliances. *Contemp Clin Dent.* 2013;4(2):223-6. [DOI | PubMed]
 15. Abraham KK, James AR, Thenumkal E, Emmatty T. Correction of anterior crossbite using modified transparent aligners: An esthetic approach. *Contemp Clin Dent.* 2016;7(3): 394-7. [DOI | Full Text]