

# Morphometric Variations of Thyroid Gland: A Cadaeric Study

Laxmi Bhattarai

Lecturer, Universal College of Medical Science, Bhairahawa, Nepal

**Corresponding Author:** Laxmi Bhattarai; email: bipasana.fertility@gmail.com

## ABSTRACT

**Background:** The size of thyroid gland is subject to great variations. The thyroid gland consists of two lobes and a bridging isthmus. It is located anteriorly in the neck at the level of the C5–T1 vertebrae deep to the Infrahyoid muscles. The developmental anomalies of the thyroid gland are partial and total agenesis, various ectopic tissues, accessory thyroid, and absence of isthmus. This distorts the morphology of the gland and causes clinical and functional disorders.

**Methods:** The thyroid gland was removed from 28 embalmed cadavers. Specimen of abnormal conditions like enlarged gland, partial and total agenesis of gland and absent isthmus was excluded from the study. Presence of pyramidal lobe and levator glandulae thyroidea was noted. The dimensions of each lobe was measured using Vernier caliper. Descriptive statistics was calculated as mean and standard deviation.

**Results:** The average length (right lobe=4.96cm, left lobe= 4.48cm), width (right lobe=2.25cm, left lobe=1.86cm) and thickness (right lobe=1.53cm, left lobe=1.45cm) were measured. Pyramidal lobe was present in 32.14%. Levator glandulae thyroidea was found in only one case (3.57%).

**Conclusion:** Variation in the dimensions of thyroid gland are reported. Knowledge of the wide ranging variations and measurements will help the surgeons and radiologists in correct interpretation, diagnosis and treatment of thyroid diseases.

**Keywords:** Isthmus; Levator glandulae thyroidea; Morphology; Pyramidal lobe

## INTRODUCTION

Thyroid gland is highly vascular endocrine gland placed anteriorly in lower part of neck. It consist of two lateral lobes connected by isthmus. The pyramidal lobe is considered as a normal variant of thyroid gland and has normal thyroid tissue.<sup>1</sup> It develops from the thyroglossal duct. The lower part of duct develops into two lobes and median isthmus. Pyramidal lobe develops as an embryological remnant of caudal end of thyroglossal duct.<sup>2</sup>

The morphology of thyroid gland varies with age, sex, race and geographical location. It was observed that the right lobe is slightly larger than the left one.<sup>3,4</sup> The right lobe is more likely to be affected by thyroid nodules and tends to enlarge more in diffuse thyroid goiter. The study also focused on subjects with an esophagus deviated to the left had a significantly larger right lobe than those with a centrally located esophagus.<sup>5</sup>

As all thyroid diseases are also found in pyramidal lobe, its study bears great importance. Thyroid gland surgery is one of the common procedures performed in head and neck region.<sup>6,7</sup> Hence the knowledge of variation in morphological and topographical anatomy is important in

evaluation and management of thyroid disorders in clinical practice for physicians, radiologists for postoperative scintigraphy and surgeons for performing thyroidectomy.<sup>8</sup>

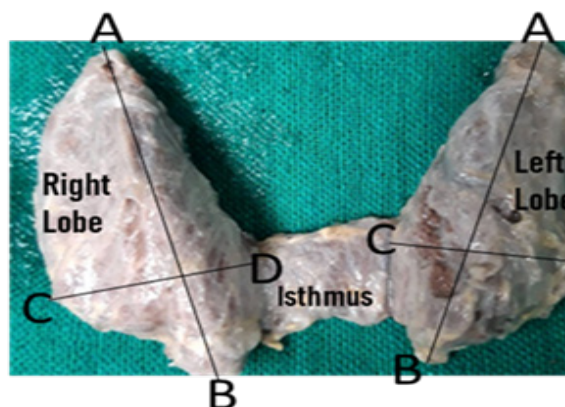
## METHODS

Present study is a cross sectional observational study. It was conducted at the Department of Anatomy, Universal College of Medical Science Bhairahawa, Nepal from July 2021 to September 2021. Institutional Ethical clearance was taken from ethical and subject research committee of Universal College of Medical Sciences (IRC/036/21). Samples were collected by using convenient sampling method. Samples of present study was taken from cadavers. In Rupandehi, cadavers were available in Department of Anatomy, Universal College of Medical Science Bhairahawa. In the dissection room, there were 35 embalmed cadavers out of which 28 were males and 7 were females. Enlarged thyroid gland and partial and total agenesis of gland was excluded from study. As per Cunningham's dissection manual, dissection was carried out to expose the thyroid gland.<sup>9</sup> After dissection, 28 thyroid glands samples met the inclusive criteria out of which 25 were of males and 3 of females. The normal thyroid gland was removed from the cadaver. Measurement was taken using standard vernier

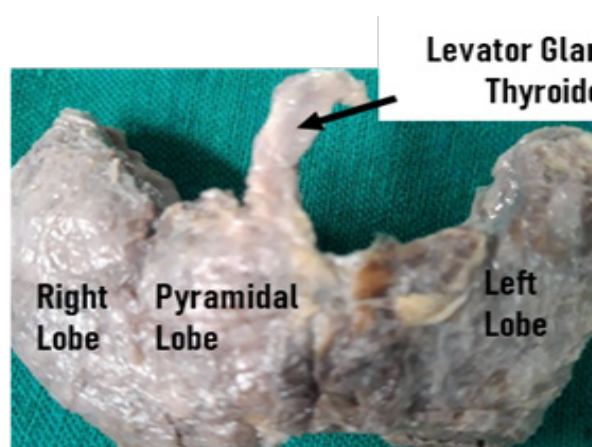
Article information		
Received: 3 May 2022	Accepted: 6 August 2023	Published Online: 31 August 2023
<p>Copyright © 2023 by the author(s), wherein the author(s) are the only owners of the copyright of the published content</p> <p><b>Licensing:</b> This published content is distributed under the terms of the <a href="https://creativecommons.org/licenses/by/4.0/">Creative Commons Attribution International License (CC BY 4.0)</a> license, and is free to access on the Journal's website. The author(s) retain ownership of the copyrights and publishing rights without limitations for their content, and they grant others permission to copy, use, print, share, modify, and distribute the article's content even for commercial purposes.</p> <p><b>Disclaimer:</b> This publication's claims, opinions, and information are the sole creations of the specific author(s) and contributor(s). Errors in the contents and any repercussions resulting from the use of the information included within are not the responsibility of the publisher, editor, or reviewers. Regarding any jurisdictional assertions in any published articles, their contents, and the author's institutional affiliations, the Journal and its publisher maintain their objectivity.</p>		

caliper (in centimeter) according to the following method:

- Length and width of right and left lobes: The length was measured as a vertical distance from highest point of apex to the base of the thyroid gland. The width was measured as largest mediolateral distance of each lobe (**Figure 1**).
- Thickness of right and left lobes: It was measured as a largest anteroposterior distance of each lobe.
- Width of isthmus: It was measured as a vertical distance between upper and lower border of isthmus.
- Pyramidal lobe and Levator glandulae thyroidea was also observed. (**Figure 2**)



**Figure 1:** Lobes of thyroid gland connected by isthmus. AB: Length of lobe, CD: Width of lobe



**Figure 2:** Pyramidal lobe and levator glandulae Thyroidea

Precise working proforma was used to collect the information. Data was recorded in working pro-forma. Data were entered and analysed into SPSS Version 15. Descriptive statistics was used and data were expressed as mean, standard deviation and range were used.

## RESULTS

Present study include 28 thyroid glands out of which 25 were from male cadavers. The average dimensions of right lobe were length 4.96 cm, width 2.25 cm and thickness 1.53 cm. The average dimensions of left lobe were length 4.48 cm, width 1.86 cm and thickness 1.45 cm. Present study showed that average dimension of right lobe was slightly greater than the left lobe. (**Table 1**)

Pyramidal lobe was present in 9 (32.14%) cases only; they were connected with the isthmus of thyroid gland. Levator glandulae thyroidea was found in one case (3.57%) only.

**Table 1:** Dimensions of lobe of the thyroid gland

Lobes	Mean length ± SD	Range	Mean width	Range	Mean thickness ± SD	Range
Right	4.96 ±0.38	1cm	2.25± 0.5	1.5cm	1.5± 0.48	1.5cm
Left	4.48± 0.44	1cm	1.86± 0.46	1.5cm	1.45 ±0.41	1cm

## DISCUSSION

The thyroid gland develops from the floor of the oral cavity and it is first endocrine gland to develop. In some cases, the lower part of thyroglossal duct fails to obliterate and persists as the pyramidal lobe.<sup>10</sup> The lobes are conical in shape and measure about 5 cm in height, 1.5 to 2.0 cm thickness and 2.0 to 3.0 cm width. The bases of the lobes are at the level of fourth or fifth tracheal rings. The apices are at the level of the oblique line on the laminae of the thyroid cartilage. The isthmus measures 1.25 to 1.5 cm both vertically and horizontally. The isthmus usually lies at the level of second to fourth tracheal rings.<sup>11</sup>

The average of length of right and left lobe (4.96 cm and 4.48 cm) correlates with previous studies.<sup>6,12</sup> Study reported mean length of right and left lobe (5.26cm and 5.21cm), width (2.97cm and 2.90 cm) and thickness (2.39 cm and 2.33cm) was higher than present study.<sup>13</sup> Study reported mean length (4.05cm and 3.79cm) lower than present study.<sup>14</sup> Previous study reported thickness of right and left lobes (1.37cm and 1.17cm), slightly lower than present study.<sup>15</sup> The mean width (2.04 cm) was higher than present study.<sup>14</sup> The dimensions of right lobe is slightly higher than left lobes in our sample, which correlates with the previous findings.<sup>16,17</sup> Present study showed presence of isthmus in all cases. Absence of isthmus is a rare anomaly and surgeons operating on the neck should be aware of such anomalies. Computerized tomography scans and magnetic resonance imaging may be important tool for diagnosing anomalies of the thyroid but prior anatomical knowledge may also prove to be beneficial.<sup>18</sup> Previous study investigated the association of handedness and position of esophagus with thyroid size asymmetry. Right-handed subjects had a significantly larger right lobe than left-handed subjects. The study also emphasized on subjects with an esophagus deviated to the left had a significantly larger right lobe than those with a centrally located esophagus.<sup>5</sup>

Presence of pyramidal lobe varies from 18% to 58% that coincides with present study (32.14%). Previous study compared this variation with ethnicity and dietary habits (iodine contents).<sup>19</sup> Study conducted in Indian subcontinent reported that pyramidal lobe in coastal area of South India showed highest incidence of pyramidal lobe (58%) in comparison to North-East region (38.75%).<sup>20</sup> Present study found origin of pyramidal lobe from upper border of isthmus that is common origin. But origin may vary slightly, from left of mid-sagittal plane.<sup>21,22</sup> The presence of double pyramidal lobes has also been

described by Joshi et al. The authors also emphasized that total & partial thyroidectomy performed for different stages of thyroid carcinoma require precise and accurate knowledge of variations associated with the gland.<sup>10</sup> Pyramidal lobe, also known as Lolouett's lobe – should be looked for & removed during thyroidectomy. Residual thyroid tissue in the pyramidal lobe can lead to serious complications in diseases like carcinoma & Grave's disease where complete removal of thyroid gland is indicated.<sup>3,23</sup> In the present study we encountered the levator glandulae only in 3.57%. The incidence of levator glandulae thyroidea has also been stated variably from 0.5% to 85.7%.<sup>11</sup>

### Limitations

This study include samples from only a part of Nepal. It is limited to cadavers from single institute. Cadavers from other part of Nepal could be included for these variations for more generalized conclusions. In present study, morphological variations between male and female was not included due to low proportion of female cadavers. Radiographic study for morphological variations in multiple institutes is suggested to be done in large samples.

### CONCLUSION

There is variation in the morphology of the thyroid gland. Most of the thyroid diseases e.g. goitre, thyrotoxicosis, tumour are usually associated with enlargement of the gland and may require surgical intervention. Thus, morphological variations of thyroid gland could impact pre-operative evaluation. In order to perform safe and effective surgery as well as diagnosis of thyroid disorders, knowledge of normal anatomy and the variations of the gland are essential.

**Acknowledgment:** I am thankful to the faculties and nonteaching staff of department of anatomy, Universal College of Medical Science, Bhairahawa, Nepal.

**Conflict of interest:** The author declared no conflict of interest.

**Source of funding:** The author received no external support.

### REFERENCES

1. Sgalitzer KE. Contribution to the study of the morphogenesis of the thyroid gland. *Journal of anatomy*. 1941 Jul;75(Pt 4):389. [PMID: 17104869] [[PubMed](#)] [[Google Scholar](#)] [[Full Text](#)]
2. Sandler, T. W. "Langman's Medical Embryology. Thyroid Gland." 11th Ed. Lippincott Williams and Wilkins. 2010; 278. ISBN: 0781790697
3. Rajkonwar AJ, Kusre G. Morphological variations of the thyroid gland among the people of upper Assam region of northeast India: a cadaveric study. *Journal of clinical and diagnostic research: y. J Clin Diagn Res*. 2016 Dec;10(12):01-3. [[PubMed](#)] [[DOI](#)] [[Google Scholar](#)] [[Full Text](#)]
4. Hegedüs L, et al. The determination of thyroid volume by ultrasound and its relationship to body weight, age, and sex in normal subjects. *The Journal of Clinical Endocrinology & Metabolism*. 1983 Feb 1;56(2):260-3. [[PubMed](#)] [[DOI](#)] [[Google Scholar](#)]
5. Ying M, Yung DM. Asymmetry of thyroid lobe volume in normal Chinese subjects: association with handedness and position of esophagus. *The Anatomical Record: Advances in Integrative Anatomy and Evolutionary Biology: Advances in Integrative Anatomy and Evolutionary Biology*. 2009 Feb;292(2):169-174. [[PubMed](#)] [[DOI](#)] [[Google Scholar](#)] [[Full Text](#)]
6. Raut RS, Jadhav SS, Kulkarni PR. Morphometric study of pyramidal lobe and levator glandulae thyroidea and its surgical significance. *International Journal of Anatomy and Research*. 2018;6(3.2):5538-43. [[DOI](#)] [[Google Scholar](#)] [[Full Text](#)]
7. Braun EM, Windisch G, Wolf G, Hausleitner L, Anderhuber F. The pyramidal lobe: Clinical anatomy and its importance in thyroid surgery. *Surgical and radiologic anatomy*. 2007 Feb;29(1):21-7. [[PubMed](#)] [[DOI](#)] [[Google Scholar](#)]
8. Marshall CF. Variations in the form of the thyroid gland in man. *Journal of anatomy and physiology*. 1895 Jan;29(2):234-9. [[PubMed](#)] [[Google Scholar](#)] [[Full Text](#)]
9. Cunningham's Manual of practical Anatomy. 16th Ed: Vol 3, Head and Neck and Brain. 2018;51-5. ISBN: 0198749384,9780198749387.
10. Joshi SD, Joshi SS, Daimi SR, Athavale SA. The thyroid gland and its variations: A cadaveric study. *Folia Morphol (Warsz)*. 2010 Feb;69(1):47-50. [[PubMed](#)] [[Google Scholar](#)] [[Full Text](#)]
11. Blumberg NA. Observations on the pyramidal lobe of the thyroid gland. *South African Medical Journal*. 1981 Jun 20;59(26):949-50. [[PubMed](#)] [[Google Scholar](#)]
12. Prakash, et al. Variations in the anatomy of the thyroid gland: clinical implications of a cadaver study. *Anatomical science international*. 2012 Mar;87:45-9. [[DOI](#)] [[Google Scholar](#)] [[PubMed](#)]
13. Tanriover O, et al. Morphometric features of the thyroid gland: a cadaveric study of Turkish people. *Folia morphologica*. 2011 May;70(2):103-8. [[PubMed](#)] [[Google Scholar](#)] [[Full Text](#)]
14. Diana SM, Subramanian RK, Senthil S. Morphometric features of thyroid gland: A detailed cadaveric study. *International Journal of Anatomy and Research*. 2016;2(9):856-9. [[Full Text](#)]
15. Al-Azzawi A, Takahashi T. Anatomical variations of the thyroid gland: An experimental cadaveric study. *Annals of Medicine and Surgery*. 2021 Sep 8;70:102823 [[DOI](#)]. [[PubMed](#)] [[Google Scholar](#)] [[Full Text](#)]
16. Ranade AV, et al. Anatomical variations of the thyroid gland: possible surgical implications. *Singapore medical journal*. 2008 Oct 1;49(10):831. [[PubMed](#)] [[Google Scholar](#)] [[Full Text](#)]
17. M B Saknure, C S Halnikar (Waghmare). Morphological variation of thyroid gland in cadavers. *MedPulse International Journal of Anatomy*. 2017 July;3(1):08-11. [[DOI](#)] [[Full Text](#)]
18. Hoang JK, Branstetter IV BF, Gafton AR, Lee WK, Glastonbury CM. Imaging of thyroid carcinoma with CT and MRI: approaches to common scenarios. *Cancer Imaging*. 2013 March;13(1):128. [[DOI](#)] [[PubMed](#)] [[Google Scholar](#)] [[Full Text](#)]
19. Reddy CK, Panchakshari M. A study of anatomical and morphological variations of the thyroid gland. *Journal of Clinical and Diagnostic Research*. 2016 Sep;4:3510-13. [[Google Scholar](#)] [[Full Text](#)]
20. Harjeet A, Sahni D, Jit I, Aggarwal AK. Shape, measurements and weight of the thyroid gland in northwest Indians. *Surgical and radiologic anatomy*. 2004 Apr 1;26(2):91-5. [[DOI](#)] [[PubMed](#)] [[Google Scholar](#)] [[Full Text](#)]
21. Taty-Anna K, Fariyah HS, Norzana AG, Farida H, Das S. Absence of the isthmus of the thyroid gland: anatomical and clinical considerations. *La Clinica terapeutica*. 2012 Nov;163(6):503-4. [[PubMed](#)] [[Google Scholar](#)] [[Full Text](#)]
22. Larochelle D, Arcand P, Belzile M, Gagnon NB. Ectopic thyroid tissue--a review of the literature. *The Journal of otolaryngology*. 1979 Dec 1;8(6):523-30. [[PubMed](#)] [[Google Scholar](#)]
23. Patra A, Sharma A, Malhotra V, Gupta V. Morphological Variations of the Thyroid Gland in the North Indians: A Cadaveric Study with its Clinical Relevance. *Academia Anatomica International*. 2019;5(1):43-8. [[DOI](#)] [[Google Scholar](#)] [[Full Text](#)]