

# DERMATOLOGICAL MANIFESTATIONS IN CANCER PATIENTS: A HOSPITAL BASED STUDY

*Thapa DP*

Department of Dermatology, Nepal Medical College & Teaching hospital, Attarkhel, Gokarneshwor- 8, Kathmandu

## ABSTRACT

Skin can show various manifestations in patients suffering with malignancy, which may be specific or non specific. In absence of any available literature on this issue, we conducted this study to know the dermatological conditions affecting Nepalese patients with malignancy. A total of 62 patients who were referred for dermatological consultation both from out-patient department and in-patient department of Nepal Cancer Hospital were included in this study. Data including demographic variables, type of malignancy, duration since diagnosis, chemotherapeutic agents administered and dermatological manifestation were recorded. The frequency of Dermatological manifestation in cancer patients was found to be 0.41%. There were 56% females and 44% males. Mean age of presentation was 44 years. These patients had primary malignancy as carcinoma breast in 31%, lung carcinoma 21%, carcinoma colon 16%, carcinoma rectum 8%, carcinoma pancreas 7% and 3% each had carcinoma prostate, carcinoma stomach, carcinoma ovary and oral carcinoma and Ewing sarcoma. The mean duration of presentation of primary carcinoma was 8 months. The most frequent dermatoses was eczema in 39%, followed by infection 25%, pruritus 14%, insect bite hypersensitivity 3.2%, disorder of pilosebaceous unit 3.2%, urticaria 3.2%, pigmentary changes 3.2%, nail involvement 3.2%, drug rash 2%, vesiculo-blistering disorder 2% and cutaneous metastasis in 2%. In absence of screening program, we found a very low frequency of cutaneous manifestation in patients with malignancy in our study. We recommend a prospective long term follow-up study with institution of screening and awareness program.

## KEYWORDS

Cancer, chemotherapy, cutaneous metastasis, infection

## CORRESPONDING AUTHOR

Dr. Deeptara Pathak Thapa,  
Assistant Professor,  
Nepal Medical College & Teaching hospital,  
Attarkhel, Gokarneshwor-8, Kathmandu, Nepal,  
Email: drdeeptarapathak@yahoo.com

## INTRODUCTION

Skin is a mirror of functioning of internal organs. Skin changes can either be the first sign of a deeper problem including an internal malignancy. Signs of skin disease may precede, occur with or follow the detection of an associated cancer. Dermatological manifestation in cancer patients can be direct tumor spread from adjacent or deeper tissue or cutaneous metastasis from the internal organ, side effects of the chemotherapeutic agents or opportunistic infections. Paraneoplastic dermatoses are manifestations that arise in association with malignancy elsewhere in the body. According to Curth's criteria there are major and minor criteria. The two major criteria, including both conditions begin almost at the same time and both conditions follow a parallel course are sufficient to consider a dermatosis as paraneoplastic. This phenomenon is the result of interaction between the tumor and mediators like hormones, cytokines, antibodies, growth factors and the involved tissue.<sup>1</sup> Dermatological manifestations in cancer patient is broadly divided as specific or nonspecific changes.<sup>2</sup>

There are no study regarding Dermatological manifestation in cancer patients in the searchable literature of Nepal. Hence this study was conducted to know the clinical spectrum of dermatological manifestations in cancer patients.

## MATERIALS AND METHODS

All the patients who were referred for Dermatological consultation both from out-patient department and in-patient department of Nepal Cancer Hospital between December 15, 2017 and May 15, 2018 were included in this study. All data including demographic variables (age, sex and residence, hospital ID), data pertaining to the type of malignancy, duration since diagnosis, chemotherapeutic agents administered and dermatological manifestation for which consultation was done was included in the study. A thorough detailed dermatological examination was performed to look for any change/disease in the skin, mucosae, hair and nails. In case of any positive finding, the approximate time interval between the onset of the cutaneous change and the time of diagnosis of malignancy or chemotherapy administered was ascertained. Relevant investigations such as skin biopsy were carried out wherever necessary. Statistical analysis was carried out using SPSS version 16. Descriptive analysis was carried out and chi square test was used to study association between categorical variables and P value <0.05 was considered significant.

## RESULTS

There were total of 15,256 patients who attended out patient department and inpatient department of Nepal Cancer Hospital between December 15, 2017 - June 15 of 2018. Of which a total of 62 patients (0.41%)

were referred for Dermatologic consultation. There were 56% females and 44% males. The minimum age of presentation was 18 years and maximum 78 years and mean age of presentation was 44 years. Majority of the patients (52%) were from Central zone of Nepal, followed by east zone about 18%, south 15%, north 11% and west zone 4%. These patients had primary malignancy as carcinoma breast in 31%, lung carcinoma 21%, carcinoma colon 16%, carcinoma rectum 8%, carcinoma pancreas 7% and 3% each had carcinoma prostate, carcinoma stomach, carcinoma ovary, oral carcinoma and Ewing sarcoma and Ca. parotid 2% as shown in Table 1.

**Table 1: Types of primary cancer in patients having dermatological manifestations**

Type of carcinoma	n (%)
Carcinoma Breast	19 (31)
Carcinoma Lung	13 (21)
Carcinoma Colon	10 (16)
Carcinoma Rectum	5 (8)
Carcinoma Pancreas	4 (7)
Carcinoma Ovary	2 (3)
Carcinoma Oral	2 (3)
Carcinoma Prostate	2 (3)
Carcinoma Stomach	2 (3)
Ewing Sarcoma	2 (3)
Carcinoma Parotid	1 (2)

The mean duration of presentation of primary carcinoma was 8 months. The most frequent dermatoses was eczema in 39%, followed by Infection 25%, Pruritus 14%, Insect bite hypersensitivity 3.2%, disorder of pilo-sebaceous unit 3.2% (Acneiform lesions and seborrheic dermatitis 1 patient each), urticaria 3.2%, pigmentary changes 3.2%, nail involvement 3.2% (Mee's and Bees line in one

**Table 2: Association of patient's characteristics with occurrence of cancer and dermatological manifestations**

Patient's characteristics		Chi square test (P value)
Cancer	Dermatological manifestation	0.0016
Cancer	Age	0.000
Cancer	Sex	0.076
Dermatological manifestation	Age	0.374
Dermatological manifestation	Sex	0.768
Dermatological manifestation	Duration	0.113

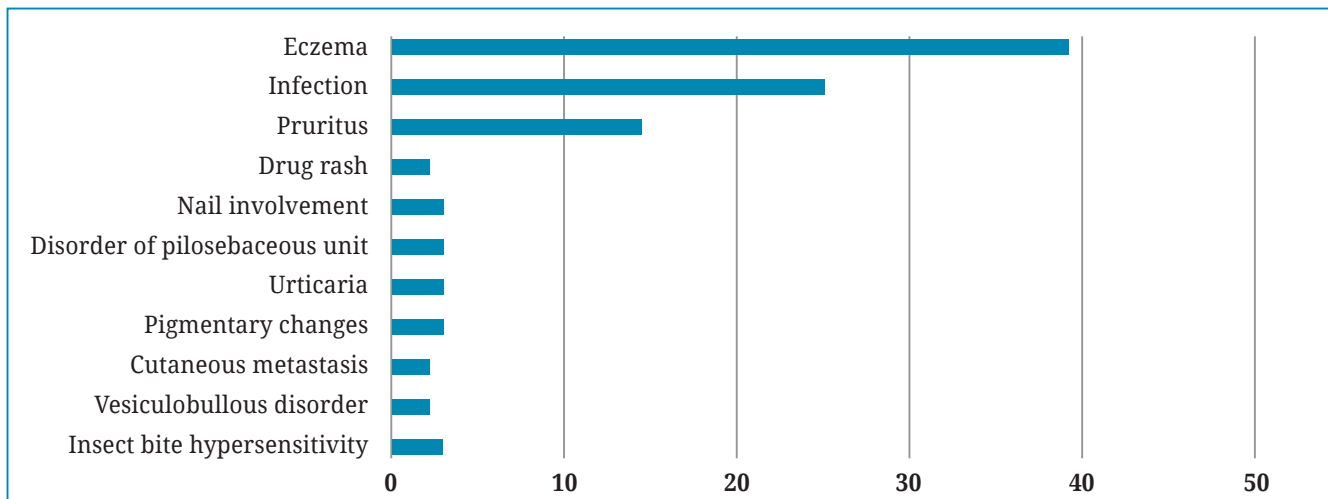


Fig. 1: Dermatological manifestations in cancer patient

patient seen due to etoposide and cyclophosphamide and melanonychia 1 patient), drug rash 2% (due to paclitaxel), vesiculo-blistering disorder 2% and cutaneous metastases in 2% patients as shown in Fig. 1. The mean duration of cutaneous manifestation was 12 days. The most common type of eczema was Xerotic eczema which constituted for 48% of total eczema cases followed by psoriasiform dermatitis 17% and allergic contact dermatitis in 13%. In Infection & Infestation category which was seen in 25%, the commonest was fungal infection constituting about 69% (Dermatophytes 10 patients, cutaneous candidiasis 1 patient), viral 19% (Herpes zoster in 2 patients, herpes labialis 1 patient), bacterial 6% (furunculosis) and scabies 6%. There was statistical significance between different types of cancers and dermatological manifestations ( $p < 0.016$ ), between Cancers and age ( $p < 0.000$ ). Dermatological manifestations with age, or sex or duration of disease didn't have any statistical significance as shown in Table 2.

## DISCUSSION

Cutaneous manifestations may be highly specific to the disease, occur primarily due to the malignancy and include cutaneous metastases and cutaneous markers of various tumor syndromes or are nonspecific and include paraneoplastic syndromes, cutaneous infections, pigmentary disturbances, etc.<sup>3</sup> Some changes are also due to the various treatment modalities employed; for example, alopecia, papulopustular rash, hand-foot syndrome, paronychia and mucositis are common skin reactions seen in patients undergoing chemotherapy.

The five most common cancers worldwide in both sexes were cancers of the lung (13%), breast (11.9%), colorectum (9.7%), prostate (7.9%) and cervix uteri (3.7%) while in our we found the commonest as Carcinoma Breast in 31% followed Lung carcinoma 21% and others. According to Poudel *et al*, in a study in Nepal, Lung cancer has the highest incidence (4.6) in males followed by stomach cancer (2.0) and larynx cancer (1.4) per 100,000 while cervical cancer has

the highest incidence (5.5) per 100,000 population in females followed by breast cancer (4.6) and lung cancer (3.0).<sup>4</sup> The incidence of female cancer cases (29.2) per 100,000 population is higher than the incidence of male cancer cases (26.5) similar to our study.

Skin is a rare site for metastases even though it is the largest organ of the human body. In a study too authenticated this fact as only two patients with cutaneous metastases (0.8%) were seen. Similarly, in our study also we have seen in 1.6% of the total patients. This goes in accordance with other studies in literature which shows that the frequency of cutaneous metastases is low, ranging from 0.8% -9%.<sup>5,6,7,8,9</sup> among which, studies from south east Asia also showed similar results ranging from 0.8% - 6.93%. However in our case this finding may be falsely low as we included only those patients who were referred to us. A systematic screening program to look for any dermatological manifestation would be able to find the true incidence.

The period of interval between the onset of symptoms of the primary malignancy and the onset of cutaneous metastases ranged from 2 months to 5 years.<sup>10</sup> In our study also we found it to be nearly 2 months in a patient Carcinoma Breast.

Eczema was the most common dermatologic finding in our study about 39%. In a study psoriasis and eczema was found to be present in 10%.<sup>11</sup> Generalized xerosis and pruritus are cutaneous manifestations of advanced malignant disease according to Kleyn *et al*.<sup>12</sup> Xerosis was seen in 2.4% according to Hassan *et al*. A study in Asian patients on epidermal growth factor receptor inhibitors the most common drug related reaction was found to be xerosis about 82.8%, while in our study it was seen in 18%.

We found infections as second most common presentation in cancer patients around 16%. Similarly, Quaglino *et al* also found infection to be a common finding in their study affecting 19.8%. Dermatophytosis was the commonest type of infection seen in our study in about 69% out of total

infections followed by viral in 19%. Ayyumperumal *et al* in their study found herpes zoster infection in 27% commonly associated with carcinoma breast but in our study we found it associated with carcinoma pancreas and carcinoma Colon. In a study on hematological malignancies authors found Herpes zoster as the most common non-specific skin lesion, possibly due to multiple factors, especially immunosuppression and anti-neoplastic drugs.<sup>10,13,14</sup>

In literature it has also been stated that Herpes zoster in a cancer patient in remission, may be a marker for recurrent malignant disease.<sup>15</sup> This cutaneous change has been reported in literature to many drugs including sorafenib and capecitabine.<sup>7,10</sup>

Several studies have shown that chemotherapy can cause nail changes such as pigmentary disturbances, nail dystrophy, leukonychia, onycholysis and others. Most of the nail changes seen were possibly chemotherapy induced. The most common chemotherapeutic agents that were received by these patients were cisplatin, cyclophosphamide, epirubicin, 5-fluorouracil, doxorubicin and docetaxel.<sup>7,16,17,18,19</sup> Nail changes with taxanes are very common with some series reporting rates as high as 89% after three treatment cycles.<sup>18</sup> In our study we found involvement of nails in 3.2%. We saw a patient having Mee's and Beau's line in a same patient induced by cyclophosphamide and etoposide.

Skin rashes are relatively common with taxans though the clinical cutaneous changes have received little attention in the literature. Presentation may be diffuse macules and papules may manifest as a mild morbilliform eruption and may be associated with pruritus and burning. Taxane-induced rash is predominantly found such as the folds, contact areas, or under dressings and pads with the most characteristic presentation as development of painful, bilateral, inflammatory intertriginous

patches in the axillary and inguinal regions or neck folds, especially with docetaxel as adjuvant therapy for breast cancer.<sup>21,22,23,24,25,26</sup> In our study we found maculopapular drug reaction in 2% due to paclitaxel in a patient with breast cancer. Quaglino *et al* found drug adverse reactions in 16.8%.<sup>11</sup>

There was statistical difference between different types of cancers and dermatological manifestations (p 0.016) which shows that the present study prevalence of 0.4% which was less and shows only fraction of the total problem therefore screening and long prospective study should be carried out in future. There was also statistical significance between cancer and age (p 0.000) which also points towards screening of the patients in community level.

*Limitations of the study:* Being a cross sectional and a short-duration study, patients couldn't be followed up for longer duration and couldn't be assessed for clearance of dermatological manifestation after treatment. The fact that cutaneous lesions either preceded the primary cancer or occurred after the onset of cancer couldn't be assessed.

The manifestations of skin lesions in patients with malignancy may be of greatest importance in the detection and management of cancer because of easy accessibility of the skin to examination in cancer patients and as such can provide important insights into underlying cancer processes or possible complications from cancer chemotherapy or opportunistic infection. Though the frequency of cutaneous manifestation was very low (0.41%) in our study, this could be the tip of iceberg therefore long follow-up study along with public awareness programs, Physician awareness and more Dermatology referrals for suspected skin lesion should be carried in near future.

## REFERENCES

- Ortega-Loayza AG, Ramos W, Gutierrez EL, Paz PC, Bobbio L, Galarza C. Cutaneous manifestations of internal malignancies in a tertiary health care hospital of a developing country. *An Bras Dermatol* 2010; 8: 736-42
- Lee A. Skin manifestations of internal disease. *Aust Fam Physician* 2009; 38: 498-505.
- Yuste-Chaves M, Unamuno PP. Cutaneous alerts in systemic malignancy: Part I. *Actas Dermosifiliogr* 2013; 104: 285-98.
- Poudel KK, Huang Z, Neupane PR, Steel R, Poudel JK. Hospital based cancer incidence in Nepal from 2010 to 2013. *Nepal J Epidemiol* 2017; 7: 659-65.
- Fabrocini G, Izzo R, Panariello L, Monfrecola G. Skin reactions secondary to anticancer agents. *Eur Med J Dermatol* 2013; 1: 38-43.
- Lookingbill DP, Spangler N, Sexton FM. Skin involvement as the presenting sign of internal carcinoma. A retrospective study of 7316 cancer patients. *J Am Acad Dermatol* 1990; 22: 19-26.
- Hassan, I, Zeerak S, Kuchav S, Bashir S, Bhat YJ, Mubashir S *et al*. Cutaneous changes in internal malignancy: Study from a tertiary care center. *Indian J Dermatol Venereol Lepros* 2017; 83: 276
- Chopra R1, Chhabra S, Samra SG, Thami GP, Punia RP, Mohan H *et al*. Cutaneous metastases of internal malignancies: a clinicopathologic study. *Indian J Dermatol Venereol Leprol* 2010; 76: 125-31.
- Saranath D, Khanna A. Current status of cancer burden: Global and Indian scenario. *Biomed Res J* 2014; 1: 1-5.
- Ayyamperumal A, Tharini G, Ravindran V, Parveen B. Cutaneous manifestations of internal malignancy. *Indian J Dermatol* 2012; 57: 260-4



11. Quaglino P1, Nardò T, Fierro MT, Massaia M, Orsucci L, Fava P *et al.* Clinicopathologic spectrum of cutaneous diseases in patients with hematologic malignancies with or without allogeneic bone marrow transplantation: an observational cohort study in 101 patients. *G Italy Dermatol Venereol* 2013; 148: 453-63.
12. Kleyn CE, Lai-Cheong JE, Bell HK. Cutaneous manifestations of internal malignancy: diagnosis and management. *Am J Clin Dermatol* 2006; 7: 71-84.
13. Chularojanamontri L, Tuchinda P, Likitwattananurak C, Pongparit K, Rujitharanawong C, Ithimakin S *et al.* Cutaneous toxicities of epidermal growth factor receptor inhibitors: A prospective study in 60 Asian patients. *Asian Pac J Allergy Immunol* 2018 Mar 12. doi: 10.12932/AP-140317-0047. [Epub ahead of print]
14. Rajagopal R, Arora PN, Ramasastry CV, Kar PK. Skin changes in internal malignancy. *Indian J Dermatol Venereol Leprol* 2004; 70: 221-5.
15. Clean DI. Cutaneous Manifestations of Internal Malignant Disease. *Can Fam Physician* 1987; 33: 2357-2365
16. Dasanu CA, Alexandrescu DT, Wiernik PH. Recognizing nail and skin changes associated with chemotherapy. *Resid Staff Physician* 2006; 52: 16-20.
17. Gupta A, Parakh A, Dubey AP. Chemotherapy induced nail changes. *Indian J Dermatol* 2008; 53: 204-5.
18. Hinds G, Thomas VD. Malignancy and cancer treatment-related hair and nail changes. *Dermatol Clin* 2008; 26: 59-68.
19. Schrijvers D, Wanders J, Dirix L. Coping with toxicities of docetaxel Taxotere. *Ann Oncol* 1993; 4: 610-1.
20. Sibaud V, Lebœuf NR, Roche H, Belum VR, Gladiëff L, Deslandres M *et al.* Dermatology adverse events with taxane chemotherapy. *Eur J Dermatol* 2016; 26: 427-43.
21. Cortes JE, Pazdur R. Docetaxel. *J Clin Oncol* 1995; 13: 2643-55.
22. Trudeau, ME. Docetaxel (Taxotere): An overview of first-line monotherapy. *Semin Oncol* 1995; 22: 17-21.
23. Bologna, JL, Cooper DL, Glusac, EJ. Toxic erythema of chemotherapy: a useful clinical term. *J Am Acad Dermatol* 2008; 59: 524-940.
24. Childress J, Lokich J. Cutaneous hand and foot toxicity associated with cancer chemotherapy. *Am J Clin Oncol* 2003; 26: 435-6.
25. Spicknall KE, Mutasim DF. Localized toxic erythema of chemotherapy during treatment with paclitaxel. *Int'l J Dermatol* 2014; 53: e3-5.
26. Zimmerman GC, Keeling JH, Burris HA. 1995. Acute cutaneous reactions to docetaxel, a new chemotherapeutic agent. *Arch Dermatol* 1995; 131: 202-6.