

Case Report

Primary Melanoma of Testis- A Case Report

Sujata Pudasaini¹, Bhola Raj Joshi², Neeraj Subedi², Rakesh Pathak¹, Kricha Pande¹, Shradha Koirala¹, Neeta Kafle¹, Krishna Kaji Bhomi², Aanchal Shahi¹

¹Department of Pathology, Nepal Medical College, Kathmandu, Nepal

²Department of Urology, Nepal Medical College, Kathmandu, Nepal

ABSTRACT

Primary melanoma of the testis is very rare. Melanoma of testis usually occurs as metastatic tumor. Here we present a case of 54 year old man with right testicular swelling proven to be primary malignant melanoma. Patient had right scrotal swelling of six months duration. With raised LDH and unremarkable Serum β -HCG and Alpha Feto Protein level and with a suspicion of primary testicular tumor on MRI, right inguinal orchidectomy was done. Its clinical presentation and histopathological examination is discussed here.

Keywords: Melanoma; Melan- A; Testis

Copyright: This is an open-access article distributed under the terms of the Creative Commons Attribution 4.0 International License, which permits unrestricted use, distribution, and reproduction in any medium, provided the original author and source are credited.

Correspondence:

Dr Sujata Pudasaini, MBBS, MD
Associate Professor, Department of Pathology,
Nepal Medical College, Kathmandu, Nepal
ORCID ID: 0000-0001-9699-8204
Email: sujatapudasaini@gmail.com

Submitted: 20th September 2018

Accepted: 25th October 2018

Published: 1st December 2018



Conflict of Interest: None

Sources of Support: None

Citation: Pudasaini S, Joshi BR, Subedi N, Pathak R, Pande K, Koirala S, Kafle N, Bhomi KK, Shahi A. Primary melanoma of testis- a case report. Nep Med J 2018;1:121-3. DOI: 10.3126/nmj.v%vi%i.21594

INTRODUCTION

Testicular cancer comprises approximately 1% of all the male cancers worldwide.^{1,2} It is most commonly seen in younger age group.³ The incidence of testicular tumors is on rising trend in western countries.^{1,3} The commonest presentation of testicular tumor is painless swelling of one gonad.¹ Tumors of germ cell origin account for 94% to 96% of all testicular neoplasms and sex cord stromal origin constitute 4% to 6 percent. The remaining testicular neoplasms of diverse histologic types are rare and account for 1% of testicular tumors.² Metastatic carcinoma to the testis is a rare finding and simulates primary testicular neoplasm.⁴

Melanoma is a malignant neoplasm arising from melanocytes and is relatively rare.⁵ Melanoma metastasizing to the testis

is aggressive and life threatening. The incidence of cutaneous melanoma as the primary site in metastatic testicular tumors has been reported to vary between 9% and 41%.⁴ Other sites for melanoma include the oral cavities, nasal sinuses, genitalia and rectum.⁵ Primary melanoma of testis is extremely rare.⁴

CASE REPORT

A 54 year male came to surgery outpatient department with the chief complaints of right scrotal swelling for 6 months. The patient was apparently well 6 months ago when he noticed right

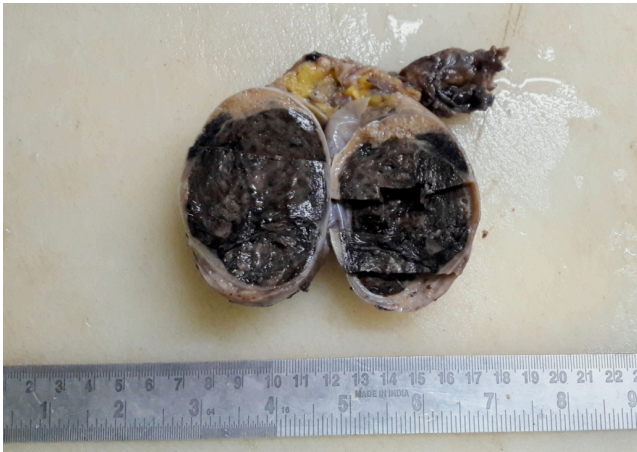

Figure 1: Orchidectomy specimen; Gross showing well capsulated solid mass with melanin pigments giving it a black homogenous appearance

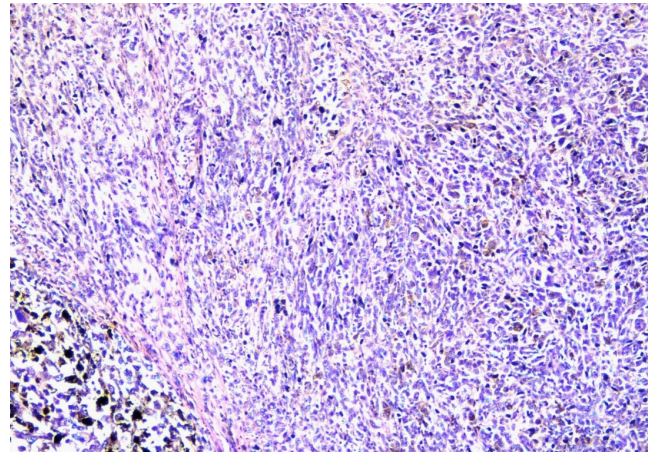


Figure 2: Sheets of oval to spindle shaped cells and melanin pigments. (H E stain, x 100)

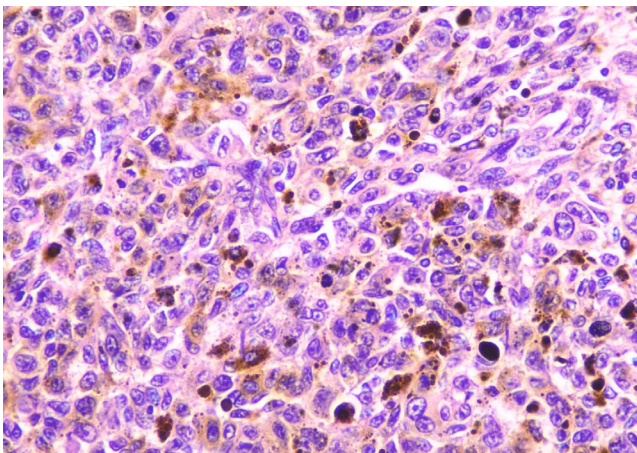


Figure 3: Sheets of melanoma cells with prominent eosinophilic nucleoli and melanin pigments. (H E stain, x 400)

sided scrotal swelling. The swelling was gradually increasing in size and was associated with pain. The pain was mild to start with and later increased. The patient did not give history of any significant illness in the past. The patient had no other findings on examination. Right scrotum was enlarged and measured 10 cm x 7 cm. The overlying skin was normal.

Laboratory investigations such as LDH, Serum B HCG and Alpha Feto Protein were sent. LDH (1025, normal- 313-618U/L) was raised. Serum B HCG (<2.39) and Alpha Feto Protein (AFP) (3.94 ng/ml) were not raised. MRI was suggestive of primary testicular tumor.

Right high inguinal orchidectomy was done and the specimen was sent for histopathological examination. Specimen of right testis, epididymis and spermatic cord was received in a container with formalin. Testis weighed 120 grams and measured 9 x 6 x 5 cm. Epididymis measured 2 x 0.5 cm and spermatic cord measures 7 x 2 cm. Outer surface of the testis was smooth and shiny. Cut surface showed well capsulated mass measuring 6 x 4 x 4 cm. The testis was almost replaced by the mass which was solid and cut surface was homogenous dark in colour. The mass was free from tunica vaginalis grossly. Epididymis was grossly unremarkable however the spermatic cord was thickened (fig 1).

Microscopic examination showed tumor cells arranged in sheets, fascicular pattern and occasional nested pattern (fig 2 and fig 3).

These cells shows moderate to severe pleomorphism. Individual tumor cells were oval to spindle shaped with increased nuclear to cytoplasmic ratio and cells had moderate to abundant eosinophilic cytoplasm. Few cells showed eccentric nuclei. Nuclei showed irregular nuclear rim, vesicular to coarse clumped chromatin with prominent eosinophilic nucleoli. Some of the cells showed intranuclear cytoplasmic inclusions and grooves. Binucleated cells, multinucleated giant cells and few bizarre looking cells were also noted. Stroma showed lymphocytic infiltrations and dark brown pigments. Occasional mitotic figures were seen in the mitotically active stroma. Normal testicular parenchyma showed seminiferous tubules with edematous stroma. Margins including tunica vaginalis were free of tumor. Section from the epididymis and spermatic cord were histologically unremarkable. With all this findings, the impression on histopathological examination was poorly differentiated carcinoma with differential diagnosis of spermatocytic seminoma (sarcomatoid/ anaplastic), melanoma and lymphoma. Paraffin blocks were sent for Immunohistochemistry (IHC). Result showed IHC markers MELAN-A, SOX-10, HMB-45 immunoreactive with 4+ score in neoplastic cells and IHC markers CD45, CK and SALL-4 non immunoreactive scoring 0 in neoplastic cells. The impression of IHC was suggestive of melanoma.

The patient was followed up after surgery. The wound healing was good and there were no complaints. The patient was re-examined to look for any pigmented lesions in the body elsewhere. However, no remarkable pigmented lesions were identified. The patient was referred to Oncology department but patient refused for further management. Follow up till 5 months was uneventful.

DISCUSSION

Melanoma is a neoplasm that arises from melanocytes and is increasing in incidence.³

It accounts for 1-2 % of all malignancies.⁵ Most of the melanoma arises from the skin. In 5-10% of cases, melanoma arises from sites other than the skin.⁵ Tumor metastatic to the testis accounts for 3.6% affecting elderly men. The metastasis could be from prostate, lung, urinary tract, skin (melanoma), colon or kidney.^{2,4} Primary melanoma arising from the visceral organ is extremely rare especially from the testicle.³ To the best of our knowledge, there were only two cases of primary melanoma of testis reported,

one on fine needle aspiration and another on histopathological examination.^{5,6}

Primary melanoma of testis is extremely rare and its existence is questionable.⁴ In most of the cases, it represents a disseminated disease that was not diagnosed yet.⁷

Migration of melanin producing cells from the neural crest to mesodermal derivatives during embryologic development

explains the presence of melanocytes in testis. This supports the possibility of a primary melanoma in testis.⁵

CONCLUSION

Although very rare, primary melanoma of the testis should be a consideration in a patient with scrotal pain and testicular swelling.

REFERENCES

1. Beigh A, Junaid S, Beg A, Farooq S, Wani LA, Manjoor F. Clinopathological study of testicular tumors: an experience in a tertiary care hospital in Kashmir valley, Jammu and Kashmir, India. *Int J Res Med Sci* 2017;5:2741-6. [Crossref](#)
2. Christopher D M Fletcher. Tumors and tumor like conditions of the male genital tract, testicular neoplasms. *Diagnostic histopathology of tumors*. 4th edn. Elsevier, 1995. pp- 951-98.
3. Patnana M, Korivi BR, Devine CE et al. Metastatic melanoma to the testis. *British J Radiol Case Rep* 2018;4:20170104. [Crossref](#)
4. Muhammad ZA, Ahmed MS, Nagrajan S, Rizvi ST. Malignant melanoma representing with testicular metastasis: a case report and review of the literature. *Can Urol Assoc J* 2010; 4: 103-4
5. Katiyar RK, Singh A, Kumar D. Primary melanoma of testis. *J cancer Res Ther* 2008;4: 97-8. [Crossref](#)
6. Damala K, Tsanon E, Pappa L et al. A rare case of primary malignant melanoma of the scrotum diagnosed by fine needle aspiration. *Diagn Cytopathol* 2004;31:413-6 [Crossref](#)
7. Gomes CA, Junior CS, Pireira de Assis EAC et al. Metastatic and synchronous melanoma in the testicle and paratesticular region. *J clin Exp Dermatol Res* 2012; 3: doi/10.4172/2155/9554/1000139